

Myocarditis Following COVID-19 Vaccination

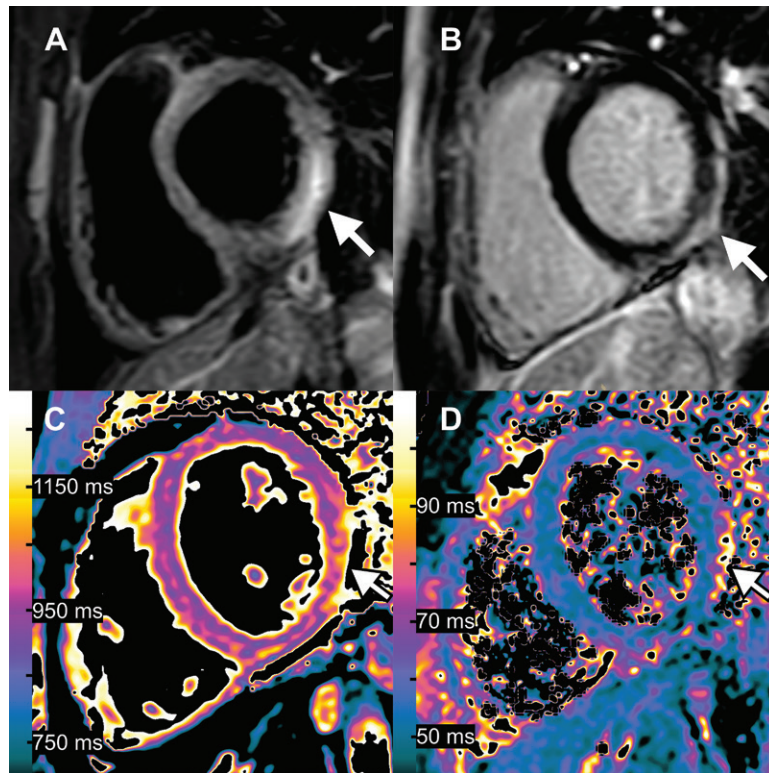
Alexander Isaak, MD • Andreas Feisst, MD • Julian A. Luetkens, MD

From the Department of Diagnostic and Interventional Radiology, University Hospital Bonn, Venusberg-Campus 1, 53127 Bonn, Germany; and Quantitative Imaging Laboratory Bonn, Bonn, Germany. Received July 14, 2021; revision requested July 14; revision received July 20; accepted July 22. Address correspondence to A.I. (e-mail: alexander.isaak@ukb Bonn.de).

A.I. is supported by the BONFOR research program (grant no. 2021-1A-05).

Conflicts of interest are listed at the end of this article.

Radiology 2021; 301:E378–E379 • <https://doi.org/10.1148/radiol.2021211766> • ©RSNA, 2021



Images in 15-year-old boy with myocarditis after COVID-19 vaccination. One day after receiving his second vaccination dose, he developed fever, myalgia, and intermittent tachycardia. **(A)** T2-weighted short inversion time inversion recovery MRI scan at 1.5 T in short-axis view shows focal high-signal intensities (arrow) at basal lateral and inferior wall, indicating myocardial edema. **(B)** Late gadolinium enhancement image in short-axis view shows corresponding linear subepicardial enhancement (arrow), indicating inflammatory myocardial necrosis. **(C)** T1 mapping and **(D)** T2 mapping in short-axis view show elevated T1 and T2 at the mid-ventricular lateral and inferolateral wall (arrow in **C** and **D**), indicating acute myocardial injury (focal T1, 1165 msec; focal T2, 70 msec; institution-specific cut-off values for acute myocarditis: T1 global ≥ 1000 msec, T2 global ≥ 55.9 msec).

A healthy 15-year-old boy received his second dose of the Pfizer-BioNTech COVID-19 vaccine. The next day, he developed fever, myalgia, and intermittent tachycardia. At presentation to the hospital, electrocardiography showed ST-segment elevation in the left precordial leads. High-sensitive cardiac troponin and C-reactive protein levels were elevated. Serologic test results for cardiotropic viruses were negative. Transthoracic echocardiography showed normal myocardial function without wall motion abnormalities. Cardiac MRI at 1.5 T showed a normal left ventricular size, a normal left ventricular ejection fraction, and a small pericardial effusion. T2-weighted short inversion time inversion recovery sequences displayed focal myocardial edema involving the lateral wall, most emphasized in the basal inferolateral segment (Figure, A). Corresponding subepicardial enhancement was detected with late gadolinium enhancement imaging indicating inflammatory necrosis (Figure, B). Quantitative myocardial mapping parameters were elevated, which confirmed the qualitatively assessed findings (Figure, C, D). The 2018 Lake Louise criteria for the diagnosis of acute myocarditis were fulfilled (1,2). Furthermore, vaccine-induced

unilateral axillary lymphadenopathy was also observed. Because of the close temporal relation between the COVID-19 vaccination and the onset of symptoms (1 day), vaccine-induced hypersensitivity myocarditis was the clinical diagnosis. The patient was discharged in stable condition after 7 days of hospitalization.

Cardiac MRI characteristics of vaccine-induced hypersensitivity myocarditis are similar to other virus-induced causes of myocarditis. This case shows that clinicians should be aware of vaccine-induced myocarditis as a possible adverse effect in children with thoracic and/or cardiovascular complaints after COVID-19 vaccination. As children are now scheduled to be vaccinated in many countries, cases of vaccine-induced myocarditis will have been noted in association with messenger RNA vaccines. Vaccine-associated myocarditis is rare but more common in the younger population, especially in males (eg, incidence of 40.6 cases per million second doses of COVID-19 vaccinations in males aged 12–29 years [3]). The clinical course is typically self-limited (4).

Disclosures of Conflicts of Interest: A.I. disclosed no relevant relationships. A.F. disclosed no relevant relationships. J.A.L. received payment for lectures from Philips Healthcare.

References

1. Ferreira VM, Schulz-Menger J, Holmvang G, et al. Cardiovascular Magnetic Resonance in Nonischemic Myocardial Inflammation: Expert Recommendations. *J Am Coll Cardiol* 2018;72(24):3158–3176.
2. Luetkens JA, Faron A, Isaak A, et al. Comparison of Original and 2018 Lake Louise Criteria for Diagnosis of Acute Myocarditis: Results of a Validation Cohort. *Radiol Cardiothorac Imaging* 2019;1(3):e190010.
3. Gargano JW, Wallace M, Hadler SC, et al. Use of mRNA COVID-19 Vaccine After Reports of Myocarditis Among Vaccine Recipients: Update from the Advisory Committee on Immunization Practices - United States, June 2021. *MMWR Morb Mortal Wkly Rep* 2021;70(27):977–982.
4. Montgomery J, Ryan M, Engler R, et al. Myocarditis Following Immunization With mRNA COVID-19 Vaccines in Members of the US Military. *JAMA Cardiol* 2021. 10.1001/jamacardio.2021.2833. Published online June 29, 2021.