

COVID-19 Vaccination–Associated Axillary Adenopathy: Imaging Findings and Follow-Up Recommendations in 23 Women

Shabnam Mortazavi, MD, MPH¹

Submitted: Feb 6, 2021 ■ Revision requested: Feb 11, 2021 ■ Revision received: Feb 18, 2021 ■ Accepted: Feb 20, 2021 ■ First published online: Feb 24, 2021

The author declares that there are no disclosures relevant to the subject matter of this article.

The purpose of this article is to report on 23 women with evidence of axillary adenopathy at breast imaging after recent COVID-19 vaccination. A total of 13% of patients had symptoms (axillary lump), 43% were undergoing screening, and 43% were undergoing diagnostic imaging for other reasons. BI-RADS category 2 was assigned in one case, BI-RADS 3 in 21 (ultrasound in 4–24 weeks), and BI-RADS 4 in one. Radiologist familiarity and evidence-based guidelines are needed to avoid follow-up imaging and biopsies for reactive adenopathy after COVID-19 vaccination.

The finding of axillary adenopathy on imaging after COVID-19 vaccination has been reported [1]. Practice recommendations are needed to prevent excessive follow-up imaging and potential biopsy of COVID-19–associated axillary adenopathy. The purpose of this study was to assess clinical and imaging features of axillary adenopathy after COVID-19 vaccination to inform the development of follow-up recommendations.

Methods

This retrospective HIPAA-compliant study was approved by the institutional review board. The requirement for informed consent was waived. Electronic medical record review was performed to identify women with axillary adenopathy detected during screening or diagnostic breast imaging after recent COVID-19 vaccination from December 2020 to February 2021. According to institutional protocol, during screening and diagnostic breast ultrasound examinations, the axilla was routinely scanned with high-frequency (12 MHz) linear-array ultrasound transducers (iU22 and EPIQ Elite ultrasound systems, Philips Healthcare). Clinical data and imaging reports were summarized descriptively. No new interpretations were made.

For mammography, a node was considered abnormal when its size, shape, or density was deemed disproportionate to other axillary nodes (ipsilateral or contralateral). For ultrasound, a node was considered abnormal on the basis of subjective assessment for cortical abnormalities, including focal or diffuse thickening greater than 3 mm [2–4] and nodal prominence compared with the contralateral axilla (when available). Overall node size was not a criterion given lack of consensus about axillary node assessment with ultrasound [5]. For MRI, a node was considered abnormal when asymmetric in size and/or number in comparison with nodes in the contralateral axilla.

Results

A total of 23 women (mean age, 49 ± 21 years) had axillary adenopathy ipsilateral to the vaccinated arm on screening or diagnostic breast imaging (Table 1). A total of 13% had symptoms (axillary lump with possible tenderness). The adenopathy was detected incidentally on screening breast imaging in 43% of patients (mammography, 5; ultrasound, 2; both mammography and ultrasound, 1; high-risk screening MRI, 2) and on diagnostic imag-

TABLE 1: Summary of Data on 23 Women With COVID-19 Vaccination–Associated Axillary Adenopathy

| Feature | No. of Patients |
|--|-----------------|
| Type of vaccine | |
| Pfizer-BioNTech | 12 (52) |
| Moderna | 5 (22) |
| Not reported | 6 (26) |
| Time between first dose and imaging (d) ^a | |
| 2–6 | 7 (35) |
| 7–13 | 7 (35) |
| 14–20 | 5 (25) |
| > 20 | 1 (5) |
| Presentation | |
| Symptomatic (axillary lump with possible tenderness) | 3 (13) |
| Asymptomatic, screening | 10 (43) |
| Asymptomatic, diagnostic (reason unrelated) | 10 (43) |
| Modality showing abnormal node | |
| Mammography | 5 (22) |
| Ultrasound | 12 (52) |
| Mammography and ultrasound | 4 (17) |
| MRI | 2 (9) |
| No. of abnormal lymph nodes | |
| 1 | 13 (57) |
| 2 | 5 (22) |
| 3 | 3 (13) |
| > 3 | 2 (9) |

(Table 1 continues on next page)

¹Department of Radiology, University of California Los Angeles Health System, 200 Medical Plaza, Ste 165-47, Los Angeles, CA 90095. Address correspondence to S. Mortazavi (smortazavi@mednet.ucla.edu).

TABLE 1: Summary of Data on 23 Women With COVID-19 Vaccination–Associated Axillary Adenopathy (continued)

| Feature | No. of Patients |
|--|-----------------|
| Maximal lymph node cortical thickness (mm) | |
| 4 | 10 (43) |
| 5–6 | 10 (43) |
| > 6 | 3 (13) |
| Imaging follow-up recommendation (wk) | |
| No imaging follow-up (BI-RADS 2) | 1 (4) |
| 4–6 (BI-RADS 3) | 5 (22) |
| 7–12 (BI-RADS 3) | 13 (57) |
| 13–24 (BI-RADS 3) | 3 (13) |
| Ultrasound-guided biopsy (BI-RADS 4) | 1 (4) |

Note—Values in parentheses are percentages, which may not total 100 owing to rounding.

^aExcludes three patients in whom adenopathy was first detected after second dose (interval of 1, 7, or 9 days after second dose).

ing for other reasons in 43% (BI-RADS category 3 follow-up for breast finding, 3; screening callback for other reason, 2; nonaxillary breast pain or lump, 5). The median interval between the first vaccine dose and imaging showing the abnormal node (20 patients) was 9.5 days (range, 2–29 days). A total of 57% of women had one abnormal node. The cortical thickness of the largest node was greater than 6 mm in 13% of patients.

BI-RADS category 2 was assigned in one case, and BI-RADS 3 in 21 cases (median recommended ultrasound follow-up, 8 weeks; range, 4–24 weeks) (Fig. 1). BI-RADS 4 was assigned in one case. This patient had left breast pain and a medical history of left breast cancer, ipsilateral to the vaccination site. Ultrasound-guided core needle biopsy yielded a reactive lymphoid process.

Discussion

We report on the largest sample, to our knowledge, of the finding of COVID-19 vaccination–associated axillary adenopathy on imaging. A total of 87% of cases were detected incidentally in women who did not have symptoms. The adenopathy was detected on screening imaging in 50% of these women. Follow-up imaging or biopsy was recommended to all but one patient.

Current Society of Breast Imaging recommendations for management of unilateral axillary adenopathy found at screening examinations after recent COVID-19 vaccination [6] entail initial BI-RADS category 0 assessment to allow further assessment of the ipsilateral breast; after appropriate diagnostic workup, consideration of a follow-up examination 4–12 weeks after the second

dose (BI-RADS 3); and if axillary adenopathy persists, consideration of lymph node sampling to exclude malignancy. Furthermore, Mehta et al. [7] recommended follow-up of the affected axilla 4–12 weeks after the second dose with targeted ultrasound to evaluate for resolution. They noted that ultrasound-guided core needle biopsy might be necessary to exclude malignancy if the adenopathy persists.

Despite these recommendations, our study highlights the occurrence of axillary adenopathy ipsilateral to the arm into which Pfizer-BioNTech or Moderna COVID-19 vaccine is injected as a potential reactive process with which radiologists must be familiar. Recommendation for follow-up imaging may not be warranted. Incorporating the patient's COVID-19 vaccination history, including vaccination date and laterality, is critical to optimizing assessment and management of imaging-detected axillary adenopathy in women with otherwise normal breast imaging findings. Concurrent assessment of the contralateral axilla for comparison may assist radiologists in management. This study was limited by small sample size and retrospective design. In addition, we did not determine the percentage, among all women undergoing imaging at our centers, of women exhibiting adenopathy who had received recent COVID-19 vaccination, nor did we compare imaging between women with and those without vaccination. Future research remains warranted.

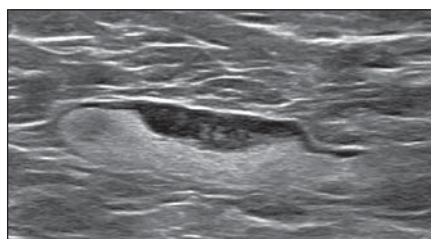
References

- Ahn RW, Mootz AR, Brewington CC, Abbara S. Axillary lymphadenopathy after mRNA COVID-19 vaccination. *Radiol Cardiothorac Imaging* 2021; 3:e210008
- Choi YJ, Ko EY, Han BK, Shin JH, Kang SS, Hahn SY. High-resolution ultrasonographic features of axillary lymph node metastasis in patients with breast cancer. *Breast* 2009; 18:119–122
- Abe H, Schmidt RA, Kulkarni K, Sennett CA, Mueller JS, Newstead GM. Axillary lymph nodes suspicious for breast cancer metastasis: sampling with US-guided 14-gauge core-needle biopsy—clinical experience in 100 patients. *Radiology* 2009; 250:41–49
- Bedi DG, Krishnamurthy R, Krishnamurthy S, et al. Cortical morphologic features of axillary lymph nodes as a predictor of metastasis in breast cancer: in vitro sonographic study. *AJR* 2008; 191:646–652
- Marino MA, Avendano D, Zapata P, Riedl CC, Pinker K. Lymph node imaging in patients with primary breast cancer: concurrent diagnostic tools. *Oncologist* 2020; 25:e231–e242
- Grimm L, Destounis S, Dogan B, et al.; Society of Breast Imaging Patient Care and Delivery Committee. Recommendations for the management of axillary adenopathy in patients with recent COVID-19 vaccination. Society of Breast Imaging website. www.sbi-online.org/Portals/0/Position%20Statements/2021/SBI-recommendations-for-managing-axillary-adenopathy-post-COVID-vaccination.pdf. Accessed May 21, 2021
- Mehta N, Sales RM, Babagbemi K, et al. Unilateral axillary adenopathy in the setting of COVID-19 vaccine. *Clin Imaging* 2021; 75:12–15

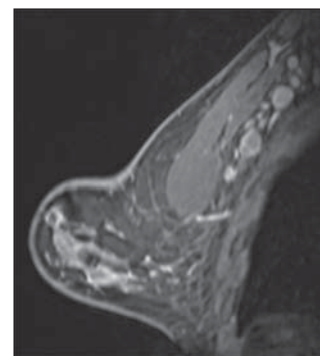
Fig. 1—Examples of BI-RADS category 3 assessments.

A, 55-year-old woman who underwent screening mammography and ultrasound (US) 7 days after first COVID-19 vaccination dose. Screening mammogram and US showed unilateral left axillary lymph node with cortical thickness of 5 mm on US (not shown). BI-RADS category 0 was assigned. US from diagnostic workup performed 7 days later shows no change in lymph node size. BI-RADS 3 was assigned.

B, 41-year-old woman who underwent high-risk screening breast MRI 15 days after first COVID-19 vaccination dose. Sagittal T1-weighted fat-saturated contrast-enhanced MRI shows extensive unilateral left level I–II axillary adenopathy. BI-RADS category 3 was assigned.



A



B