

## Short communication

# Supraclavicular lymphadenopathy following COVID-19 vaccination: an increasing presentation to the two-week wait neck lump clinic?

O.R. Mitchell\*, R. Dave, J. Bekker, P.A. Brennan

*Queen Alexandra Hospital, Portsmouth*

Available online 15 February 2021

## Abstract

The first COVID-19 vaccination was given in December 2020 and there is an effort to vaccinate the international population on a massive scale. Common side effects from the vaccine include headache and tiredness. Regional lymphadenopathy has been described in relation to other vaccines. We describe two cases of supraclavicular reactive lymphadenopathy presenting in patients who had the COVID vaccination in the ipsilateral arm. Awareness of this diagnosis is important for patients presenting to the neck lump clinic.

© 2021 The British Association of Oral and Maxillofacial Surgeons. Published by Elsevier Ltd. All rights reserved.

*Keywords:* COVID-19; lymphadenopathy; neck lump

The first COVID-19 vaccination was given to an NHS patient on 8 December 2020.<sup>1</sup> Since then then over fifteen million people have received the vaccine in England and this number will significantly increase as the population is offered it.<sup>2</sup> Common side effects include a sore arm, tiredness, headaches, and general malaise.

We report two cases of reactive supraclavicular lymphadenopathy following COVID-19 vaccination presenting at the same two-week wait neck lump clinic. A 47-year-old and a 55-year-old female, both otherwise fit and well, had received the COVID vaccination in their left arms three weeks previously. They both then developed a swollen left supraclavicular lymph node about three days later and were referred to the urgent neck lump clinic on the two-week wait cancer pathway to exclude malignancy. One of the patients reported that the lump had since reduced in size. Clinical and ultrasonographic examination confirmed the lumps as reac-

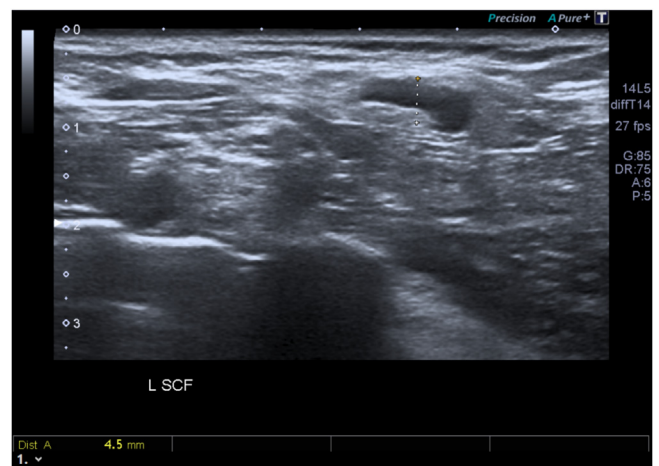


Fig. 1. 4.5mm reactive lymph node in the left supraclavicular fossa.

tive lymph nodes (Fig. 1). No other neck lymphadenopathy was identified and both patients were reassured and discharged.

\* Corresponding author.

*E-mail addresses:* [Omitchell241@gmail.com](mailto:Omitchell241@gmail.com) (O.R. Mitchell), [Roma.Dave@porthosp.nhs.uk](mailto:Roma.Dave@porthosp.nhs.uk) (R. Dave), [Jasper.Bekker@porthosp.nhs.uk](mailto:Jasper.Bekker@porthosp.nhs.uk) (J. Bekker), [peter.brennan@porthosp.nhs.uk](mailto:peter.brennan@porthosp.nhs.uk) (P.A. Brennan).

<https://doi.org/10.1016/j.bjoms.2021.02.002>

0266-4356/© 2021 The British Association of Oral and Maxillofacial Surgeons. Published by Elsevier Ltd. All rights reserved.