

# A case of generalized Sweet syndrome with vasculitis triggered by recent COVID-19 vaccination



Neha Kinariwalla, MPhil,<sup>a</sup> Ashley O. London, MS,<sup>a</sup> Ysra S. Soliman, MD,<sup>b</sup> George W. Niedt, MD,<sup>c</sup> Sameera Husain, MD,<sup>b</sup> and Stephanie M. Gallitano, MD<sup>b</sup>  
New York, New York

**Key words:** COVID-19; Sweet syndrome; vaccination; vasculitis.

## INTRODUCTION

Sweet syndrome (SS), also known as acute febrile neutrophilic dermatosis, is an uncommon dermatosis characterized by fever, neutrophilia, and multiple erythematous painful plaques. Histologically, it presents with a dense dermal neutrophilic infiltration. SS is often associated with hematologic malignancies, including plasma cell dyscrasias. Herein, we report a rare case of SS with vasculitis and transient IgA monoclonal gammopathy triggered by a Janssen Ad26.COVS.2 vaccine.

## CASE REPORT

A 54-year-old man with no significant past medical history presented to the emergency department in significant pain, with tongue swelling and ulceration. The patient denied fevers, chills, night sweats, and weight loss. He had received the Janssen Ad26.COVS.2 vaccine 9 days prior to symptom onset.

On physical examination, he had an erythematous, fissured tongue with confluent erosions (Fig 1, A) and dozens of firm, blanching and erythematous and papulonecrotic nodules on the extremities and trunk (Fig 1, B). The scrotum had flesh-colored and erythematous plaques. The plantar aspects of the feet had erythematous and targetoid macules (Fig 1, C). The patient's lesions progressed over one week, and he developed new eroded and crusted plaques on the scalp, trunk, and extremities. The genital (Fig 1, D) and plantar foot lesions became more targetoid in appearance.

### Abbreviation used:

SS: Sweet syndrome

Lab work revealed leukocytosis ( $10.84 \times 10^3/\mu\text{L}$ ) with 90% neutrophils, an erythrocyte sedimentation rate of 29 mL/h, and a C-reactive protein concentration of 19.6 mg/L. Serum protein electrophoresis resulted in a positive abnormal monoclonal IgA lambda. Additional rheumatologic, including tests for antineutrophil cytoplasmic antibodies and antinuclear antibody, and infectious workup was otherwise negative. The patient was negative for COVID-19 on nasal polymerase chain reaction, and COVID-19 serologies were negative. Computed tomography of the chest, abdomen, and pelvis were unremarkable.

Three 3-millimeter punch biopsies were performed for direct immunofluorescence, hematoxylin-eosin staining, and tissue cultures for fungi and bacteria, including acid-fast bacilli. Hematoxylin-eosin staining demonstrated a dense interstitial and perivascular neutrophilic infiltrate with leukocytoclasia and focal fibrin deposition in blood vessel walls (Fig 2, A to C). Notably, we did not appreciate papillary dermal edema. The direct immunofluorescence and cultures were unremarkable. The patient was treated with a 10-day course of steroids with significant improvement of the lesions. Furthermore, repeat serum protein electrophoresis performed approximately 10 weeks after disease onset showed resolution of monoclonal IgA

From the Columbia University Vagelos College of Physicians and Surgeons, New York<sup>a</sup>; Department of Dermatology, Columbia University Irving Medical Center, New York<sup>b</sup>; and Kimberly and Eric J. Waldman Department of Dermatology, Icahn School of Medicine at Mount Sinai, New York.<sup>c</sup>

Funding sources: None.

IRB approval status: Not applicable.

Correspondence to: Neha Kinariwalla, MPhil, Columbia University Vagelos College of Physicians and Surgeons, 161 Fort

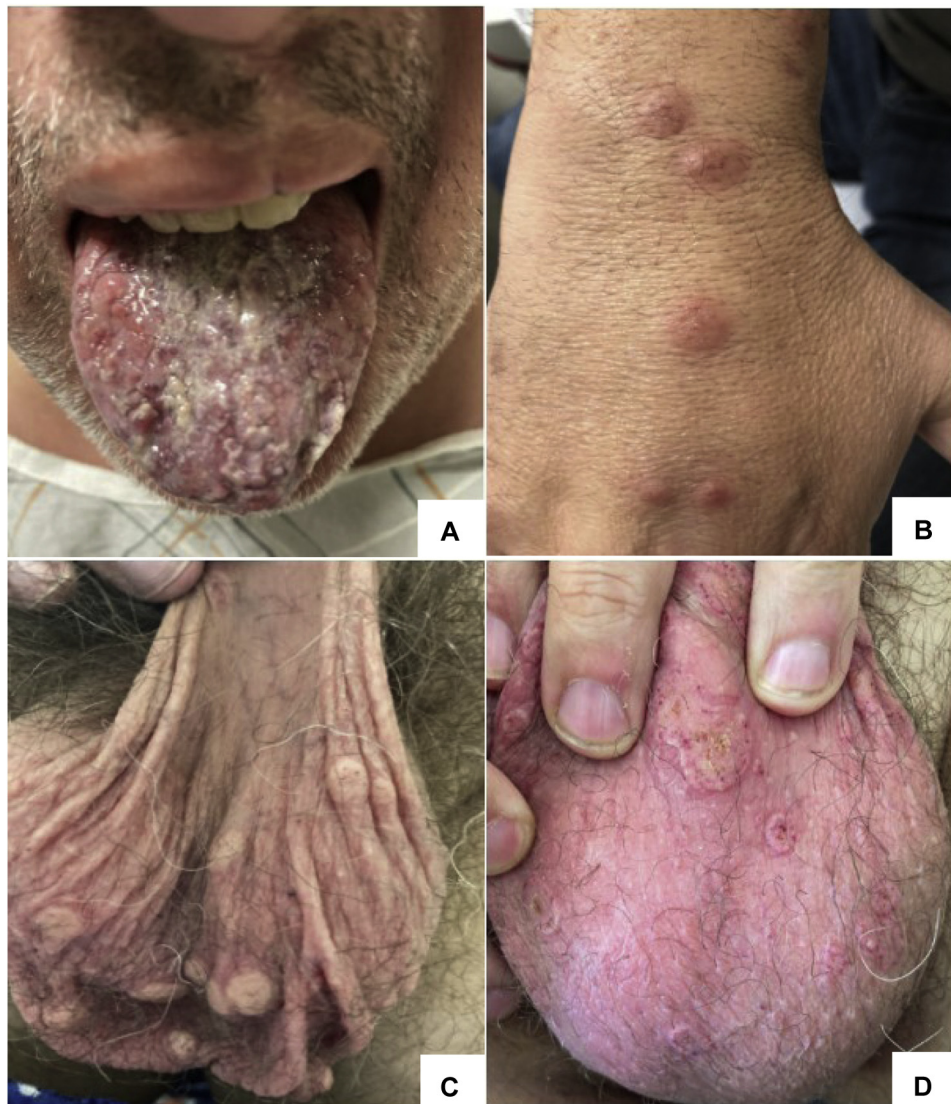Washington Ave, Herbert Irving Pavilion, 12th Floor, New York, NY 10032. E-mail: [nk2674@cumc.columbia.edu](mailto:nk2674@cumc.columbia.edu).

JAAD Case Reports 2022;19:64-7.

2352-5126

© 2021 by the American Academy of Dermatology, Inc. Published by Elsevier, Inc. This is an open access article under the CC BY-NC-ND license (<http://creativecommons.org/licenses/by-nc-nd/4.0/>).

<https://doi.org/10.1016/j.jidcr.2021.11.010>



**Fig 1.** Physical examination revealed an enlarged, erythematous painful tongue with many papules and fissures with overlying exudate (A); erythematous, firm nodules with slightly eroded centers on the dorsal aspects of the hands and extremities (B); tan, firm verrucous nodules, some with central pinpoint hemorrhage (C), which progressively became more targetoid in appearance (D).

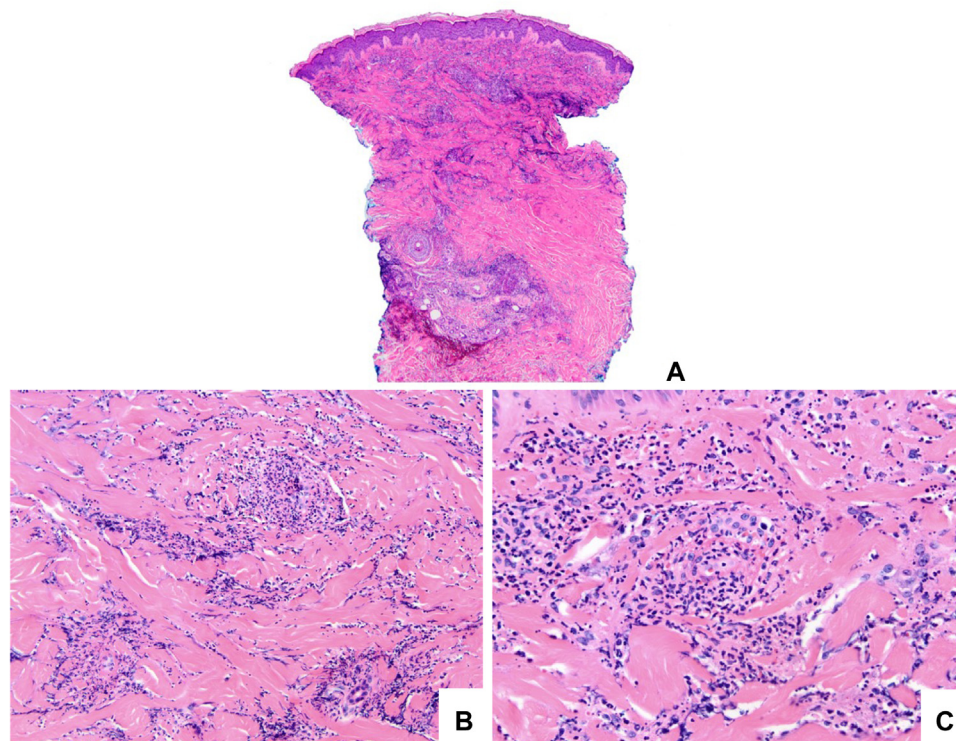
lambda. Thus, we diagnosed a case of SS with vasculitis and transient monoclonal IgA gammopathy, triggered by the Janssen Ad26.COV2.S vaccine.

## DISCUSSION

The major diagnostic criteria for SS include the abrupt onset of painful erythematous plaques or nodules and histopathologic evidence of neutrophilic dermal infiltrate without leukocytoclastic vasculitis.<sup>1</sup> The minor criteria for SS include fever; symptoms preceded by upper respiratory or gastrointestinal infections, or associated with vaccinations, malignancy, inflammatory disorders, or pregnancy;

abnormal white blood cell count and inflammatory markers; and improvement with systemic steroids. Although the absence of vasculitis has been a historical criterion for the diagnosis of SS, reports have suggested that vasculitis should not exclude this disorder.<sup>2,3</sup>

COVID-19 can infect endothelial cells, leading to intravascular inflammation and cutaneous vasculitis, and a recent study reported the appearance of monoclonal bands in the proteinogram of COVID-19 patients.<sup>4</sup> The data suggest that increased production of interleukin 6 results in differentiation of B-cells and hyperstimulation of the humoral response, resulting in



**Fig 2.** Hematoxylin–eosin–stained sections showing (A, B) a diffuse neutrophilic infiltrate in the interstitial dermis associated with prominent leukocytoclasia and (C) neutrophils surrounding and involving a blood vessel, which also exhibits fibrin deposition. (Original magnifications: A, ×40; B, ×200; C, ×400.)

aberrant immunoglobulin production and a transient plasma cell dyscrasia.<sup>4</sup> Class switching from immunoglobulin M to IgG/IgA typically occurs within 7 to 10 days, which coincides with this patient's onset of symptoms.<sup>5</sup> In fact, a robust postvaccination class switch from immunoglobulin M to IgA may account for his monoclonal gammopathy at the time of presentation. For our patient, given the transient nature of the monoclonal gammopathy, a consulting hematologist did not recommend further workup of his monoclonal gammopathy with bone marrow biopsy. There have been several reports of cutaneous vasculitis precipitation or exacerbation, including leukocytoclastic vasculitis, urticarial vasculitis, anti-neutrophil cytoplasmic antibody-associated vasculitis, and Henoch-Schönlein purpura, secondary to the use of current Food and Drug Administration-approved vaccines for SARS-CoV-2.<sup>6–9</sup> Our patient presented with generalized SS with histopathologic evidence of vasculitis 10 days after receiving the Janssen Ad26.COV2.S vaccine. We postulate that an immune response similar to COVID-19 infection was experienced in our recently vaccinated patient. Following treatment, the IgA monoclonal gammopathy resolved, highlighting the transient nature of immunoglobulin response and subsequent vasculitis. It is imperative for

physicians to be aware of these significant yet transient side effects and to understand that they are not a contraindication for vaccination against SARS-CoV-2.

#### Conflicts of interest

None disclosed.

#### REFERENCES

1. Ratzinger G, Burgdorf W, Zelger B. Sweet syndrome: vasculitis or not? *Br J Dermatol*. 2006;155(5):1099-1101.
2. Malone JC, Slone SP, Wills-Frank LA, et al. Vascular inflammation (vasculitis) in sweet syndrome: a clinicopathologic study of 28 biopsy specimens from 21 patients. *Arch Dermatol*. 2002;138(3):345-349.
3. Sahu K, Sirka CS, Pradhan S, Rout AN, Nayak S. Annular pattern of pustular vasculitis: a case report of unusual morphological presentation. *Indian Dermatol Online J*. 2020;11(2):232-234.
4. Farina A, Labriola R, Ialongo C, et al. Transient plasma cell dyscrasia in COVID-19 patients linked to IL-6 triggering. *Microbes Infect*. 2021;23(4-5):104808.
5. Stavnezer J, Schrader CE. IgH chain class switch recombination: mechanism and regulation. *J Immunol*. 2014;193(11):5370-5378.
6. Shakoort MT, Birkenbach MP, Lynch M. ANCA-associated vasculitis following Pfizer-BioNTech COVID-19 vaccine. *Am J Kidney Dis*. 2021;78(4):611-613.
7. Dash S, Behera B, Sethy M, Mishra J, Garg S. COVID-19 vaccine-induced urticarial vasculitis. *Dermatol Ther*. 2021;34(5):e15093.

8. AlGhoozi DA, AlKhayyat HM. A child with Henoch-Schonlein purpura secondary to a COVID-19 infection. *BMJ Case Rep.* 2021; 14(1):e239910.
9. Cohen SR, Prussick L, Kahn JS, Gao DX, Radfar A, Rosmarin D. Leukocytoclastic vasculitis flare following the COVID-19 vaccine. *Int J Dermatol.* 2021;60(8):1032-1033.