

# Sinovac COVID-19 vaccine—induced cutaneous leukocytoclastic vasculitis



Rungrot Bencharattanaphakhi, MD,<sup>a,b</sup> and Pawinee Rerknimitr, MD, MSc<sup>b</sup>  
Songkhla and Bangkok, Thailand

**Key words:** CoronaVac; COVID-19; Sinovac; vaccine; vasculitis.

## INTRODUCTION

During the COVID-19 pandemic, several vaccine platforms have been generated against this virus, including inactivated whole-virus vaccines, namely CoronaVac (Sinovac Life Sciences).<sup>1</sup> It is used particularly in Asia, the Middle East, and South America.<sup>2</sup> Dermatologic reactions such as erythema, swelling, and urticaria have been reported.<sup>1</sup> Cutaneous vascular inflammation, however, has not been reported from the use of Sinovac (CoronaVac). We, herein, report 2 cases of CoronaVac-induced cutaneous vasculitis.

## CASE SERIES

Patient A, a 23-year-old woman, and patient B, a 26-year-old woman, presented with nonblanchable, discrete, erythematous plaques with pinpoint purpura on the lower and upper extremities at 36 and 4 hours after CoronaVac administration, respectively (Fig 1). There were no current medications or recent systemic illness in either patient. Other physical examinations were unremarkable. Complete blood cell counts, blood chemistries, urinalyses, and erythrocyte sedimentation rates were normal. Hepatitis B, hepatitis C, and HIV serologies were negative. Tests for antinuclear antibodies and antineutrophil cytoplasmic antibodies were also negative, and tests for C3 and C4 were within normal limits in both patients, whereas CH50 was 30 U/mL (normal range, 41.8–95.6 U/mL), and thus slightly decreased, in only patient A. Skin biopsies from both patients showed evidence of leukocytoclastic vasculitis (LCV) (Fig 2, A and B). Direct immunofluorescence revealed C3

### Abbreviations used:

LCV: leukocytoclastic vasculitis  
mRNA: messenger RNA

and fibrinogen deposition around blood vessel walls in patient A and immunoglobulin M, C3, and IgA deposition in patient B (Fig 2, C and D). After 2 doses of intramuscular and 4 doses of intravenous dexamethasone (4 mg every 8 hours) followed by oral prednisolone (10 mg twice a day) for 5 days in patient A and oral colchicine (0.6 mg twice a day) and naproxen (250 mg twice a day) for 4 weeks in patient B, only mild postinflammatory hyperpigmentation remained. The second CoronaVac administration was introduced in patient A without cutaneous sequelae, whereas patient B refused the further dose. Follow-up urinalysis at 3 months in both patients was unremarkable; however, low CH50 levels persisted in patient A.

## DISCUSSION

Vasculitis is a rare cutaneous adverse event after vaccination. It has been reported from inactivated vaccines such as influenza, hepatitis B, and hepatitis A vaccines.<sup>3</sup> Among available COVID-19 vaccines, LCV was reported only after administering the messenger RNA (mRNA)-based platform (1 case from Pfizer-BioNTech [BNT162b2] and 2 cases from Moderna [mRNA-1273]).<sup>4,5</sup> Interestingly, no cases were reported from the use of CoronaVac, which is based on inactivated whole virus.

From the Division of Dermatology, Department of Pediatrics, Faculty of Medicine, Prince of Songkla University, Songkhla<sup>a</sup>; and Division of Dermatology, Skin and Allergy Research Unit, Department of Medicine, Faculty of Medicine, Chulalongkorn University, Bangkok.<sup>b</sup>

Funding sources: None.

IRB approval status: Approved by Research Ethics Committee, Faculty of Medicine, Chulalongkorn University (COA 996/2021).

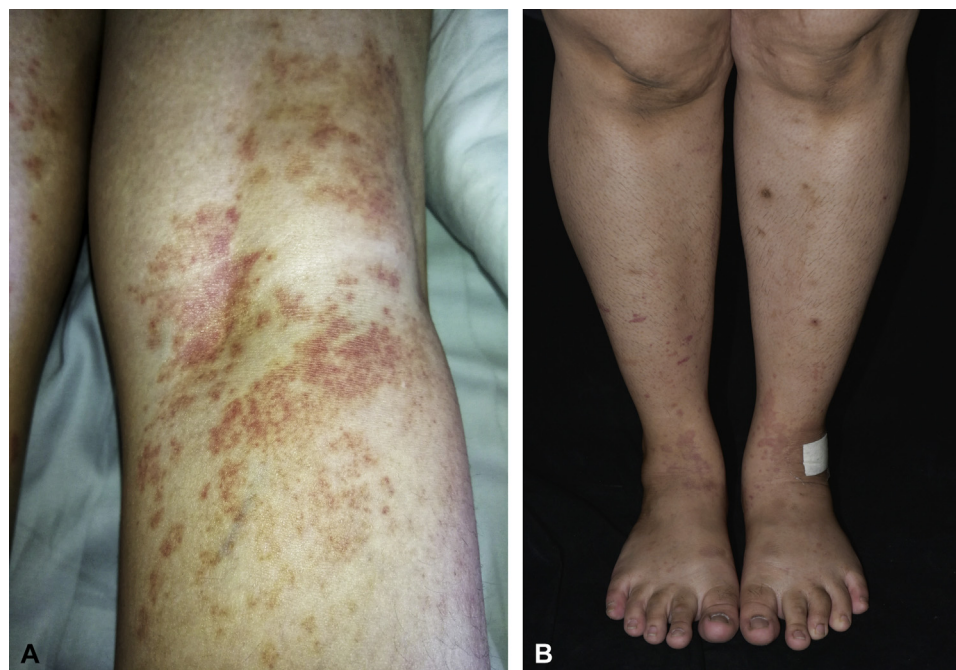
Correspondence to: Pawinee Rerknimitr, MD, MSc, Division of Dermatology, Skin and Allergy Research Unit, Department of Medicine, Faculty of Medicine, Chulalongkorn University, 1873

Rama IV Road, Pathumwan, Bangkok 10330, Thailand. E-mail: [pawinee.r@chula.ac.th](mailto:pawinee.r@chula.ac.th).

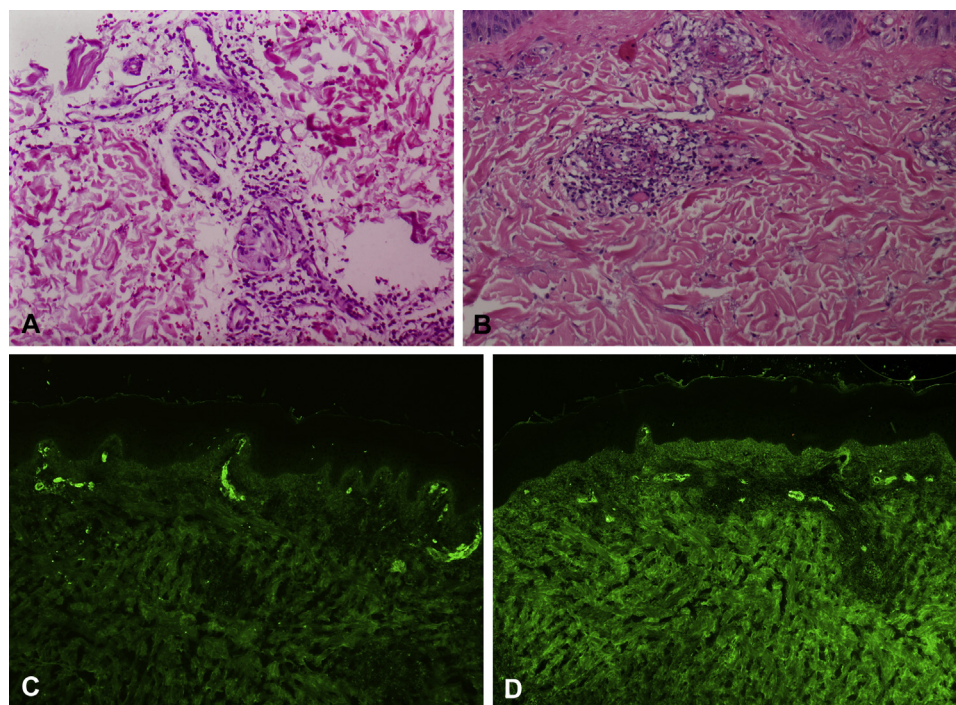
JAAD Case Reports 2021;18:■-■.  
2352-5126

© 2021 by the American Academy of Dermatology, Inc. Published by Elsevier, Inc. This is an open access article under the CC BY-NC-ND license (<http://creativecommons.org/licenses/by-nc-nd/4.0/>).

<https://doi.org/10.1016/j.jdc.2021.10.002>



**Fig 1.** Clinical manifestations of CoronaVac-induced leukocytoclastic vasculitis, Nonblanchable discrete erythematous plaques with pinpoint purpura. **A**, Patient A: eruptions on the lower and upper extremities. **B**, Patient B: eruptions on the lower extremities.



**Fig 2.** Histopathology of the skin specimen showed fibrinoid necrosis of blood vessels walls with neutrophils, neutrophilic fragments, and a few eosinophils in **(A)** patient A and without eosinophils in **(B)** patient B. Direct immunofluorescence microscopy demonstrated **(C)** C3 and **(D)** IgA deposition around blood vessels (patient B). (**A** and **B**, Hematoxylin-eosin stain; **C** and **D**, Direct immunofluorescence microscopy; original magnifications: **A**,  $\times 200$ ; **B**,  $\times 200$ ; **C**,  $\times 200$ ; **D**,  $\times 200$ .)

Vasculitis can be triggered by infections, namely hepatitis B and C.<sup>3</sup> It is worth noting that SARS-CoV-2 is notoriously responsible for skin findings associated with vascular pathology, such as chilblain-like lesions and retiform purpura. In addition, vasculitis has also been reported to be induced or exacerbated by SARS-CoV-2 infection.<sup>6,7</sup> Although the pathogenesis of vaccine-related LCV remains obscure, it is speculated that immune complexes comprising inactivated viral specific antigens and the abnormal antibody deposition in the blood vessel walls may cause complement activation, resulting in vascular damage.<sup>4</sup> However, it is unknown as to whether the viral particles or the excipients of the vaccine are responsible as an antigen for such reactions.

Although the isolated cutaneous LCV is the most common form of vaccine-related vasculitides, it can also be an early sign of deleterious systemic conditions.<sup>3</sup> Therefore, a prompt investigation for any systemic involvement in patients with vaccine-induced LCV should be undertaken. Our patients responded well to systemic corticosteroids and nonsteroidal antiinflammatory drugs. No recurrence was found in patient A after the second dose of CoronaVac. Similarly, recurrence of LCV after the second dose of COVID-19 mRNA vaccines did not occur.<sup>5</sup> As most of the available COVID-19 vaccines are administered in 2 doses, more vasculitis cases need to be observed before an appropriate vaccination course can be recommended for those with LCV from the first injection.

In conclusion, to our knowledge, this is the first report of 2 CoronaVac-induced cases of cutaneous

LCV. Health care professionals should be aware of the fact that the SARS-CoV-2 vaccine can trigger vascular inflammation.

The authors thank the Skin and Allergy Research Unit for their supports.

#### **Conflicts of interest**

None disclosed.

#### **REFERENCES**

1. Zhang Y, Zeng G, Pan H, et al. Safety, tolerability, and immunogenicity of an inactivated SARS-CoV-2 vaccine in healthy adults aged 18-59 years: a randomised, double-blind, placebo-controlled, phase 1/2 clinical trial. *Lancet Infect Dis*. 2021;21(2):181-192.
2. World Health Organization. Interim recommendations for use of the inactivated COVID-19 vaccine, CoronaVac, developed by Sinovac [WWW document]. Updated June 1, 2021. Accessed June 10, 2021. [https://www.who.int/publications/i/item/WHO-2019-nCoV-vaccines-SAGE\\_recommendation-Sinovac-Corona-Vac-2021.1](https://www.who.int/publications/i/item/WHO-2019-nCoV-vaccines-SAGE_recommendation-Sinovac-Corona-Vac-2021.1)
3. Bonetto C, Trotta F, Felicetti P, et al. Vasculitis as an adverse event following immunization—systematic literature review. *Vaccine*. 2016;34(51):6641-6651.
4. Cohen SR, Prussick L, Kahn JS, Gao DX, Radfar A, Rosmarin D. Leukocytoclastic vasculitis flare following the COVID-19 vaccine. *Int J Dermatol*. 2021;60(8):1032-1033.
5. McMahon DE, Amerson E, Rosenbach M, et al. Cutaneous reactions reported after Moderna and Pfizer COVID-19 vaccination: a registry-based study of 414 cases. *J Am Acad Dermatol*. 2021;85(1):46-55.
6. de Perosanz-Lobo D, Fernandez-Nieto D, Burgos-Blasco P, et al. Urticarial vasculitis in COVID-19 infection: a vasculopathy-related symptom? *J Eur Acad Dermatol Venereol* 2020;34(10):e566-e568.
7. Lind E, Jameson A, Kurban E. Fulminant granulomatosis with polyangiitis presenting with diffuse alveolar haemorrhage following COVID-19. *BMJ Case Rep*. 2021;14(6):e242628.