

## LETTERS TO THE EDITOR

## Cutaneous small-vessel vasculitis following COVID-19 vaccine

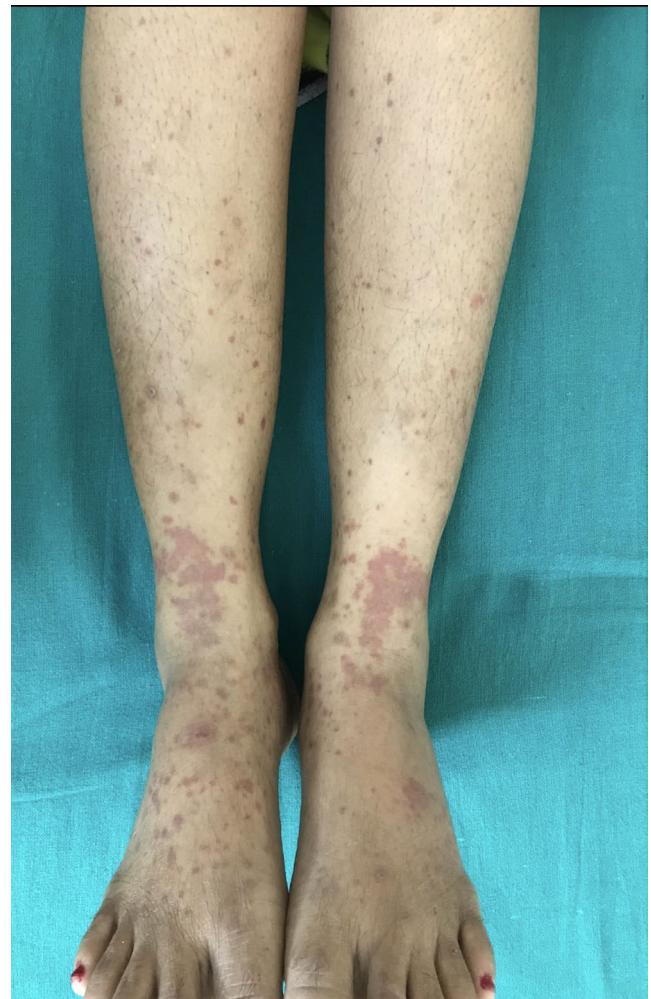
To the editor,

A 46-year-old woman presented to the outpatient department of dermatology with purpuric papules on her legs, arthralgia, and swelling of ankle joints for two days. She had no fever, cough, coryza, burning micturition, or any features suggestive of infection prior to the eruption. She had an unremarkable medical history. There was no history of any drug intake as well. She admitted to have received her first dose of COVID-19 vaccine with COVAXIN<sup>®</sup>, an inactivated viral vaccine five days prior to the onset of the skin lesions. On clinical examination, there were palpable purpuras over both legs mostly localized to lower legs along with pitting edema over the ankles [Figure 1]. Routine investigations, urine analysis, anti-streptolysin O titer, and anti-nuclear antibody were within normal limits except a mildly raised ESR. Reverse transcription (RT)-PCR for COVID-19 was negative from her throat and nasopharyngeal swab. Dermoscopy of the lesions showed purpuric dots or globules in a patchy brown background. Histopathology from the lesion showed unremarkable epidermis with focal hyperkeratosis, angiocentric inflammation with extravasation of red blood cells, leukocytoclasia, and fibrinoid necrosis of vessel walls [Figure 2]. Direct immunofluorescence could not be done. A diagnosis of Cutaneous small-vessel vasculitis secondary to inactivated SARS-CoV-2 vaccine, BBV152/ COVAXIN<sup>®</sup>, was made. The patient was advised to follow leg end elevation and rest. There was a complete recovery in 15 days with antihistamines, and the patient was followed up for a month without any recurrence.

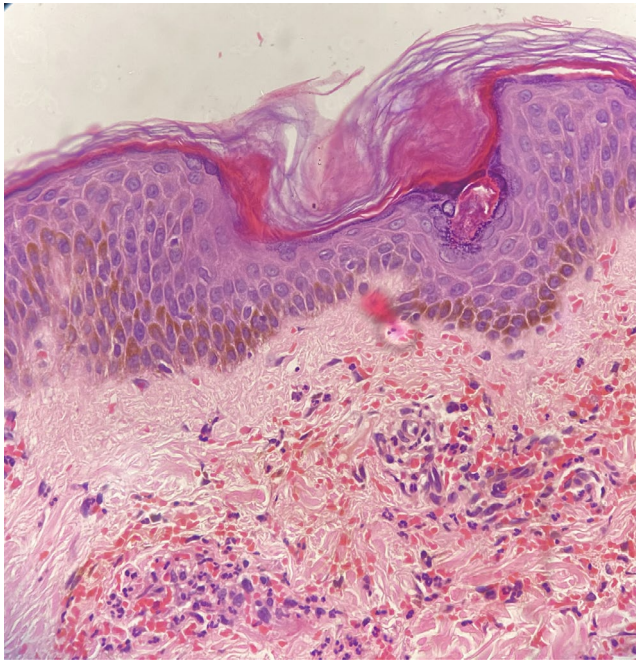
Cutaneous small-vessel vasculitis is known to be precipitated by infections, medications, and vaccinations. Several vaccines such as influenza vaccine, meningococcal B, hepatitis A vaccine, Hepatitis B, BCG, and HPV have been reported to be associated with small vessel cutaneous vasculitis.<sup>1</sup> With the ongoing pandemic, several COVID-19 vaccine agents have received emergency use approval. With more and more use, several cutaneous side effects of the COVID-19 vaccines are being increasingly reported. Heterogenous skin lesions such as chilblain, livedo reticularis-livedo racemosa and purpuric "vasculitic" papules, and acrodermatitis have been seen secondary to SARS-CoV-2 infection.<sup>2,3</sup> The SARS-CoV-2 virus causes immune system activation secondary to cross-reactivity and molecular mimicry with self-antigens, thereby causing vasculitis.<sup>4</sup> It is known to cause endothelial cell inflammation and dysfunction, triggering vasculitis. The vaccine proteins are structurally analogous to the wild viral antigens. The vaccine protein could induce pro-inflammatory cascade similar to that caused by the viral protein. Vaccine antigens possibly do activate

B/T cells and cause antibody formation and subsequent immune complex deposition in small-caliber vessels. Urticarial vasculitis and leukocytoclastic vasculitis have been reported with mRNA COVID-19 vaccines.<sup>5</sup> There are only limited cases of cutaneous vasculitis secondary to inactivated COVID-19 vaccine as seen in our case.<sup>6,7</sup>

Cutaneous small-vessel vasculitis secondary to infections, drugs, and vaccines have a less protracted course than the primary vasculitis. Dermatologists should be aware of the rare adverse reaction to COVID-19 vaccines and effectively manage the patient. However,



**FIGURE 1** Palpable purpuras over both legs mostly localized to lower legs along with pitting edema over the ankles



**FIGURE 2** Angiocentric inflammation with extravasation of red blood cells, leukocytoclasia, and fibrinoid necrosis of vessel walls. (H and E, 40x)

this should not be a deterrent to the use of COVID vaccine, which is the most effective weapon to curb the pandemic.

#### INFORMED CONSENT

Informed consent was taken from the patient for using the clinical data and publication of photographs after ensuring anonymity.

#### KEYWORDS

BBV152, Covaxin, COVID vaccine, COVID-19, Cutaneous vasculitis, dermatopathology, Leukocytoclasia, vasculitis

#### ACKNOWLEDGMENT

None.

#### CONFLICT OF INTEREST

None.

#### ETHICAL STATEMENT

Authors declare human ethics approval was not needed for this study.

Bikash Ranjan Kar MBBS, MD (Dermatology)

Bhabani STP Singh MBBS, MD (Dermatology)

Liza Mohapatra MBBS, MD (Dermatology)

Ishan Agrawal MBBS

Department of Dermatology, IMS and SUM Hospital,  
Bhubaneswar, India

Email: karbikash@gmail.com

Email: drbstp@gmail.com

Email: drlmohapatra@gmail.com

#### Correspondence

Ishan Agrawal, Department of Dermatology, IMS and SUM  
Hospital, Bhubaneswar, Odisha, India.  
Email: ishanagrawal1995@gmail.com

#### ORCID

Bikash Ranjan Kar <https://orcid.org/0000-0003-1504-1799>

Ishan Agrawal <https://orcid.org/0000-0002-9951-003X>

#### REFERENCES

1. Bonetto C, Trotta F, Felicetti P, et al. Vasculitis as an adverse event following immunization - Systematic literature review. *Vaccine*. 2016;34:6641-6651.
2. Marzano AV, Cassano N, Genovese G, Moltrasio C, Vena GA. Cutaneous manifestations in patients with COVID-19: a preliminary review of an emerging issue. *Br J Dermatol*. 2020;183(3):431-442.
3. Veraldi S, Beretta AE, Marletta DA, Wei Y. Commentary on "An Isolated Peculiar Gianotti-Crosti Rash in the Course of a COVID-19 Episode". *Acta Derm Venereol*. 2021;101:adv00399.
4. Vojdani A, Kharrazian D. Potential antigenic cross-reactivity between SARS-CoV-2 and human tissue with a possible link to an increase in autoimmune diseases. *Clin Immunol*. 2020;217:108480.
5. McMahon DE, Amerson E, Rosenbach M, et al. Cutaneous reactions reported after Moderna and Pfizer COVID-19 vaccination: A registry-based study of 414 cases. *J Am Acad Dermatol*. 2021;85:46-55.
6. Bostan E, Gulseren D, Gokoz O. New-onset leukocytoclastic vasculitis after COVID-19 vaccine. *Int J Dermatol*. 2021;10.1111/ijd.15777
7. Kharkar V, Vishwanath T, Mahajan S, Joshi R, Gole P. Asymmetrical cutaneous vasculitis following COVID-19 vaccination with unusual eosinophil preponderance. *Clin Exp Dermatol*. 2021;10.1111/ced.14797

**How to cite this article:** Kar BR, STP BS, Mohapatra L, Ishan A. Cutaneous small-vessel vasculitis following COVID-19 vaccine. *J Cosmet Dermatol*. 2021;20:3382-3383. <https://doi.org/10.1111/jocd.14452>