

Case report

Severe immune thrombocytopenic purpura after SARS-CoV-2 vaccine

Katherine M. Cooper^{*,1}, Bradley Switzer^{1,2}¹University of Massachusetts Medical School, Worcester, MA, USA; ²Reliant Medical Group, Worcester, MA, USA**Abstract**

Immune thrombocytopenic purpura (ITP) is a rare hematologic condition through to affect 3.3 in 100,000 adults per year in the United States. Many cases of immune thrombocytopenia are diagnosed incidentally with laboratory tests that reveal low platelet count, without a clear cause. However, when platelet counts are very low, patients may show signs of bleeding. Here we present the case of a 24-year-old female with mucocutaneous bleeding ten days after receiving her first dose of SARS-CoV-2 vaccine, who was subsequently found to have severe thrombocytopenia. Extensive work up for new thrombocytopenia was unremarkable suggesting a diagnosis of ITP, potentially secondary to vaccination. Empiric treatment with glucocorticoids was initiated without response prompting the use of intravenous immunoglobulin G. The patient was discharged on hospital day five with a platelet count over 20,000 platelets per microliter. In summary, ITP is a potential sequela of the SARS-CoV-2 vaccine, and otherwise healthy young individuals may be at risk for hematologic side effects.

Keywords: *Coronavirus vaccine; thrombocytopenia; immune reactions***Introduction**

Immune thrombocytopenic purpura (ITP) is an immune-mediated hematologic condition characterized by destruction of platelets [1]. The incidence of ITP is about 3.3 per 100,000 adults per year [2] and typically affects those 50-65 years old [3]. The diagnosis is one of exclusion; and is considered in patients with isolated thrombocytopenia (blood platelet count <100,000 platelets per microliter) without underlying conditions associated with platelet destruction [4]. Many patients are asymptomatic and are diagnosed incidentally on routine blood work. However, in severe thrombocytopenia (platelet count <30,000

platelets per microliter) patients are more likely to experience mucocutaneous bleeding and are at increased risk for life-threatening hemorrhage [5].

Diagnosis of primary ITP is made when there is no identifiable cause. Secondary ITP is diagnosed when the condition occurs in the setting of a trigger or another disease. Compared to children who often develop acute, post-viral ITP, adults experience insidious onset disease. This can make it difficult to isolate a trigger if one was present [6]. Etiologies to consider include underlying chronic disease, infection, medications and, in rare cases, vaccination. There have been reports of ITP in patients diagnosed SARS-CoV-2 viral infection and recent cases of thrombocytopenia in patients who have received a SARS-CoV-2 vaccine [7]. Here we report the case of a 24-year-old female with severe ITP ten days after receiving her first dose of SARS-CoV-2 vaccine.

Received: June 2021; Accepted after review: July 2021; Published: July 2021.

*Corresponding author: Katherine M. Cooper, University of Massachusetts Medical School, 55 N Lake Ave, Worcester, MA 01655, USA
Email: katherine.cooper@umassmed.edu



Case report

A 24-year-old Hispanic woman presented to our medical center with cutaneous and mucosal bleeding. The patient was in her usual state of health on the morning of admission day. In the evening she noticed raised purple lesions on her tongue and a diffuse rash consisting of regularly shaped, flat, purple spots on her legs. The patient sought out an urgent care where she was found to have critically low platelets with a platelet count of 1,000 platelets per microliter and was transferred to the Emergency Department. The patient noted the rash must have developed between 12:45 pm– 5:30 pm on the day of her admission. The rash was not associated with pain or pruritis. A full review of systems was performed which was negative other than presence of increased menstrual bleeding on the day of admission.

Past medical history is remarkable for dysfunctional uterine bleeding secondary to her Etonogestrel implant, mild asthma controlled with as needed albuterol inhaler, and vitamin D deficiency. The patient reported allergies to shellfish and penicillin, both of which give her hives. In addition, she reported a history of local reaction to a vaccine after receiving influenza vaccine and pneumonia

vaccine in same arm on same day in October 2019. She denied family history of bleeding disorders, hematologic conditions, and autoimmune conditions. She endorsed social drinking but denied use of tobacco products (including vape devices, cigarettes, smokeless tobacco) and other illicit drugs. There were no recent changes to her home environment. The patient denied recent allergic exposures, sick contact, or recent viral illness. However, she reported receiving her first dose of the Pfizer SARS-2-Coronavirus ten days prior. On physical examination, the patient was afebrile, hemodynamically stable, and showing no signs of active bleeding. On examination of the skin and mucous membranes, she had hemorrhagic bullae of the oral mucosa and tongue and a diffuse petechial rash of the bilateral lower extremities and abdomen with scant spots on her chest and proximal upper extremities (Figure 1). She had ecchymosis at the site of her blood draw which developed in less than one hour's time. The remainder of her examination was unremarkable, including absence of scleral icterus, hepatosplenomegaly, and lymphadenopathy. Laboratory tests admission were notable for isolated thrombocytopenia (Table 1). Polymerase chain reaction was negative for COVID-19 twice.

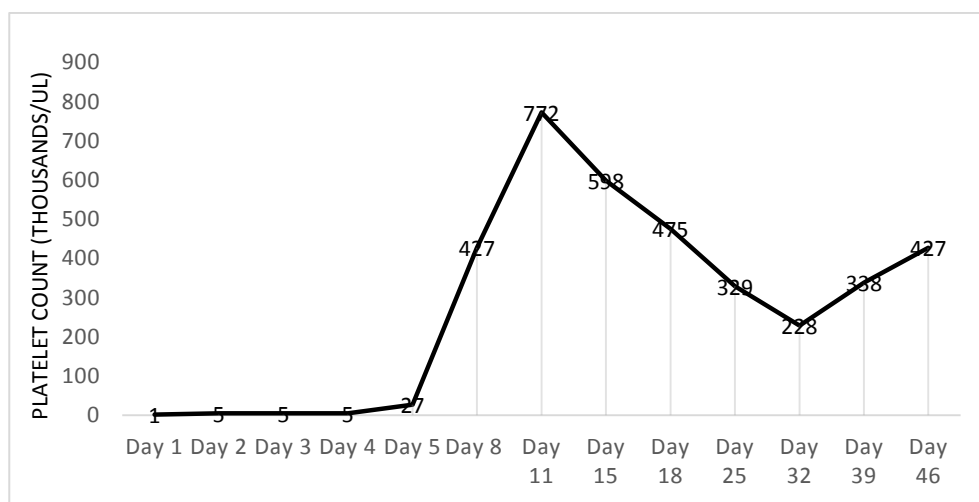


Fig. 1. Platelet Trends with platelet values reported in thousands/uL for patient with suspected ITP. Day 1 – day 5 were hospitalization days, while days 8 – 46 were collected at outpatient follow-up appointments. Prednisone treatment was initiated on day 1. Day 5 corresponds to the first laboratory value after treatment with intravenous immunoglobulin.

Table 1. Admission Laboratory Tests

Laboratory Test	Result
White Blood Cells (1000/uL)	9.3
Red Blood Cells (mil/uL)	4.73
Hemoglobin (g/dL)	13.2
Hematocrit (%)	40.4
Mean Corpuscular Volume (fL)	85.4
Red Blood Cell Distribution Width (%)	12.2
Platelets (x1000/uL)	1

*Results of complete blood count drawn in the emergency department (Day 1) from 24-year-old woman presenting with cutaneous and mucosal bleeding. Complete blood count was selected as it evaluates all cell lines. Results reported with standard units used in the United States; units are reported in parentheses next to each component of the test.

After admission, the patient provided a thorough family, social and past medical history. Medication reconciliation was completed and unremarkable for medications associated with platelet destruction. Family history of bleeding disorders were negative. The patient works as a dental assistant but denies history of exposures at work.

Laboratory investigations were initiated to rule out other causes of thrombocytopenia. Hemogram, coagulation panel and hemolytic work up (e.g., lactate dehydrogenase, haptoglobin) were within normal limits. Electrolytes were unremarkable. Peripheral smear revealed rare large platelets, normal red cell morphology, and normal white cell morphology. Infectious disease panel including HIV, Hepatitis C, Hepatitis B, and Helicobacter pylori were negative. Thyroid disease and autoimmune disorders were screened with TSH and ANA, respectively. CT of the chest was not obtained given two negative polymerase chain reaction tests and no clinical suspicion. Full work up yielded isolated thrombocytopenia in the severe range and empiric treatment for ITP was indicated.

The differential diagnosis of thrombocytopenia varies by clinical scenario and the number of cell lines involved. For example, critically ill and hospitalized patients may develop thrombocytopenia due to diffuse intravascular coagulation or bone marrow suppression. These conditions were considered highly unlikely in our patient, as they typically involve aberrations in more than

one cell line and have additional clinical signs and symptoms associated with severe illness. Our patient had normal hemoglobin, white blood cell count, and coagulation panel. Medications are another cause of thrombocytopenia that should always be considered, especially since it does not require any work up. Our patient took few medications and had no recent changes to her regimen. There are multiple infectious causes of thrombocytopenia, but our patient had no other symptoms and limited risk factors for the classic diseases. These were ruled out when she tested negative for COVID-19, HBV, HCV, and HIV. Hypothyroidism can also cause low platelets; however, the patient's thyroid was normal size and non-tender. She endorsed no symptoms of hypothyroid including weight gain, appetite changes, cold intolerance, and constipation. A normal TSH ruled hypothyroidism out. Rheumatologic conditions such as systemic lupus erythematosus are well characterized causes of thrombocytopenia in young adult women. However, these conditions are associated with aberrations in multiple cell lines and the presence of symptoms such as fatigue and arthralgias. Our patient was tested for these conditions and was negative for anti-nuclear antibody, c-reactive protein and erythrocyte sedimentation rate. Ultimately, in the otherwise healthy adult patient, ITP is the most likely cause of isolated thrombocytopenia.

Treatment for suspected ITP is recommended for adults with platelet count

less than 30,000 platelets per microliter, especially for individuals with clinical manifestations and examination findings. First line treatment includes corticosteroids and/or intravenous immunoglobulin. Options in steroid non-responders include thrombopoietin receptor agonists, rituximab, and in refractory cases, splenectomy. The patient was initiated on 80 milligrams oral dose of prednisone daily, consistent with standard first line therapy: prednisone 0.5–2.0 milligrams per kilogram [5]. After three days of this regimen, the patient's platelet count remained less than five platelets per microliter. Her platelet count was deemed unresponsive to steroids at that time, and intravenous immunoglobulin was initiated on Hospital Day 4 with a dose of one gram per kilogram of ideal body weight.

After one day of intravenous immunoglobulin, the patient's platelet count increased to 27,000 platelets per microliter, suggesting positive response. Transient response to intravenous immunoglobulin has

been associated with good outcomes in some populations [8]. The patient was discharged on a prednisone taper with instructions to reduce the dose by 10 mg daily every four days until stop (Day 36). Her discharge diagnosis was secondary ITP in relation to SARS-CoV-2 vaccine.

The patient's first follow up was one week after symptom onset. At that time, her laboratory tests continued to demonstrate responsiveness to treatment (Figure 2, Day 8). She was tolerating the prednisone well, with no unexpected side effects. The prednisone taper was continued and follow up with laboratory tests was scheduled twice weekly for the first two weeks following discharge before switching to weekly visits (Figure 2). Her platelet counts remained normal at eight weeks, and a bone marrow biopsy was deferred given her treatment response. She will be followed over the following 12 months to monitor for recurrence.

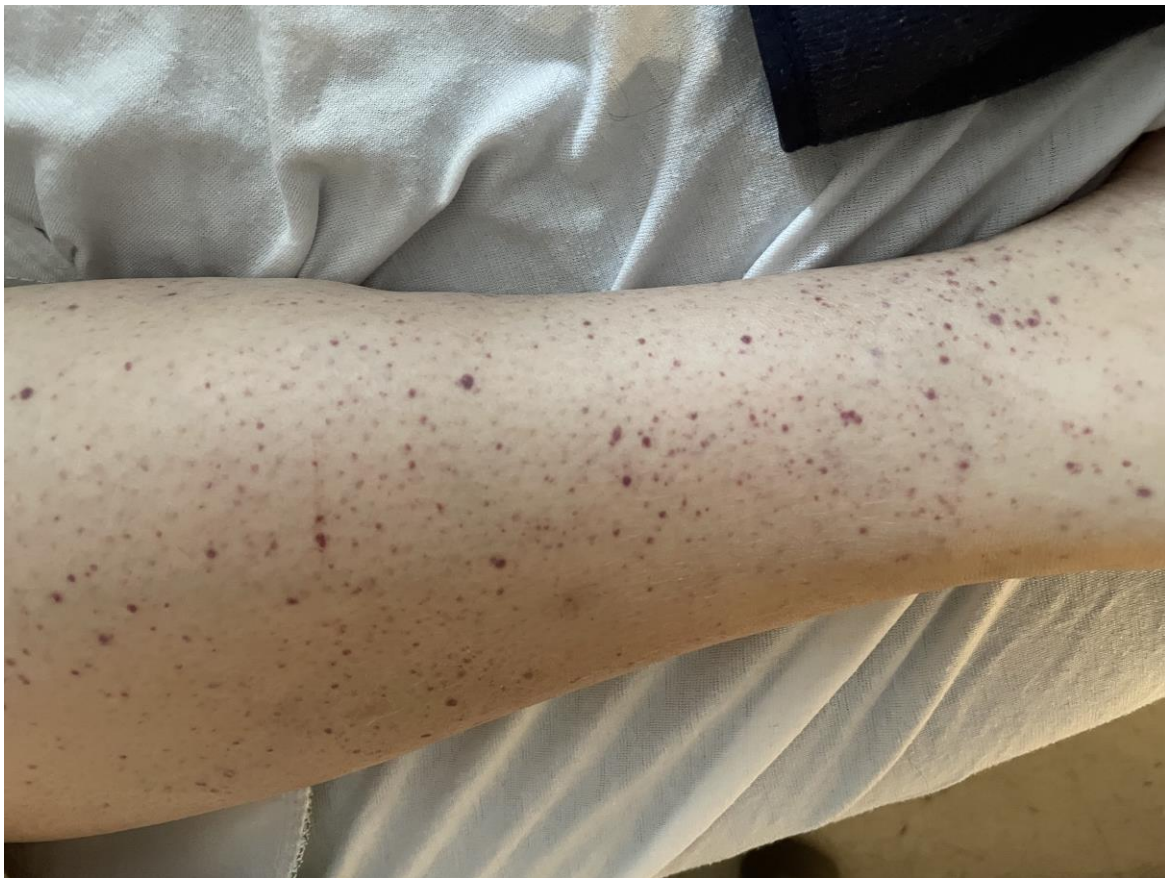

Fig. 2. Diffuse petechial rash on the patient's lower extremities (the right lower leg) - day two of hospitalization

Discussions

Here we present the case of severe isolated thrombocytopenia in an otherwise healthy young adult 10 days after vaccination for SARS2-Coronavirus. The patient's platelet count was non-responsive to steroids alone, however responded to intravenous immunoglobulin. Our work up was negative for platelet-destructive medications, infection, or underlying autoimmune conditions. The onset of thrombocytopenia in our patient suggests relation to the vaccine, and thus newly diagnosed secondary ITP.

Multiple vaccines have been implicated in ITP. Vaccinations rely on an intact immune response, and thus any vaccination can trigger the disease [9]. The mechanism by which messenger RNA vaccines may cause autoimmunity is not fully understood but is thought to involve processes like molecular mimicry and bystander activation [9]. While in most cases ITP has an insidious onset in adults, post-vaccination ITP is thought to occur within six weeks of vaccination. In the extreme, there are cases of post-vaccination ITP reported in adults as few as four days post vaccination [10].

Few serious side effects have been linked to the coronavirus vaccines to date [11]. However, cases of post-coronavirus vaccination ITP have been begun emerging in the literature. It is important to note, most have been in the setting of previous disease or published without case details [7]. In one case, a 22-year-old male was found to have new onset thrombocytopenia after the vaccine

but was subsequently found to have an elevated Sjogren's antibody [12].

It is interesting to note that this patient has a history of atopy and a previous local immune reaction. This immune reaction was limited to a raised red circle on her arm that was self-limited and not associated with changes to blood count. However, a history of previous reactions to vaccines may mark an increased risk of later adverse reactions. A strength of this case is the thorough immunologic and infectious work up completed, as well as the patient's response to standard therapy. Conversely, a weakness in this case is that the gold standard diagnosis of ITP is a bone marrow biopsy, which was not done for our patient given her recovery.

Conclusions

Overall, our case brings attention to potential sequelae of vaccination for SARS-2 Coronavirus. More work should be done to identify risk factors for this complication, and additional cases will be needed to establish the prognosis and to substantiate the optimal therapeutic approach.

Acknowledgement

There was no funding for this work. The authors declare that they have no competing interests. Written informed consent was obtained from the patient for publication of this case report and accompanying image.

References

1. Zufferey A, Kapur R, Semple JW. Pathogenesis and therapeutic mechanisms in immune thrombocytopenia (ITP). *J Clin Med* 2017; 6(2):16.
2. Terrell DR, Beebe LA, Vesely SK, Neas BR, Segal JB, George JN. The incidence of immune thrombocytopenia in children and adults: A critical review of published reports. *Am J Hematol* 2010; 85(3):174-180.
3. Abrahamson PE, Hall SA, Feudjo-Tepie M, Mitrani-Gold FS, Logie J. The incidence of idiopathic thrombocytopenic purpura among adults: a population-based study and literature review. *Eur J Haematol* 2009; 83(2):83-89.
4. Provan D, Stasi R, Newland AC, et al. International consensus report on the investigation and management of primary immune thrombocytopenia. *Blood* 2010; 115(2):168-186.
5. Cines DB, Bussel JB. How I treat idiopathic thrombocytopenic purpura (ITP). *Blood* 2005;106(7):2244-2251.
6. ITP A. Guidelines for the investigation and management of idiopathic thrombocytopenic



- purpura in adults, children and in pregnancy. *Br J Haematol* 2003; 120(1):574-596.
7. Lee EJ, Cines DB, Gernsheimer T, et al. Thrombocytopenia following Pfizer and Moderna SARS-CoV-2 vaccination. *Am J Hematol* 2021; 96(5):534-537 doi: 10.1002/ajh.26132. Epub 2021 Mar 9.
 8. Choi HS, Ji MH, Kim SJ, Ahn HS. Platelet count recovery after intravenous immunoglobulin predicts a favorable outcome in children with immune thrombocytopenia. *Blood res* 2016; 51(2):95.
 9. Guimaraes LE, Baker B, Perricone C, Shoenfeld Y. Vaccines, adjuvants and autoimmunity. *Pharmacol Res* 2015; 100:190-209.
 10. Perricone C, Ceccarelli F, Nesher G, et al. Immune thrombocytopenia (ITP) associated with vaccinations: a review of reported cases. *Immunol Res* 2014; 60(2-3):226-235.
 11. Polack FP, Thomas SJ, Kitchin N, et al. Safety and Efficacy of the BNT162b2 mRNA Covid-19 Vaccine. *N Engl J Med* 2020; 383(27):2603-2615.
 12. Tarawneh O, Tarawneh H. Immune thrombocytopenia in a 22-year-old post Covid-19 vaccine. *Am J Hematol* 2021; 96(5):E133-E134. doi: 10.1002/ajh.26106.