

## Case Report

## Lobar bleeding with ventricular rupture shortly after first dosage of an mRNA-based SARS-CoV-2 vaccine

Josef Finsterer\*

Klinik Landstrasse, Messerli Institute, Vienna, Austria

## ARTICLE INFO

## Article history:

Received 28 September 2021

Received in revised form 20 October 2021

Accepted 22 October 2021

Available online 28 October 2021

## Keywords:

SARS-CoV-2

COVID-19

Vaccination

Side effect

Adverse reaction

Intracerebral bleeding

## ABSTRACT

Vaccination against SARS-CoV-2 is beneficial but may be rarely accompanied by side effects. We report a 67yo female who developed visual impairment, dysarthria, confusion, and fatigue a few hours after a first dosage with an mRNA-based SARS-CoV-2 vaccine (Pfizer). Her previous history listed diabetes, arterial hypertension, arterial occlusive disease, a single renal cyst on the left side, smoking, and ischemic stroke 20y earlier. Stroke was complicated by normal pressure hydrocephalus requiring placement of a ventriculo-atrial (VA)-shunt. Cerebral imaging revealed a right-sided intracerebral bleeding with ventricular rupture and correct placement of the VA-shunt. Neurosurgeons decided against surgical treatment. The further course was dominated by prolonged confusion, visual impairment, and disorientation but ultimately only minor deficits. In conclusion, a single patient experienced intracerebral bleeding with ventricular rupture shortly after application of the first jab of an mRNA-based SARS-CoV-2 vaccine. Whether bleeding was causally related to the vaccination or occurred coincidentally, remains speculative. © 2021 International Hemorrhagic Stroke Association. Publishing services by Elsevier B.V. on behalf of KeAi Communications Co. Ltd. This is an open access article under the CC BY-NC-ND license (<http://creativecommons.org/licenses/by-nc-nd/4.0/>).

## 1. Introduction

There is an increasing number of publications reporting putative adverse reactions to mRNA-based SARS-CoV-2 vaccines.<sup>1,2</sup> These reports raised concerns about the safety of SARS-CoV-2 vaccines and led either to restrictions with the indication of the vaccine or to withdrawal of the compound from the market at least in some countries. One of the repeatedly observed complications of a SARS-CoV-2 infection is disturbed coagulation, manifesting either as hypercoagulability (venous thrombosis) or as hypocoagulability (bleeding). Bleeding as a side effect of SARS-CoV-2 vaccines has not been reported but is known as a neurological complication of SARS-CoV-2 infections.<sup>3</sup> Here we report intra-cerebral bleeding shortly after application of the first dosage of an mRNA-based SARS-CoV-2 vaccine.

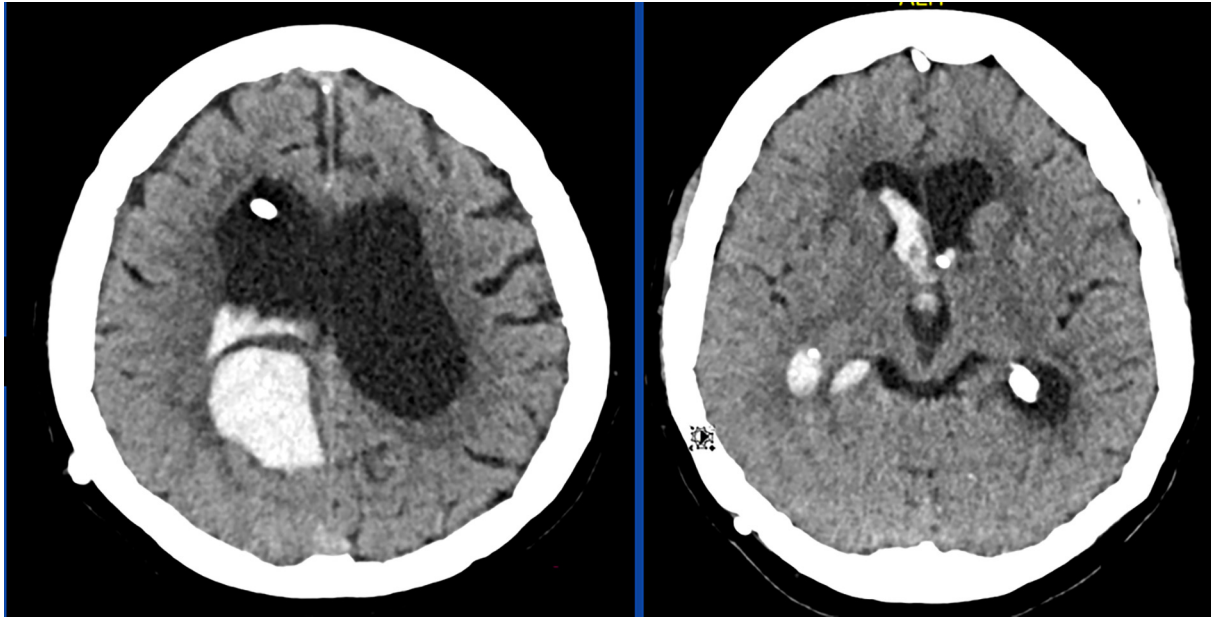
## 2. Case report

The patient is a 67yo female, height 163 cm, weight, 77 kg, who presented with visual impairment, dysarthria, confusion, and fatigue. Her previous history was positive for vaccination with an mRNA-based SARS-CoV-2 vaccine (Pfizer) a few hours earlier, dia-

betes, arterial hypertension, smoking (20cig/d), arterial occlusive disease, a single renal cyst on the left side, endoscopic cholecystectomy, cervical conisation, and ischemic stroke 20y earlier. The previous stroke had been complicated by normal pressure hydrocephalus communicating requiring implantation of a ventriculo-atrial (VA)-shunt. Her medication on admission included escitalopram, metformin, folic acid, tramadol, lisinopril, rosuvastatin, doxazosin, and rilmenidin. Clinical neurologic exam on admission revealed bradyphrenia, neglect to the left, gaze palsy to the right, and hemianopia to the left, corresponding with an NIHSS score of 3. Blood pressure was normal. Multimodal cerebral MRI revealed a right parietal, lobar bleeding with ventricular rupture and a VA-shunt from the right side with the shunt tip in the anterior horn of the left lateral ventricle (Fig. 1). Neurosurgeons did not recommend surgical removal of the bleeding. Functionality of the VA-shunt was confirmed. Blood tests were non-informative except for mildly elevated D-dimer of 0.89 mg/L (n: <0.5 mg/L). Follow-up cerebral CT scan did not show progressive widening of the ventricular system why the shunt adjustment was not changed. CT-angiography of the cerebral vessels did not reveal a source of the bleeding. During the following days the patient presented with confusion and visual impairment but was able to walk, speak, and swallow without restriction.

\* Corresponding author at: Postfach 20, 1180 Vienna, Austria.

E-mail address: [fifigs1@yahoo.de](mailto:fifigs1@yahoo.de)



**Fig. 1.** CT-scan of the brain showing an intracerebral bleeding in the right parietal region with ventricular rupture and blood within the 1st and 3rd ventricle. To prevent the development of hydrocephalus, a ventricular drainage had been placed from the right frontal side.

### 3. Discussion

The patient is interesting for a putative, adverse reaction to the first dose of an mRNA-based SARS-CoV-2 vaccine. Whether intraxial bleeding with ventricular rupture occurring a few hours after the first dosage of an mRNA-based SARS-CoV-2 vaccination was causally related to the vaccination remains speculative. Arguments for a causal relation are that an infection with SARS-CoV-2 can be complicated by coagulation disorders, leading more frequently to hyper-coagulation than hypo-coagulation with bleeding,<sup>4</sup> that the bleeding occurred time-locked to application of the vaccine, that thrombocytopenia due to SARS-CoV-2 vaccination has been reported,<sup>5</sup> that neurological side effects to the vaccination have been repeatedly reported,<sup>6</sup> and that bleeding also occurs after the second dose of mRNA-based vaccines.<sup>7</sup> Venous thrombosis has been even reported after the second dose of an mRNA-based SARS-CoV-2 vaccine.<sup>8</sup> Arguments against a causal relation, however, are that the patient had micro- and macro-angiopathy appropriate to her cardiovascular risk profile, that bleeding after a SARS-CoV-2 vaccination has not been reported as an adverse reaction, and that serological coagulation parameters were within normal limits except for a mildly elevated D-dimer.

The bleeding can be explained by several scenarios. First, it was simply due to a hypertensive crisis and causally unrelated to the previous vaccination. Second, it was causally related to the vaccination and due immune thrombocytopenia, which is a well-known complication of SARS-CoV-2 vaccinations (vaccine-induced thrombotic thrombocytopenia (VITT))<sup>5,9</sup> monoglyc and can be associated with intra-cerebral bleeding (ICB) due to the low counts of dysfunctional thrombocytes<sup>10,11</sup> witting, fi. A strong argument against thrombocytopenia, however, is that the thrombocyte count was normal throughout hospitalisation. A third explanation could be that the ICB masqueraded in fact a venous sinus thrombosis (VST) that was complicated by ischemic stroke and consecutive bleeding. Arguments against this speculation, however, are that the D-dimer was only mildly elevated, that clinical presentation was not typical for VST, that VST is only rarely complicated by massive ICB,<sup>12</sup> and that the MRI did not show VST. A fourth speculation assumes that SARS-CoV-2 directly reduces the production of vari-

ous coagulation factors which consecutively results in hypocoagulability. However, there were no indications for hypocoagulability in the index patient, why the cause of bleeding remains speculative.

### 4. Conclusions

Intracerebral bleeding with ventricular rupture may occur shortly after the first dosage of an mRNA-based SARS-CoV-2 vaccine. To establish or exclude a causal relation between vaccination and the bleeding, systematic, controlled cohort studies are required.

### Ethics approval

The study was approved by the ethics committee of the Mes-serli Institute. All clinical practices and observations were conducted in accordance with the Declaration of Helsinki.

### Declaration of competing interest

The author declares that she has no conflicts of interests to this work. We declare that we do not have any commercial or associative interest that represents a conflict of interest in connection with the work submitted.

### Informed consent

Informed consent was obtained from patient included in the study.

### Patient consent

Informed consent was obtained from patient for publication of this manuscript.

### Consent for publication

The author has consented for publication of this manuscript.

### Funding

None received.

### Authors contribution

JF: design, literature search, discussion, first draft, critical comments.

### Acknowledgements

None.

### References

1. Kaur RJ, Dutta S, Bhardwaj P, et al. Adverse events reported from COVID-19 vaccine trials: A systematic review. *Indian J Clin Biochem.* 2021;27:1–13.
2. Rutkowski K, Mirakian R, Till S, Rutkowski R, Wagner A. Adverse reactions to COVID-19 vaccines: a practical approach. *Clin Exp Allergy.* 2021;51(6):770–777.
3. Lang CN, Dettinger JS, Berchtold-Herz M, et al. Intracerebral hemorrhage in COVID-19 patients with pulmonary failure: A propensity score-matched registry study. *Neurocrit Care.* 2021;34(3):739–747.
4. Al-Mufti F, Amuluru K, Sahni R, et al. Cerebral venous thrombosis in COVID-19: A New York metropolitan cohort study. *AJNR Am J Neuroradiol.* 2021;42(7):1196–1200.
5. Greinacher A, Thiele T, Warkentin TE, Weisser K, Kyrle PA, Eichinger S. Thrombotic thrombocytopenia after ChAdOx1 nCov-19 vaccination. *N Engl J Med.* 2021;384(22):2092–2101.
6. Li X, Ostropolets A, Makadia R, et al. Characterizing the incidence of adverse events of special interest for COVID-19 vaccines across eight countries: a multinational network cohort study. medRxiv. 2021 Mar 28:2021.03.25.21254315. doi: 10.1101/2021.03.25.21254315.
7. Finsterer J, Korn M. Aphasia seven days after second dose of an mRNA-based SARS-CoV-2 vaccine. *Brain Hemorrhages.* 2021.
8. Carli G, Nichele I, Ruggeri M, Barra S, Tosetto A. Deep vein thrombosis (DVT) occurring shortly after the second dose of mRNA SARS-CoV-2 vaccine. *Intern Emerg Med.* 2021;16(3):803–804.
9. Monagle P, Ng AP, Linden M, et al. Vaccine-induced immune thrombosis and thrombocytopenia syndrome following adenovirus-vectored severe acute respiratory syndrome coronavirus 2 vaccination: a novel hypothesis regarding mechanisms and implications for future vaccine development. *Immunol Cell Biol.* 2021.
10. Wilting FNH, Kotsopoulos AMM, Platteel ACM, van Oers JAH. Intracerebral hemorrhage and thrombocytopenia after AstraZeneca COVID-19 vaccine: Clinical and diagnostic challenges of vaccine-induced thrombotic thrombocytopenia. *Cureus.* 2021;13(9).
11. Finsterer J, Redzic Z. Symptomatic peduncular, cavernous bleeding following SARS-CoV-2 vaccination induced immune thrombocytopenia. *Brain Hemorrhages.* 2021.
12. Purkayastha P, Mckechnie C, Kalkur P, Scully M. Rare case of COVID-19 vaccine-associated intracranial haemorrhage with venous sinus thrombosis. *BMJ Case Rep.* 2021;14(9):e245092.