

Lessons of the month 3: Haemophagocytic lymphohistiocytosis following COVID-19 vaccination (ChAdOx1 nCoV-19)

Authors: Philippa Cory,^A Hannah Lawrence,^B Hunar Abdulrahim,^C Hamzah Mahmood-Rao,^D Azza Hussein^E and Jennie Gane^F

ABSTRACT

A 36-year-old woman presented to hospital 9 days after receiving her first dose of the ChAdOx1 nCoV-19 vaccine with fever, myalgia and a sore throat. She was previously fit and well with no prior vaccine reactions.

There was no clinical response to initial treatment with intravenous (IV) antibiotics. Microbiology tests including for COVID-19 were negative. At day 5, she developed pleuritic pain and a pericardial rub. Echocardiography and subsequent cardiac magnetic resonance imaging showed evidence of constrictive pericarditis. Computed tomography revealed gross hepatomegaly and moderate splenomegaly. Blood tests showed raised inflammatory markers, deranged clotting, low platelets and a marked hyperferritinaemia.

A presumptive diagnosis of a multi-system inflammatory disorder secondary to recent COVID-19 vaccination was made and high-dose IV methylprednisolone initiated. Following a high 'H score' of 70%–80% a diagnosis of secondary haemophagocytic lymphohistiocytosis (HLH) was made. She was treated with IV immunoglobulin with subsequent clinical response.

HLH is a rare syndrome of acute and rapidly progressive systemic inflammation characterised by cytopenias, excessive cytokine production and hyperferritinaemia. The adult form has multiple triggers, including recent vaccination. This case prompts awareness among clinicians of HLH as a rare complication of COVID-19 vaccination but should not discourage individuals from vaccination.

KEYWORDS: HLH, covid, vaccination, inflammation, hyperferritinaemia

DOI: 10.7861/clinmed.2021-0564

Case presentation

A 36-year-old woman, a carer with no previous medical history, presented to hospital with fever, myalgia and sore throat. She had received a first dose of the ChAdOx1 COVID-19 vaccination (Oxford–AstraZeneca) 9 days previously. Three days post-vaccine, she experienced mild facial swelling that resolved with oral antihistamines. At day 5, she developed fever ($>42^{\circ}\text{C}$) and severe myalgia. Her symptoms progressed despite simple analgesia and she was admitted to hospital. Medication, family, travel and sexual histories were unremarkable. She reported no previous adverse reactions to vaccines, or allergies to food or drugs. Admission observations were a temperature of 39.9°C , respiratory rate of 32 breaths per minute, heart rate of 137 beats per minute, blood pressure of 104/65 mmHg and oxygen saturations of 97% on air. Clinical examination was unremarkable except mild right upper quadrant abdominal tenderness with hepatomegaly. There was no rash, joint-swelling or synovitis.

Admission electrocardiography showed sinus tachycardia. Chest X-ray was unremarkable. Urine dip was positive for protein, ketones and haemoglobin. Inflammatory markers were raised with normal renal, liver and coagulation screens (Table 1). Serial viral polymerase chain reaction (PCR) tests for SARS-CoV-2 infection and routine microbiology tests (blood and urine cultures, respiratory viral PCR screen, urinary antigens for *Legionella* and pneumococcus) were all negative. Serological testing for cytomegalovirus (CMV), Epstein–Barr virus (EBV), HIV, and hepatitis B and C showed no evidence of active or prior infection. She was treated for suspected sepsis secondary to infection of uncertain aetiology with IV piperacillin/tazobactam, analgesia and fluids.

After 5 days in hospital, she remained pyrexial, tachycardic and tachypnoeic and developed pleuritic pain and a pericardial rub. Repeat bloods showed increasing C-reactive protein of 339 mg/L, white cell count of $33.5 \times 10^9/\text{L}$, neutrophils of $31.2 \times 10^9/\text{L}$, marked hyperferritinaemia of 12,423 $\mu\text{g}/\text{L}$ and deranged clotting with raised fibrinogen (prothrombin time of 16 seconds, activated partial thromboplastin time of 31 seconds and fibrinogen of 5.5 g/L) but normal haemoglobin, platelets

Authors: ^AIMT3 doctor, University Hospitals of Derby and Burton NHS Foundation Trust, Derby, UK; ^Brespiratory registrar, University Hospitals of Derby and Burton NHS Foundation Trust, Derby, UK; ^Clocum rheumatology consultant, University Hospitals of Derby and Burton NHS Foundation Trust, Derby, UK; ^Dconsultant in rheumatology and general medicine, University Hospitals of Derby and Burton NHS Foundation Trust, Derby, UK; ^Erheumatology consultant, University Hospitals of Derby and Burton NHS Foundation Trust, Derby, UK; ^Frespiratory consultant, University Hospitals of Derby and Burton NHS Foundation Trust, Derby, UK

Table 1. Investigations summary

	Day 1	Day 7
Biochemistry		
Urea and electrolytes	Normal	Normal
C-reactive protein, mg/L	207	339
Alanine transaminase, U/L	38	15
Alkaline phosphatase, U/L	76	245
Albumin, g/L	36	17
Albumin adjusted calcium, mmol/L	2.19	2.07
Creatine kinase, U/L	42	390
Lactate dehydrogenase, U/L	-	351
Procalcitonin, ng/mL	-	38.7
Ferritin, µg/L	-	12,423
Triglycerides, mmol/L	-	1.8
Haematology		
Haemoglobin, g/L	140	115
White cell count, × 10 ⁹ /L	12.8	28.7
Platelets, × 10 ⁹ /L	210	243
Prothrombin time, seconds	12	16
Activated partial thromboplastin time, seconds	25	31
Fibrinogen, g/L	-	5.5
Erythrocyte sedimentation rate, mm/hour	-	7
Immunology		
Immunoglobulins	Normal	
Antinuclear antibody, extractable nuclear antigen antibody, antineutrophil cytoplasmic antibody and liver autoantibody screen	Negative	
Microbiology		
Blood cultures (nine sets)	All negative	
Urine cultures	Negative	
Respiratory viral screen (influenza A & B, respiratory syncytial virus, parainfluenza, enterovirus, rhinovirus, metapneumovirus, adenovirus and seasonal coronavirus)	Negative	
Urinary antigens (<i>Legionella</i> and <i>Streptococcus pneumoniae</i>)	Negative	
Mycoplasma pneumoniae	Negative	
HIV serology	Negative	
Epstein–Barr virus serology	Negative	
Cytomegalovirus serology	Negative	

and erythrocyte sedimentation rate. Computed tomography of the thorax, abdomen and pelvis revealed gross hepatomegaly, moderate splenomegaly and small bilateral pleural effusions, but no lymphadenopathy. Electrocardiography demonstrated ST

elevation in leads V1–2 and serial troponins were 162 ng/L and 154 ng/L. Findings on bedside echocardiography and subsequent cardiac magnetic resonance imaging (MRI) were consistent with constrictive pericarditis. Thoracic ultrasound showed simple bilateral anechoic pleural effusions. MRI of brain and spine were normal.

Given the features of fever, hepatosplenomegaly, hyperferritinaemia, coagulopathy and pericarditis in the absence of evidence for infection or malignant disease, a presumptive diagnosis of a multi-system inflammatory disorder secondary to recent COVID-19 vaccination was made. Pulsed intravenous (IV) methylprednisolone (1 g/day for 3 consecutive days) was started followed by high-dose oral prednisolone (60 mg once daily). Her temperature, pulse and respiratory rate normalised within 12 hours of initiating steroids and concurrent symptomatic and biochemical improvements were observed (Fig 1).

However, 6 days later her fever resumed, and she developed a thrombocytopenia (platelets of 70 × 10⁹/L). Repeat septic screen was negative. Bone marrow biopsy showed a reactive picture. A 5-day course of IV immunoglobulins was initiated that resulted in resolution of her fever and improvement in her myalgia and chest pain. The patient was discharged home after 33 days to continue her recovery on a weaning course of oral prednisolone.

Discussion

Haemophagocytic lymphohistiocytosis (HLH) is a rare syndrome of acute and rapidly progressive systemic inflammation characterised by cytopenias, excessive cytokine production and hyperferritinaemia.¹ Abnormal activation of pro-inflammatory cytokines results in the over-activation and proliferation of macrophages, hypersecretion of cytokines (predominantly interleukin (IL) 1, IL-6 and tumour necrosis factor alpha) termed the 'cytokine storm', and phagocytosis of haematopoietic cells within the bone marrow.² This results in the clinical constellation of fever, lymphadenopathy, hepatosplenomegaly and multi-organ failure.² Diagnosis is challenging as it presents as a non-specific illness and mimics sepsis. The condition is classified as primary or secondary. Primary (familial) HLH is a rare condition caused by genetic mutations that presents in childhood. Secondary HLH is the more common form in adulthood. Known triggers include viral infections (CMV, EBV and SARS-CoV-2), malignancy, autoimmune disorders (eg adult-onset Still's disease and systemic lupus erythematosus) and drugs.²

Several differing diagnostic criteria to define HLH exist; however, these were largely developed around paediatric populations.³ The diagnostic H score was developed from a cohort of patients with secondary HLH and our patient fulfilled a diagnosis of HLH using this tool.⁴ Therapeutic options outlined by HLH treatment protocol include steroids, etoposide, cyclosporin, immunoglobulins and biologics such as IL-1 inhibitors (anakinra) and IL-6 inhibitors (tocilizumab).⁵ Prognosis of HLH is poor with a high mortality, particularly malignancy-associated HLH.⁵

In this patient, her symptoms developed within days of the Oxford–AstraZeneca COVID-19 vaccination suggesting a potential causal link. It was reported via the Medicines and Healthcare products Regulatory Agency COVID-19 Yellow Card system.⁶ An alternative disease trigger was not identified despite thorough investigation. In particular, no evidence for active or prior

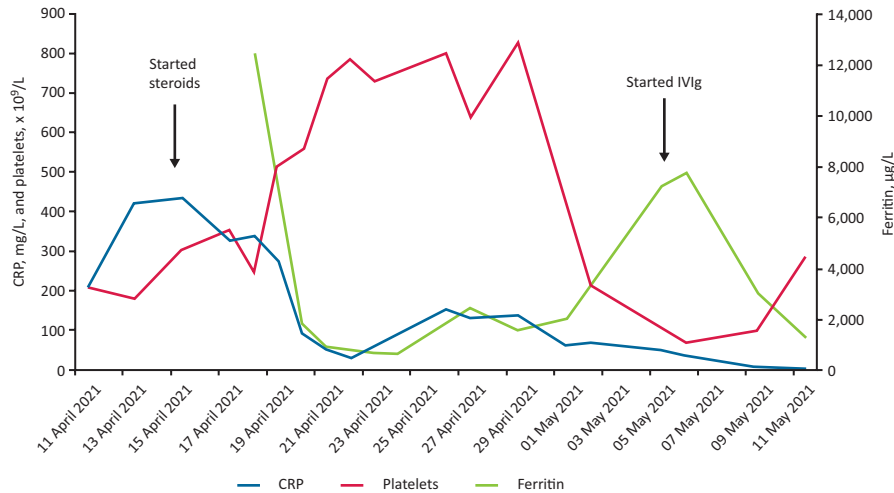


Fig 1. Changes in C-reactive protein, platelets and ferritin during admission. CRP = C-reactive protein; Ig = immunoglobulins; IV = intravenous.

SARS-CoV-2 infection was identified, although antibody tests were not performed.

The ChAdOx1 nCoV-19 vaccine uses a modified adenovirus ChAdOx1 as a viral vector to introduce the SARS-CoV-2 spike protein to cells, inducing an antibody and T-cell mediated response. The frequently reported self-limiting adverse reactions include injection-site tenderness, pyrexia, fatigue, myalgia and arthralgia.⁷ It has been linked to rare severe cerebral venous sinus thrombosis occurring in conjunction with low platelets and this is believed to be an immune phenomenon.⁷ HLH secondary to vaccination is rare but reported in adults following influenza vaccination.^{8,9} Following literature review, one case report of HLH post-COVID-19 vaccination was identified in a patient following an inactivated SARS-CoV-2 vaccination.¹⁰ Similar to our case, symptoms developed rapidly following vaccination, however, unlike our case they improved with dexamethasone alone and required no further treatment.¹⁰

Conclusion

This case prompts awareness among clinicians of HLH as a potentially serious complication of COVID-19 vaccination. However, with over 4.9 billion doses administered worldwide to date, this remains an extremely rare complication and should not discourage individuals from vaccination. ■

References

- Retamozo S, Brito-Zerón P, Sisó-Almirall A *et al.* Haemophagocytic syndrome and COVID-19. *Clin Rheumatol* 2021;40:1233–44.
- Soy M, Atagündüz P, Atagündüz I, Sucak GT. Hemophagocytic lymphohistiocytosis: a review inspired by the COVID-19 pandemic. *Rheumatol Int* 2021;41:7–18.
- Henter JI, Horne A, Aricó M *et al.* HLH-2004: Diagnostic and therapeutic guidelines for hemophagocytic lymphohistiocytosis. *Pediatr Blood Cancer* 2007;48:124–31.
- Fardet L, Galicier L, Lambotte O *et al.* Development and validation of the HScore, a score for the diagnosis of reactive hemophagocytic syndrome. *Arthritis Rheumatol* 2014;66:2613–20.
- La Rosée P, Horne A, Hines M *et al.* Recommendations for the management of hemophagocytic lymphohistiocytosis in adults. *Blood* 2019;133:2465–77.
- Medicines and Healthcare products Regulatory Agency. *Coronavirus Yellow Card reporting site*. MHRA. <https://coronavirus-yellowcard.mhra.gov.uk>
- Medicines and Healthcare products Regulatory Agency. *Summary of Product Characteristics for Vaxzevria*. MHRA, 2021. www.gov.uk/government/publications/regulatory-approval-of-covid-19-vaccine-astazeneca/information-for-healthcare-professionals-on-covid-19-vaccine-astazeneca
- Ikebe T, Takata H, Sasaki H *et al.* Hemophagocytic lymphohistiocytosis following influenza vaccination in a patient with aplastic anemia undergoing allogeneic bone marrow stem cell transplantation. *Int J Hematol* 2017;105:389–91.
- Liederman Z, Behl P. Hemophagocytic lymphohistiocytosis associated with adult vaccination: a case of cytokine flurries. *Canadian Journal of General Internal Medicine* 2015;10:39–42.
- Tang LV, Hu Y. Hemophagocytic lymphohistiocytosis after COVID-19 vaccination. *J Hematol Oncol* 2021;14:87.

**Address for correspondence: Dr Philippa Cory, University Hospitals of Derby and Burton NHS Foundation Trust, Uttoxeter Road, Derby DE22 3NE, UK.
Email: philippa.cory@nhs.net**