



Watch out for neuromyelitis optica spectrum disorder after inactivated virus vaccination for COVID-19

Shuai Chen¹ · Xiao-Rui Fan¹ · Shuang He¹ · Jie-Wen Zhang¹ · Shu-Jian Li¹ 

Received: 9 May 2021 / Accepted: 21 June 2021 / Published online: 29 June 2021
© Fondazione Società Italiana di Neurologia 2021

Abstract

With recent availability of COVID-19 vaccine, post-vaccination neurological complications had been occasionally reported. Here, we reported for the first time a case of neuromyelitis optica spectrum disorder (NMOSD) that developed after the first dose of inactivated virus vaccine for COVID-19. The patient developed mild fever, vomiting, diarrhea, and cough after receiving the first dose of inactivated virus vaccine. Two months later, she experienced dizziness and unsteady walking. MRI scanning of the brain revealed lesions in area postrema and bilateral hypothalamus, typical for NMOSD. Serum antibodies for AQP4, ANA, SSA, SSB, Ro-52, and p-ANCA were positive. The patient was diagnosed as AQP4-positive NMOSD with coexisting systemic autoimmunity. After treatment with methylprednisolone (500 mg for 5 days), symptoms were greatly relieved. As NMOSD is seriously harmful and curative, it is important to be aware of the NMOSD symptoms after vaccination. Cautions should be given for those with preexisting systemic autoimmune abnormalities in vaccination for COVID-19.

Keywords COVID-19 · Vaccine · NMOSD · AQP4 · Autoimmune response

Introduction

COVID-19 can present with a variety of neuroimmune complications including Guillain-Barré syndrome, neuromyelitis optica spectrum disorders (NMOSD), Miller Fisher syndrome, polyneuritis cranialis, myasthenia gravis, and myelitis. SARS-CoV-2 may affect the neurosystem by direct viral invasion and/or overactivation of inflammations and autoimmune responses. There have been three cases of NMOSD that developed during the recovery period of COVID-19 [1–3]. With the recent availability of COVID-19 vaccine, the rarely post-vaccination transverse myelitis and Bell's palsy had raised concerns on vaccine safety [4]. Herein, we reported for the first time a case of NMOSD that developed after receiving first dose of inactivated virus vaccine.

Case report

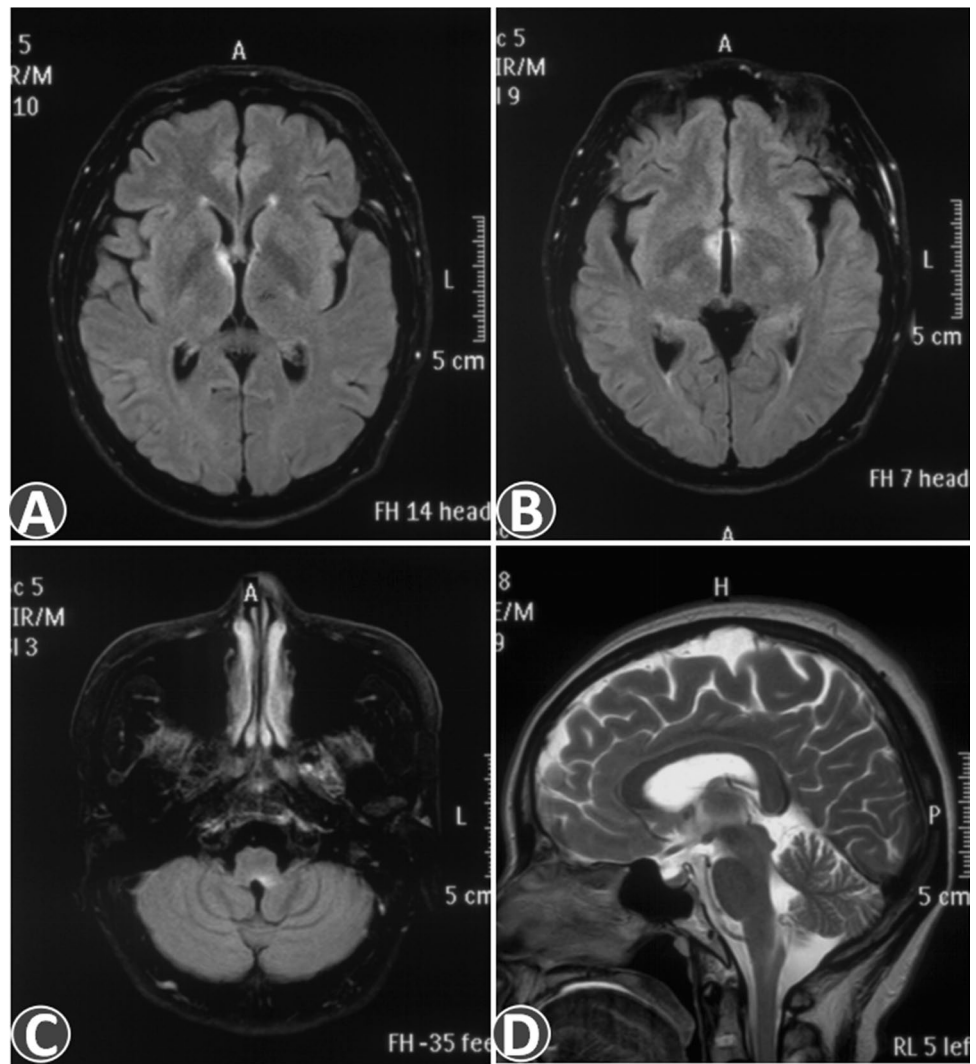
The patient was a previously healthy middle-aged female. Two months ago, on the 3rd day after receiving the first dose of inactivated virus vaccine, she developed mild fever, vomiting, diarrhea, and cough. At that time, CT scan of the chest and abdomen showed no obvious abnormalities. After symptomatic and nutritional support treatment, diarrhea was relieved, but nausea and vomiting persisted. Five days ago, she experienced dizziness and unsteady walking. Nausea and vomiting also worsened. Neurological examination revealed weakened pharyngeal reflex, limb muscle strength of grade 4, and unstable tandem walking. MRI scanning of the brain revealed area postrema and bilateral hypothalamus lesions without Gd enhancement (Fig. 1). Optic nerves and the cervical spinal cord were unremarkable on MRI. Electromyography revealed F-wave abnormalities in bilateral median and posterior tibial nerves. Laboratory tests included blood routine, liver and kidney function, cortisol and thyroid hormones, vitamin B1 and B12 levels, tumor markers, erythrocyte sedimentation rate, antinuclear antibody profiles, C-reactive protein, immunoglobulins and complements, rheumatoid factor, ANCA, antiphospholipid antibodies, anti-AQP4, MOG and GFAP IgG (CBA assay), autoimmune encephalitis antibodies, paraneoplastic antibodies,

✉ Jie-Wen Zhang
zhangjw9900@126.com

✉ Shu-Jian Li
lsjdoctor@126.com

¹ Department of Neurology, Zhengzhou University People's Hospital (Henan Provincial People's Hospital), Zhengzhou 450003, Henan, China

Fig. 1 Brain MRI of the patient. **A–C** showed area postrema and bilateral hypothalamus lesions on fluid-attenuated inversion recovery (FLAIR) sequence. **D** showed area postrema lesion on sagittal T2-weighted sequence



and serum cytokines (IFN- γ , IL-6, IL-4, IL-2, IL-10, IL-21, TNF- α). Abnormal results were leucopenia of $2.36 \times 10^9/L$ and positive antibodies for AQP4, ANA, SSA, SSB, Ro-52, and p-ANCA. Cerebrospinal fluid (CSF) leukocyte count was $31 \times 10^6/L$, all of which were mononuclear cells. CSF glucose and protein were normal, and no oligoclonal bands were found. The patient was diagnosed as AQP4-positive NMOSD with coexisting systemic autoimmunity. After treatment with methylprednisolone (500 mg for 5 days), the patient's symptoms were greatly relieved.

Discussion

Systemic autoantibodies and systemic autoimmune diseases could coexist with NMOSD. Considerable studies have found COVID-19 could provoke some autoimmune antibodies or autoimmune diseases. A study of 29 patients with severe COVID-19 who had no history of autoimmune

diseases found that the prevalence of antinuclear antibody, β 2-GPI, aCL, p-ANCA, and c-ANCA was 34.5%, 34.5%, 24.1%, 6.9%, and 6.9% respectively [5]. In another study, the prevalence of anti-Ro52 and anti-Ro60 antibodies was 20% and 25% in severe COVID-19 patients [6]. In some COVID-19 patients with neurological involvement, anti-caspr2, ganglioside GD1b, MOG, MuSK antibodies were also found. For the current case, autoimmune antibodies had not been tested before vaccination; thus, we could not determine whether she had a systemic autoimmune background in the past. In other words, it is not clear whether the vaccine just induces or directly causes NMOSD. Although multiple autoimmune antibodies were positive, it was not sufficient to diagnose any rheumatic disease at present.

This patient underwent serum cytokine tests twice after vaccination, and no elevations of inflammation markers were seen. Multiple autoimmune positive antibodies indicated that molecular mimicry may not be the major reason for the production of AQP4-IgG. It is possible that in the context

of preexisting systemic immunity, the vaccine overactivated the immune system, exacerbated the production of AQP4-IgG, and eventually provoked NMOSD. As NMOSD is seriously harmful and curative, it is important to be aware of the NMOSD symptoms after vaccination. Cautions should also be given for those with preexisting systemic autoimmune abnormalities in vaccination for COVID-19.

Author contribution SC and SL conceived the idea. XF and SH collected the clinical data. SC contributed to the writing of the manuscript. The revision of the manuscript was done by SL and JZ.

Funding Henan Natural Science Foundation (No:212300410241).

Data availability The data are available via contacting the corresponding author.

Declarations

Ethical approval This study was approved by the local ethics committee. Written informed consent for clinical and imaging data to be used for this report was obtained from the patient.

Conflict of interest The authors declare no competing interests.

References

1. Ghosh R, De K, Roy D et al (2020) A case of area postrema variant of neuromyelitis optica spectrum disorder following SARS-CoV-2 infection. *J Neuroimmunol* 350:577439
2. de Ruijter NS, Kramer G, Gons RAR et al (2020) Neuromyelitis optica spectrum disorder after presumed coronavirus (COVID-19) infection: a case report. *Mult Scler Relat Disord* 46:102474
3. Batum M, KisabayAk A, Mavioglu H (2020) Covid-19 infection-induced neuromyelitis optica: a case report. *Int J Neurosci* 30:1–7
4. Goss AL, Samudralwar RD, Das RR et al (2021) ANA investigates: neurological complications of COVID-19 vaccines. *Ann Neurol*. <https://doi.org/10.1002/ana.26065>
5. Vlachoyiannopoulos G, Magira E, Alexopoulos H et al (2021) Autoantibodies related to systemic autoimmune rheumatic diseases in severely-ill patients with COVID-19. *Ann Rheum Dis* 79(12):1661–1663
6. Zhou Y, Han T, Chen J et al (2020) Clinical and autoimmune characteristics of severe and critical cases of COVID-19. *Clin Transl Sci* 13(6):1077–1086

Publisher's note Springer Nature remains neutral with regard to jurisdictional claims in published maps and institutional affiliations.