

Bell's palsy after inactivated COVID-19 vaccination in a patient with history of recurrent Bell's palsy: A case report

Bin-Yan Yu, Lu-Sha Cen, Ting Chen, Tian-Hong Yang

ORCID number: Bin-Yan Yu 0000-0001-6680-5133; Lu-Sha Cen 0000-0001-7223-340X; Ting Chen 0000-0001-5194-7606; Tian-Hong Yang 0000-0002-1325-2149.

Author contributions: Yu BY and Cen LS reviewed the literature and contributed to manuscript drafting; Chen T interpreted the data; Yang TH analyzed and interpreted the testing findings; all authors approved the final article and assured all the questions regarding the accuracy of the article.

Supported by Zhejiang Provincial Administration of Traditional Chinese Medicine, No. 2020ZT001.

Informed consent statement:

Informed written consent was obtained from the patient for publication of this report and any accompanying images.

Conflict-of-interest statement: The authors declare that they have no conflicting interests.

CARE Checklist (2016) statement:

The authors have read the CARE Checklist (2016), and the manuscript was prepared and revised according to the CARE Checklist (2016).

Open-Access: This article is an open-access article that was selected by an in-house editor and

Bin-Yan Yu, Department of Acupuncture and Moxibustion, The First Affiliated Hospital of Zhejiang Chinese Medical University (Zhejiang Provincial Hospital of Traditional Chinese Medicine), Hangzhou 310006, Zhejiang Province, China

Lu-Sha Cen, Department of Ophthalmology, The First Affiliated Hospital of Zhejiang Chinese Medical University, Hangzhou 310006, Zhejiang Province, China

Ting Chen, Department of Ultrasonography, The First Affiliated Hospital of Zhejiang Chinese Medical University, Hangzhou 310006, Zhejiang Province, China

Tian-Hong Yang, Department of Acupuncture and Moxibustion, The First Affiliated Hospital of Zhejiang Chinese Medical University, Hangzhou 310006, Zhejiang Province, China

Corresponding author: Bin-Yan Yu, MD, Attending Doctor, Department of Acupuncture and Moxibustion, The First Affiliated Hospital of Zhejiang Chinese Medical University (Zhejiang Provincial Hospital of Traditional Chinese Medicine), No. 54 Youdian Road, Hangzhou 310006, Zhejiang Province, China. 20103034@zcmu.edu.cn

Abstract

BACKGROUND

With rapid and extensive administration of inactivated coronavirus disease 2019 (COVID-19) vaccine to the general population in China, it is crucial for clinicians to recognize neurological complications or other side effects associated with COVID-19 vaccination.

CASE SUMMARY

Here we report the first case of Bell's palsy after the first dose of inactivated COVID-19 vaccine in China. The patient was a 36-year-old woman with a past history of Bell's palsy. Two days after receiving the first dose of the Sinovac Life Sciences inactivated COVID-19 vaccine, the patient developed right-side Bell's palsy and binocular keratoconjunctivitis. Prednisone, artificial tears and fluorometholone eye drops were applied. The patient's symptoms began to improve by day 7 and resolved by day 54.

CONCLUSION

As mRNA COVID-19 vaccine trials reported cases of Bell's palsy as adverse events, we should pay attention to the occurrence of Bell's palsy after inactivated COVID-19 vaccination. A history of Bell's palsy, rapid increase of immunoglobulin M and immunoglobulin G-specific antibodies to severe acute respiratory

fully peer-reviewed by external reviewers. It is distributed in accordance with the Creative Commons Attribution NonCommercial (CC BY-NC 4.0) license, which permits others to distribute, remix, adapt, build upon this work non-commercially, and license their derivative works on different terms, provided the original work is properly cited and the use is non-commercial. See: <http://creativecommons.org/licenses/by-nc/4.0/>

Manuscript source: Unsolicited manuscript

Specialty type: Medicine, research and experimental

Country/Territory of origin: China

Peer-review report's scientific quality classification

Grade A (Excellent): 0
Grade B (Very good): B
Grade C (Good): 0
Grade D (Fair): 0
Grade E (Poor): 0

Received: June 13, 2021

Peer-review started: June 13, 2021

First decision: June 25, 2021

Revised: June 28, 2021

Accepted: July 28, 2021

Article in press: July 28, 2021

Published online: September 26, 2021

P-Reviewer: Syahputra DA

S-Editor: Wang LL

L-Editor: Filipodia

P-Editor: Yuan YY



syndrome coronavirus 2 may be risk factors for Bell's palsy after COVID-19 vaccination.

Key Words: Recurrent; Bell's palsy; Keratoconjunctivitis; Inactivated COVID-19 vaccination; Case report

©The Author(s) 2021. Published by Baishideng Publishing Group Inc. All rights reserved.

Core Tip: Bell's palsy has been reported as an adverse event in coronavirus disease 2019 (COVID-19) mRNA vaccine trials, but no cases have been seen following administration of inactivated COVID-19 vaccines. Here we report a case of Bell's palsy in a patient with a history of recurrent Bell's palsy following one dose of inactivated COVID-19 vaccine. Because of a rapid increase of immunoglobulin M- and immunoglobulin G-specific antibodies to severe acute respiratory syndrome coronavirus 2 and keratoconjunctivitis of both eyes after vaccination, we assumed that the humoral immune system was intensively activated, causing local inflammation of the facial nerve and cornea. A history of Bell's palsy and rapid increase of specific antibodies may be risk factors for Bell's palsy after COVID-19 vaccination.

Citation: Yu BY, Cen LS, Chen T, Yang TH. Bell's palsy after inactivated COVID-19 vaccination in a patient with history of recurrent Bell's palsy: A case report. *World J Clin Cases* 2021; 9(27): 8274-8279

URL: <https://www.wjgnet.com/2307-8960/full/v9/i27/8274.htm>

DOI: <https://dx.doi.org/10.12998/wjcc.v9.i27.8274>

INTRODUCTION

The ongoing coronavirus disease 2019 (COVID-19) pandemic has had a huge impact on people's health, daily life, and on the economy worldwide. To control the spread of the epidemic and to meet the coming opening of China, COVID-19 vaccination was initiated for the public from the end of 2020. Currently three types of COVID-19 vaccines have been granted emergency use and marketing authorization by National Medical Products Administration of China. According to the different techniques used for vaccine design, they can be divided into inactivated, live-vectored mRNA, and recombinant COVID-19 vaccines. Of those vaccines, the inactivated vaccine has been the most widely administered in China and is manufactured by two companies, Sinopharm China National Biotec Group and Sinovac Life Sciences. Phase III clinical trials of the inactivated vaccines are underway[1]. Initial efficacy and safety data on the inactivated vaccine have been reported[2,3]. To the best of our knowledge, there is no mention of facial paralysis in the literature describing the efficacy and safety of the inactivated vaccine.

Bell's palsy is an acute, unilateral facial paralysis. In the general population, the incidence ranges from 11.5-53.3 per 100000[4]. The cause of facial palsy is still unclear. It is reported that the incidence of Bell's palsy increased in vaccine trials[5,6]. The correlation between Bell's palsy and vaccination should receive attention. Here we report a case of 36-year-old Chinese woman with a previous history of Bell's palsy, who developed Bell's palsy 2 d after receiving inactivated COVID-19 vaccine.

CASE PRESENTATION

Chief complaints

A 36-year-old woman presented at our outpatient department 2 d after receiving inactivated COVID-19 vaccine, with the chief complaints of eye discomfort and right-side facial weakness.

History of present illness

She received the first dose of Sinovac Life Sciences (Beijing, China) COVID-19 vaccine,

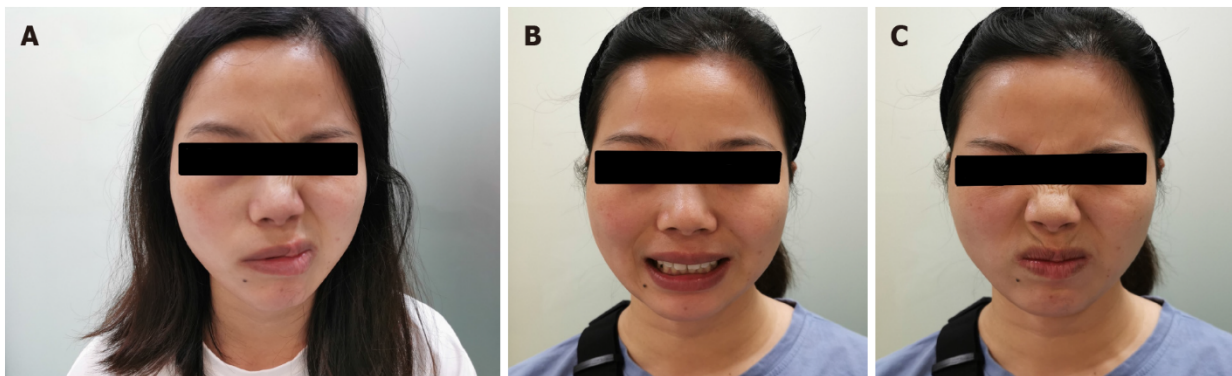


Figure 1 Changes in right-side facial expression muscle function before and after treatment. A: Patient with a right facial droop before treatment; B and C: Patient with normal right-side facial expression muscle function after treatment.

which contains 3 µg/0.5 mL of inactivated severe acute respiratory syndrome coronavirus 2 (SARS-CoV-2) virus (equivalent to 600 SU per dose) at 5 pm April 15, 2021 in Hangzhou, Zhejiang Province, China. Following injection in the right upper arm, she felt mild soreness, but no localized erythema and swelling were seen at the injection site. The next morning, she complained of eye discomfort, with dryness and foreign-body sensation, especially in her right eye. Two days later, she found that the right side of her face drooped, the forehead wrinkle had disappeared, and her eyelid did not close completely. Her body temperature was 36.7 °C. There was no inducing factor such as fatigue, influenza, or cold stimulation. She had no symptoms of respiratory tract infection and no symptoms of the Melkersson-Rosenthal syndrome triad.

History of past illness

The patient suffered from left-side Bell's palsy in 2003. She recovered after 1 mon of treatment with prednisone and acupuncture. She denied any other nervous disease or other chronic diseases.

Personal and family history

The patient had no particular individual or family history.

Physical examination

Her body weight was 52 kg. She was oriented and coherent. Cranial nerve (CN) examination was significant for House-Brackmann (H-B) grade III isolated right CN 7 palsy (Figure 1). Her motor, sensory, and cerebellar examinations were normal.

Laboratory examinations

Blood immunoglobulin M (IgM) and immunoglobulin G (IgG)-specific antibodies to SARS-CoV-2 whole-virion were positive. In addition, there were no positive findings in routine, blood biochemistry, serum immunoglobulin A, IgM, and IgG.

Imaging examinations

There was no positive finding in a computed tomography scan of the brain.

FINAL DIAGNOSIS

She was diagnosed with Bell's palsy and keratoconjunctivitis.

TREATMENT

Prednisone (40 mg/d) was administered for 1 wk. Artificial tears and fluorometholone eye drops (Santen, Osaka, Japan) were prescribed four times daily. Acupuncture therapy was applied three times weekly beginning of April 24, 2021 (Figure 2).

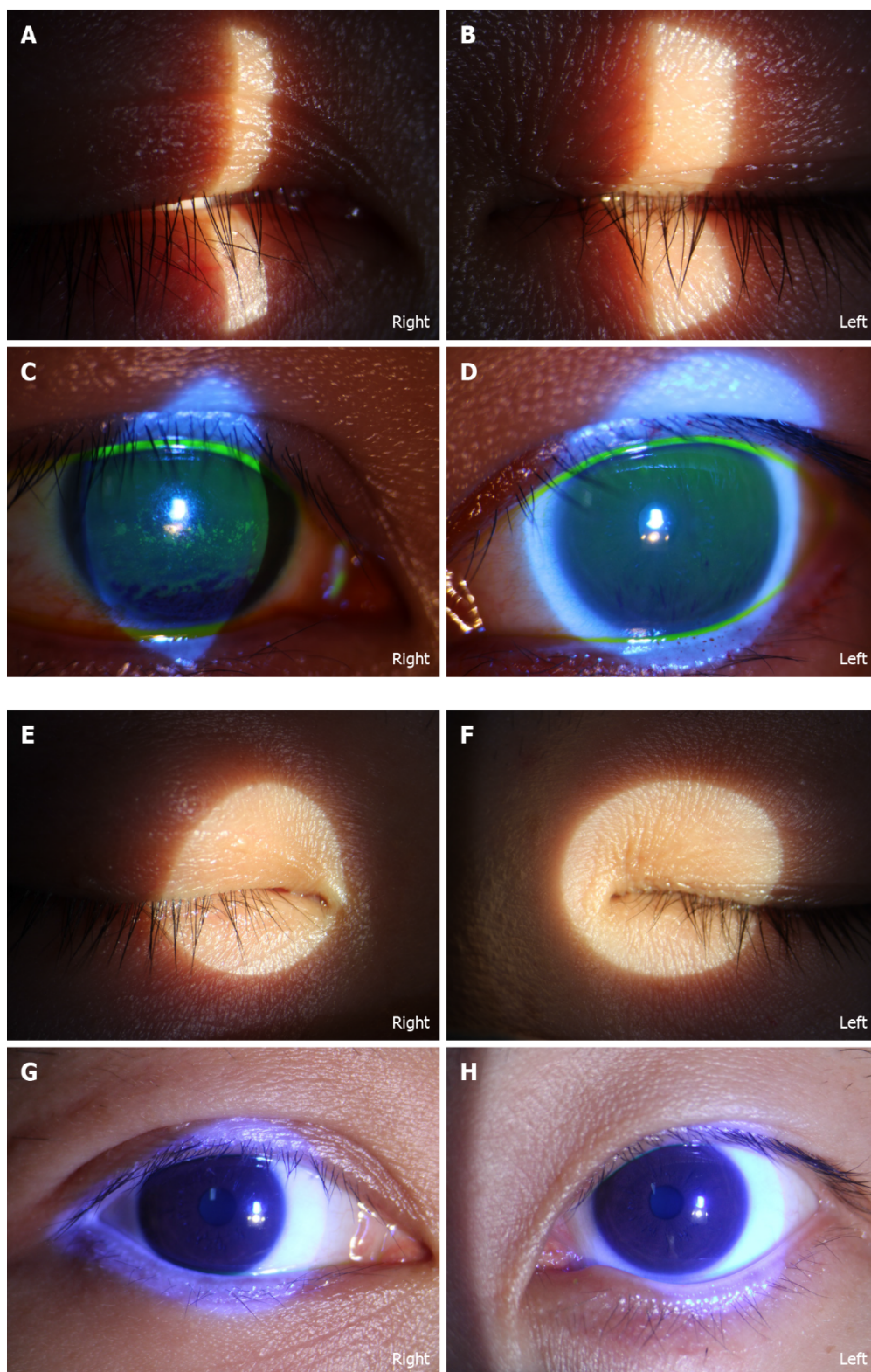


Figure 2 Ophthalmologic changes of both eyes before and after treatment. A and B: Slit lamp inspection shows that the right eyelid could not completely close and that the left one could close normally; C and D: Conjunctival and scleral vessels are slightly congested. The central corneal epithelium of both eyes was punctate with opacity; E and F: Slit lamp inspection shows that both eyelids could close normally; G and H: Conjunctival and scleral vessels were not congested. Central corneal epithelium of both eyes had recovered.

OUTCOME AND FOLLOW-UP

The patient's symptoms began to improve by day 14, and by July 10, 2021, the patient's facial expression and eye symptoms were significantly improved. The H-B grade decreased to grade I.

DISCUSSION

This is the first case of Bell's palsy in a patient with a previous history of Bell's palsy following one dose of inactivated COVID-19 vaccine. Bell's palsy has been reported after administration of a COVID-19 mRNA vaccine[7,8] and patients with a history of Bell's palsy had a three and a half to seven times higher morbidity than the general population[5]. The incidence of Bell's palsy may also be increased following injection of other inactivated vaccines including quadrivalent meningococcal conjugate[5], H1N1, and other seasonal influenza vaccines[6].

Inactivated vaccines are the classic form used to protect against viral infection by inducing specific T cell and neutralizing antibody responses[5]. A clinical trial of inactivated COVID-19 vaccine indicated that the immune responses were induced after two doses of vaccine[3]. However, IgM- and IgG-specific antibodies to the SARS-CoV-2 whole virion tested positive after first dose of vaccine in our case. Keratoconjunctivitis is a typical manifestation of COVID-19 infection[9]. The patient's left eye could close completely, but keratoconjunctivitis was present. We assumed that her humoral immune system was intensively activated, causing local inflammation of the facial nerve and cornea. Repajic *et al*[8] also reported a case of Bell's palsy after mRNA COVID-19 vaccination in a patient with a history of Bell's palsy. The association between Bell's palsy history and COVID-19 vaccination could be of importance, and pathophysiological evidence needs further investigation.

CONCLUSION

Based on the analysis of this case and other COVID-19 related cases, we consider that patients with a history of Bell's palsy may be at risk of recurrence after COVID-19 vaccination by mRNA or inactivated vaccines and physicians need to be vigilant about that. The absence of cerebrospinal fluid examination may be a limitation for this case as it is necessary to make it clear whether there was any infection in the cerebrospinal fluid. The rapid increase of IgM and IgG-specific antibodies to SARS-CoV-2 after vaccination may be a related observable factor.

REFERENCES

- 1 **Palacios R**, Patiño EG, de Oliveira Pirelli R, Conde MTRP, Batista AP, Zeng G, Xin Q, Kallas EG, Flores J, Ockenhouse CF, Gast C. Double-Blind, Randomized, Placebo-Controlled Phase III Clinical Trial to Evaluate the Efficacy and Safety of treating Healthcare Professionals with the Adsorbed COVID-19 (Inactivated) Vaccine Manufactured by Sinovac - PROFISCOV: A structured summary of a study protocol for a randomised controlled trial. *Trials* 2020; **21**: 853 [PMID: 33059771 DOI: 10.1186/s13063-020-04775-4]
- 2 **Xia S**, Zhang Y, Wang Y, Wang H, Yang Y, Gao GF, Tan W, Wu G, Xu M, Lou Z, Huang W, Xu W, Huang B, Wang W, Zhang W, Li N, Xie Z, Ding L, You W, Zhao Y, Yang X, Liu Y, Wang Q, Huang L, Xu G, Luo B, Liu P, Guo W. Safety and immunogenicity of an inactivated SARS-CoV-2 vaccine, BBIBP-CorV: a randomised, double-blind, placebo-controlled, phase 1/2 trial. *Lancet Infect Dis* 2021; **21**: 39-51 [PMID: 33069281 DOI: 10.1016/S1473-3099(20)30831-8]
- 3 **Zhang Y**, Zeng G, Pan H, Li C, Hu Y, Chu K, Han W, Chen Z, Tang R, Yin W, Chen X, Liu X, Jiang C, Li J, Yang M, Song Y, Wang X, Gao Q, Zhu F. Safety, tolerability, and immunogenicity of an inactivated SARS-CoV-2 vaccine in healthy adults aged 18-59 years: a randomised, double-blind, placebo-controlled, phase 1/2 clinical trial. *Lancet Infect Dis* 2021; **21**: 181-192 [PMID: 33217362 DOI: 10.1016/S1473-3099(20)30843-4]
- 4 **Zhang W**, Xu L, Luo T, Wu F, Zhao B, Li X. The etiology of Bell's palsy: a review. *J Neurol* 2020; **267**: 1896-1905 [PMID: 30923934 DOI: 10.1007/s00415-019-09282-4]
- 5 **Ozonoff A**, Nanishi E, Levy O. Bell's palsy and SARS-CoV-2 vaccines. *Lancet Infect Dis* 2021; **21**: 450-452 [PMID: 33639103 DOI: 10.1016/S1473-3099(21)00076-1]
- 6 **Lee GM**, Greene SK, Weintraub ES, Baggs J, Kulldorff M, Fireman BH, Baxter R, Jacobsen SJ, Irving S, Daley MF, Yin R, Naleway A, Nordin JD, Li L, McCarthy N, Vellozzi C, Destefano F, Lieu TA; Vaccine Safety Datalink Project. H1N1 and seasonal influenza vaccine safety in the vaccine safety datalink project. *Am J Prev Med* 2011; **41**: 121-128 [PMID: 21767718 DOI: 10.1016/j.amepre.2011.04.004]
- 7 **Colella G**, Orlandi M, Cirillo N. Bell's palsy following COVID-19 vaccination. *J Neurol* 2021 [PMID: 33611630 DOI: 10.1007/s00415-021-10462-4]
- 8 **Repajic M**, Lai XL, Xu P, Liu A. Bell's Palsy after second dose of Pfizer COVID-19 vaccination in a patient with history of recurrent Bell's palsy. *Brain Behav Immun Health* 2021; **13**: 100217 [PMID: 33594349 DOI: 10.1016/j.bbih.2021.100217]

- 9 **Douglas KAA**, Douglas VP, Moschos MM. Ocular Manifestations of COVID-19 (SARS-CoV-2): A Critical Review of Current Literature. *In Vivo* 2020; **34**: 1619-1628 [PMID: [32503820](#) DOI: [10.21873/invivo.11952](#)]



Published by **Baishideng Publishing Group Inc**
7041 Koll Center Parkway, Suite 160, Pleasanton, CA 94566, USA

Telephone: +1-925-3991568

E-mail: bpgoffice@wjgnet.com

Help Desk: <https://www.f6publishing.com/helpdesk>

<https://www.wjgnet.com>

