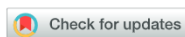

Case Report
Cardiovascular Disorders

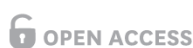

A Case Report for Myopericarditis after BNT162b2 COVID-19 mRNA Vaccination in a Korean Young Male

Dongwon Kim ,^{1†} Jun Hyung Choi ,^{1†} Jun Young Jang ,^{1†} Ouiyeon So ,^{1†} EunJeong Cho ,² Hyunhee Choi ,² Kyung Soon Hong ,² and Kyu Tae Park ,²

¹Division of Cardiology, Department of Internal Medicine, Hallym University College of Medicine, Chuncheon, Korea

²Division of Cardiology, Department of Internal Medicine, Chuncheon Sacred Heart Hospital, Hallym University College of Medicine, Chuncheon, Korea



Received: Aug 20, 2021

Accepted: Sep 27, 2021

Address for Correspondence:

Kyu Tae Park, MD, PhD

Division of Cardiology, Department of Internal Medicine, Chuncheon Sacred Heart Hospital, Hallym University College of Medicine, 77 Sakju-ro, Chuncheon 24253, Republic of Korea.
E-mail: jamems99@gmail.com

[†]Present Position: Senior student, College of Medicine, Hallym University

© 2021 The Korean Academy of Medical Sciences.

This is an Open Access article distributed under the terms of the Creative Commons Attribution Non-Commercial License (<https://creativecommons.org/licenses/by-nc/4.0/>) which permits unrestricted non-commercial use, distribution, and reproduction in any medium, provided the original work is properly cited.

ORCID iDs

Dongwon Kim
<https://orcid.org/0000-0002-8505-9794>

Jun Hyung Choi
<https://orcid.org/0000-0001-7703-3570>

Jun Young Jang
<https://orcid.org/0000-0003-1702-0131>

Ouiyeon So
<https://orcid.org/0000-0002-0978-3924>

EunJeong Cho
<https://orcid.org/0000-0003-3345-2516>

Hyunhee Choi
<https://orcid.org/0000-0001-5278-1855>


ABSTRACT

Mass vaccination with the Pfizer-BioNTech coronavirus disease 2019 (COVID-19) vaccine (BNT162b2) in Korea has resulted in many reported adverse effects. These side effects are the object of much scrutiny in the medical community. We report the case of a 29-year-old male who was diagnosed with myopericarditis after his second dose of Pfizer-BioNTech COVID-19 vaccine. This patient is the second recognized case of Pfizer-BioNTech COVID-19 vaccine induced myopericarditis in Korea and the first to have recovered from it. He originally presented with chest discomfort and exertional chest pain. Lab tests revealed elevated cardiac marker levels and echocardiographic findings displayed minimal pericardial effusion, prompting diagnosis as myopericarditis. We decided on two weeks of outpatient treatment with non-steroidal anti-inflammatory drugs (NSAIDs) due to the patient's mild symptoms and his occupation in the military. When this proved insufficient, we shifted to combination therapy with low dose corticosteroids and NSAIDs. After two weeks of treatment, the patient's symptoms and pericardial effusion had improved, and he was recovered completely 37 days after the onset.

Keywords: COVID-19; Pfizer-BioNTech Vaccine; Adverse Effects; Male; Myopericarditis

INTRODUCTION

Myopericarditis is an inflammatory syndrome in both the myocardium or pericardium that can have both infectious and noninfectious causes.^{1,2} Vaccination can also be one of these causes by inducing an immune inflammatory response in the myocardium or pericardium. There has been a recognized association with myopericarditis and the smallpox vaccine.³ Similarly, there may also be a plausible causal relationship between the Pfizer-BioNTech coronavirus disease 2019 (COVID-19) vaccine and post-vaccination myopericarditis.⁴ Here, we present the case of a Korean young male with myopericarditis following Pfizer-BioNTech COVID-19 mRNA (messenger ribonucleic acid) vaccine (BNT162b2). His symptoms and pericardial effusion have improved after 14 days of combination therapy with low dose corticosteroids and non-steroidal anti-inflammatory drugs (NSAIDs).

Kyung Soon Hong 

<https://orcid.org/0000-0002-9118-8912>

Kyu Tae Park 

<https://orcid.org/0000-0002-0822-7694>

Disclosure

The authors have no potential conflicts of interest to disclose.

Author Contributions

Conceptualization: Park KT, Kim DW, Choi JH. Formal analysis: Kim DW, Choi JH. Methodology: Park KT, Cho EJ, Choi HH, Hong KS. Writing - original draft: Kim DW, Choi JH. Writing - review & editing: Kim DW, Choi JH, Jang JY, So OY, Park KT, Cho EJ, Choi HH, Hong KS.

CASE DESCRIPTION

On June 30, 2021, a 29-year-old male serving in the army visited our outpatient clinic with a chief complaint of chest discomfort with exertional chest pain. He had received his second dose of Pfizer-BioNTech COVID-19 vaccine (BNT162b2) on the morning of the previous day. Chest discomfort started 11 hours after vaccination, satisfying the condition of acute onset.

The patient was previously healthy without prior medical history. The initial vital signs showed a blood pressure of 111/67 mmHg and pulse rate of 60 beats per minute. A review of symptoms was negative for nausea, vomiting, headache, dizziness, dyspnea, orthopnea, and palpitation. His height measured 175 cm and weight 75 kg, with a body mass index of 24.5. He has never used tobacco products and there was no family history of cardiovascular disease or sudden cardiac death.

On laboratory evaluation, blood tests showed white blood cell count of 5,040/mm³ (range, 3,600–10,200), neutrophil count of 3,300/mm³ (range, 1,400–7,700), hemoglobin 14.6 g/dL (range, 13.7–17.5) and platelet count of 188,000/mm³ (range, 140,000–380,000). High-sensitivity C-reactive protein (hsCRP) was 1.47 mg/L (range, 0–3). The blood chemistry revealed blood urea nitrogen to be 12.5 mg/dL (range, 9.0–23.0), creatinine 1.0 mg/dL (range, 0.6–1.2), total protein 7.1 g/dL (range, 6.5–8.0), and albumin 4.7 g/dL (range, 4.0–5.3). The analysis of 230,734 US military personnel vaccinated cardiac marker examination showed BNP (B-type natriuretic peptide) level of 2.06 pg/mL (range, 0–100.0), CK-MB (Creatine kinase-MB) level of 0.25 ng/mL (range, 0–5.0), and increased troponin-I level of 107.43 pg/mL (range, 0–53.53). An electrocardiogram revealed normal sinus rhythm, normal axis, 75 beats per minute without ST-T changes in any lead (**Fig. 1**) and his chest radiograph showed mild cardiomegaly (**Fig. 2**).

Transthoracic echocardiogram (TTE) on the following day demonstrated normal left ventricular systolic and diastolic function left ventricular ejection fraction (LVEF) was 61.7% with normal left ventricle (LV) wall thickness. Minimal pericardial effusion was found 3.5 mm lateral to the right ventricle without evidence of tamponade (**Fig. 3**).

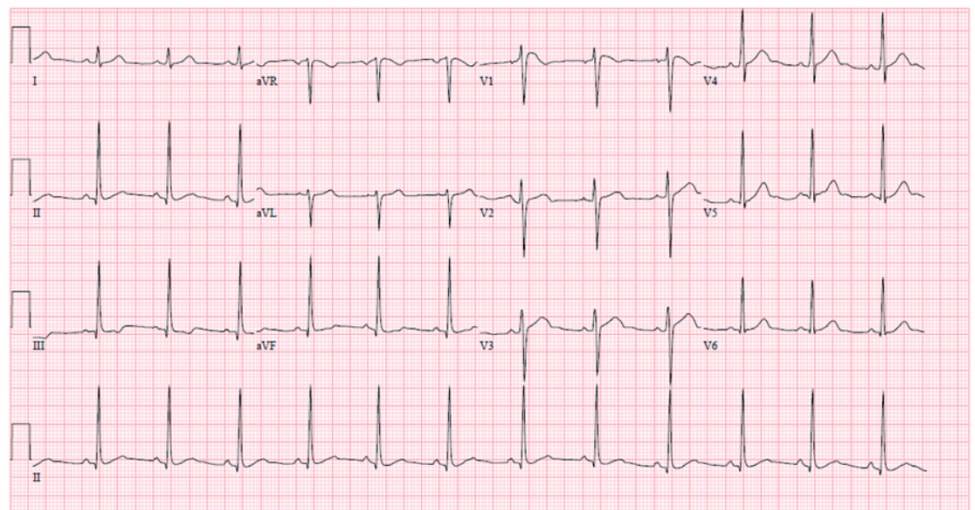


Fig. 1. ECG performed on the day of first visit. The ECG shows normal sinus rhythm, normal axis and 75 beats per minute without ST-T changes in any lead.
ECG = electrocardiogram.

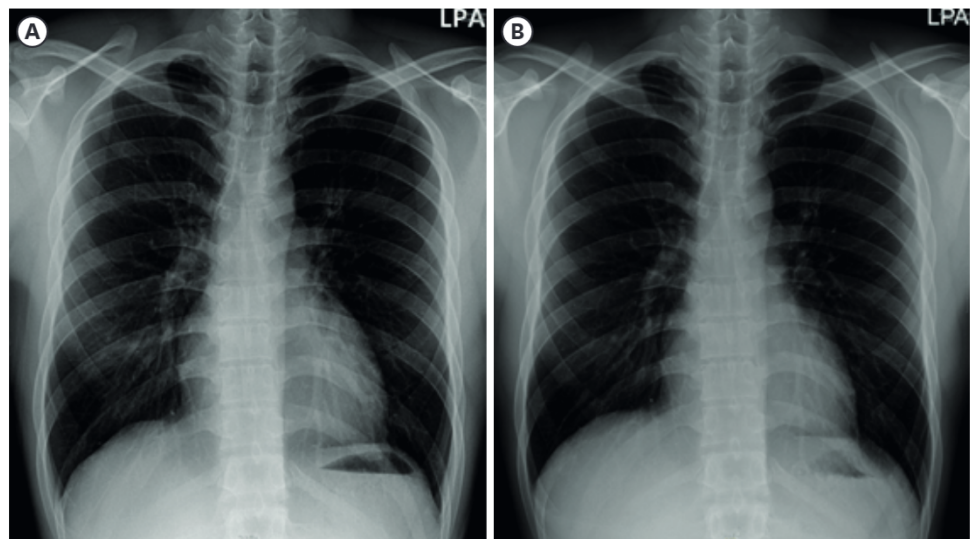


Fig. 2. Chest X-ray performed on the day of first visit and last follow-up. (A) Chest X-ray shows mild cardiomegaly. (B) Chest X-ray shows improving cardiomegaly.

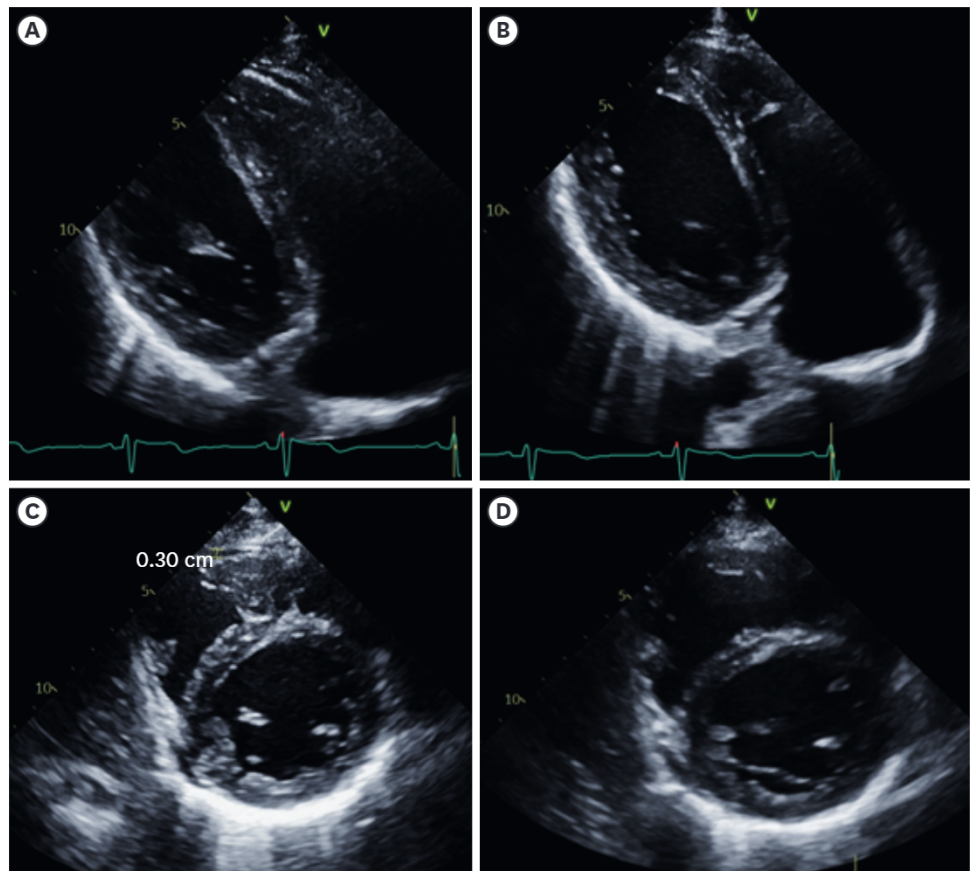


Fig. 3. Echocardiogram performed on first day of visit and last follow-up. RV focusing view at diastolic phase (A, B). (A) Image taken on June 30 shows 3.5 mm of minimal pericardial effusion at RV lateral side. (B) Image taken on August 6 shows improvement. Refer to **Supplementary Videos 1 and 2** to see imaging in relation to cardiac cycle. Parasternal short axis view (mitral valve level) at diastolic phase (C, D). (C) Image taken on June 30 shows 3 mm of minimal pericardial effusion at the RV free wall. (D) Image taken on August 6 shows improvement. RV = right ventricle.

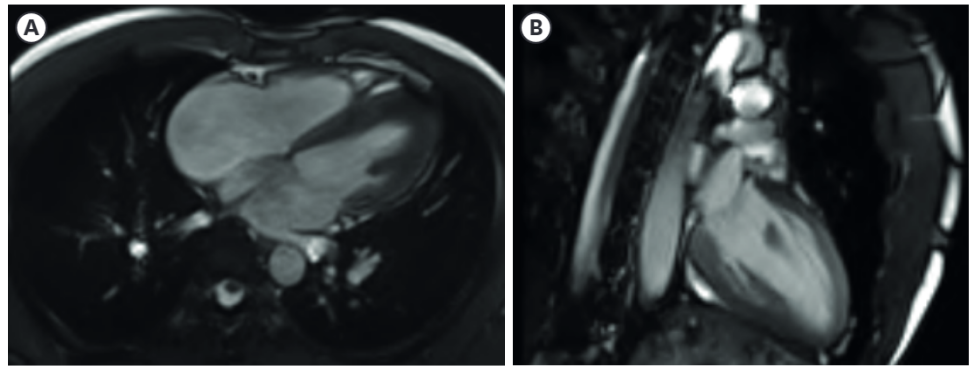


Fig. 4. Cardiac MRI of acute myopericarditis taken on August 6. (A) MRI 4 chamber cine image. (B) MRI 2 chamber left cine image. Scanty pericardial effusion was observed and no abnormalities were found in the myocardium wall. Refer to **Supplementary Videos 3 and 4** for details. MRI = magnetic resonance imaging.

Myopericarditis was suspected due to symptoms of exertional chest pain, pericardial effusion found in echocardiography and elevated troponin-I levels with normal LVEF. We started conservative treatment for myopericarditis, prescribing NSAIDs for 5 days.

Three days after prescription, the patient admitted himself to the emergency room (ER) complaining of spontaneous chest pain. The pain was dull and long lasting with intensity of numerical rating scale 3 to 4. The patient returned the following day for follow-up. TTE revealed the pericardial effusion to have been resolved by 1.5 mm, and the level of troponin-I was lowered to 55.49 pg/mL. He was prescribed NSAIDs for 7 days.

The patient returned to the outpatient department a week later without significant improvement in his symptoms. TTE follow-up showed that the patient's LVEF was normal and pericardial effusion had improved whilst still being visible. Slight increase in troponin-I levels was also found (55.49 pg/mL – > 75.89 pg/mL). His chest radiograph showed improvement in cardiomegaly (**Fig. 2**). Because of the failure of first line conservative therapy for myopericarditis, we prescribed prednisolone 5 mg daily for 14 days and ibuprofen 200 mg twice daily for 14 days.

After two weeks on July 26, TTE follow-up showed that pericardial effusion had improved, showing scanty pericardial effusion. It had improved since the first echocardiography. The patient acknowledged improvement of chest pain and discomfort.

The final follow-up on August 6 revealed normal cardiac marker levels and showed no signs of heart failure. CK-MB level was 0.28 ng/mL (range, 0–5.0), troponin-I level 28.02 pg/mL (range, 0–53.53), and NT-proBNP below 35.00 (range, 0–125). hsCRP level had declined to below 0.16 and no significant changes were observed in white blood cell or neutrophil counts. Only scanty pericardial effusion was found without any specific lesions at myocardium on cardiac magnetic resonance imaging (MRI) (**Fig. 4**). Based on these findings, we determined that he no longer required medication or further follow-up.

DISCUSSION

Pericarditis and myocarditis may coexist in overlapping forms in clinical practice according to common etiologies, either infectious (cardiotropic viruses) or noninfectious (i.e.,

systemic inflammatory disease, vaccine), they share.^{1,2,5} Myopericarditis is a predominantly pericardial syndrome with known or clinically suspected concomitant myocardial involvement, while perimyocarditis is primarily a myocardial syndrome.^{1,6,7} Myopericarditis can be clinically diagnosed in patients who meet the definite criteria for acute pericarditis and show elevation of biomarkers of myocardial injury (Troponin-I or T, CK-MB fraction) without newly developed impairment of left ventricular function in echocardiography.^{7,8}

Management of myocarditis in the absence of significant myocardial failure is similar to what is recommended for acute pericarditis. Empirical anti-inflammatory therapies (i.e. aspirin 1,500–3,000 mg/day) or NSAIDs (ibuprofen 1,200–2,400 mg/day or indomethacin 75–150 mg/day) are commonly prescribed for control of chest pain. In cases of contraindication, intolerance, or failure of aspirin or NSAIDs, corticosteroids can be prescribed as a second choice.^{7,9}

Myopericarditis following vaccination has been reported, mostly associated with smallpox vaccines. The Vaccine Adverse Event Reporting System database had 708 reports of post-vaccination myopericarditis from January 1, 1990 to December 31. Of said reports 79% were males and the total median age was 24 years. The vaccine most frequently reported was smallpox (59%).¹⁰ In an analysis of 230,734 US military personnel vaccinated against smallpox, myopericarditis was reported in 1 out of 12,819 vaccinations.¹¹

There have been several cases of myocarditis and pericarditis in individuals who have received COVID-19 mRNA vaccines.¹²⁻¹⁷ The reported cases have often occurred within days of vaccination, more frequently among younger males and more commonly following the second dose of vaccines. The course of post-vaccination myopericarditis is generally mild and responds well to conservative treatment like NSAIDs. The meeting of the Pharmacovigilance Risk Assessment Committee of the European Medicine Agency on July 5 through 8 2021 has confirmed that there may be a plausible causal relationship between the mRNA COVID-19 vaccines and myocarditis.⁴ According to World Health Organization Global Advisory Committee on Vaccine Safety statement, worldwide cases of myopericarditis following COVID-19 vaccination have typically occurred within days of vaccination. These instances have been more common among younger males and more often following the second dose of COVID-19 mRNA vaccines,⁴ which correlates with the present case.

In this case, the patient was diagnosed with myopericarditis based on his symptoms, echocardiographic findings, and elevated cardiac markers. Since he had no specific medical history other than the inoculation of COVID-19 mRNA vaccines, we suspected post-vaccination myopericarditis and started conservative management with NSAIDs for 12 days. During this time, he admitted himself to the ER due to chest pain, and no clear improvement in his symptoms or cardiac marker levels were observed. Following 2015 European Society of Cardiology Guidelines for the diagnosis and management of pericardial diseases, we started combination therapy with low dose corticosteroids (prednisolone 5 mg/day) and NSAIDs (ibuprofen 400 mg/day) for 14 consecutive days. After 14 days of combination therapy, the patient's symptoms and pericardial effusion in echocardiographic findings were improved. At the final follow-up cardiac marker and hsCRP levels had stabilized and no abnormalities of the myocardium were found on cardiac MRI.

Prior to this, there has only been one other case of myopericarditis after COVID-19 mRNA vaccination in Korea.¹⁸ While a true cause-and-effect relationship between mRNA vaccines and myopericarditis cannot be fully established, chest pain itself is a potential side effect. With mRNA vaccination on the rise, many people will visit outpatient clinics with post

vaccination chest pain. As such, clinicians should familiarize themselves with how to identify myopericarditis when presented with post mRNA vaccination chest pain. Examination of cardiac marker levels and observation of pleural effusion through echocardiography are necessary for clinical diagnosis of myopericarditis.

Post vaccination myopericarditis often shows mild course of disease and can be easily controlled with conservative treatment, such as NSAIDs. However, if the patient's condition does not improve with first line therapy, as in our case, combination therapy with low dose corticosteroids and NSAIDs could be suggested to effectively control their symptoms and pericardial effusion. Therefore, we propose combination therapy with low dose corticosteroids and NSAIDs for post-COVID-19 mRNA vaccination myopericarditis that presents mild symptoms and is not responsive to conservative treatment.

This report describes the second case of a Korean patient officially recognized with myopericarditis after his second dose of Pfizer-BioNTech COVID-19 vaccine. This is also the first patient in Korea to have managed a full recovery. While there is no established guideline for post mRNA vaccination myopericarditis, the emergence of mRNA vaccines prompts the need for data detailing how to manage such predicaments. Observing cardiac marker levels and echocardiographic images is essential in initial diagnosis. If conservative therapy with only NSAIDs proves insufficient, we recommend combination therapy with low dose corticosteroids. With this information, it is our hope that this case report serves to aid others in future post mRNA vaccine myopericarditis.

Ethics statement

This research was reviewed and approved by the Institutional Review Board of Hallym University Chuncheon Sacred Heart Hospital (IRB No. 2021-10-001). Informed consent was also submitted by the subject.

SUPPLEMENTARY MATERIALS

Supplementary Video 1

Echocardiogram RV focusing view on first visit

[Click here to view](#)

Supplementary Video 2

Echocardiogram RV focusing view on last follow-up

[Click here to view](#)

Supplementary Video 3

Cardiac MRI 4 chamber cine video

[Click here to view](#)

Supplementary Video 4

Cardiac MRI 2 chamber left cine video

[Click here to view](#)

REFERENCES

1. Spodick DH. *The pericardium: a comprehensive textbook*. New York, NY, USA: Marcel Dekker, Inc.; 1996.
2. Zipes DP, Libby P, Bonow RO, Mann DL, Tomaselli GF, Braunwald E. *Braunwald's Heart Disease: a Textbook of Cardiovascular Medicine*. Philadelphia, PA, USA: Elsevier/Saunders; 2019.
3. Cassimatis DC, Atwood JE, Engler RM, Linz PE, Grabenstein JD, Vernalis MN. Smallpox vaccination and myopericarditis: a clinical review. *J Am Coll Cardiol* 2004;43(9):1503-10.
[PUBMED](#) | [CROSSREF](#)
4. COVID-19 Subcommittee of the WHO Global Advisory Committee on Vaccine Safety (GACVS). Updated guidance regarding myocarditis and pericarditis reported with COVID-19 mRNA vaccines. <https://www.who.int/news/item/09-07-2021-gacvs-guidance-myocarditis-pericarditis-covid-19-mrna-vaccines>. Updated 2021. Accessed July 28, 2021.
5. Imazio M, Trinchero R. Myopericarditis: Etiology, management, and prognosis. *Int J Cardiol* 2008;127(1):17-26.
[PUBMED](#) | [CROSSREF](#)
6. Maisch B, Seferović PM, Ristić AD, Erbel R, Rienmüller R, Adler Y, et al. Guidelines on the diagnosis and management of pericardial diseases executive summary; The Task force on the diagnosis and management of pericardial diseases of the European society of cardiology. *Eur Heart J* 2004;25(7):587-610.
[PUBMED](#) | [CROSSREF](#)
7. Adler Y, Charron P, Imazio M, Badano L, Barón-Esquivias G, Bogaert J, et al. 2015 ESC Guidelines for the diagnosis and management of pericardial diseases. *Eur Heart J* 2015;36(42):2921-64.
[PUBMED](#) | [CROSSREF](#)
8. Imazio M, Brucato A, Barbieri A, Ferroni F, Maestroni S, Ligabue G, et al. Good prognosis for pericarditis with and without myocardial involvement: results from a multicenter, prospective cohort study. *Circulation* 2013;128(1):42-9.
[PUBMED](#) | [CROSSREF](#)
9. Imazio M, Cooper LT. Management of myopericarditis. *Expert Rev Cardiovasc Ther* 2013;11(2):193-201.
[PUBMED](#) | [CROSSREF](#)
10. Su JR, McNeil MM, Welsh KJ, Marquez PL, Ng C, Yan M, et al. Myopericarditis after vaccination, vaccine adverse event reporting system (VAERS), 1990–2018. *Vaccine* 2021;39(5):839-45.
[PUBMED](#) | [CROSSREF](#)
11. Halsell JS, Riddle JR, Atwood JE, Gardner P, Shope R, Poland GA, et al. Myopericarditis following smallpox vaccination among vaccinia-naïve US military personnel. *JAMA* 2003;289(24):3283-9.
[PUBMED](#) | [CROSSREF](#)
12. Singh B, Kaur P, Cedeno L, Brahimi T, Patel P, Virk H, et al. COVID-19 mRNA vaccine and myocarditis. *Eur J Case Rep Intern Med* 2021;8(7):002681.
[PUBMED](#)
13. Watkins K, Griffin G, Septaric K, Simon EL. Myocarditis after BNT162b2 vaccination in a healthy male. *Am J Emerg Med*. Forthcoming 2021. DOI: 10.1016/j.ajem.2021.06.051.
[PUBMED](#) | [CROSSREF](#)
14. Vidula MK, Ambrose M, Glassberg H, Chokshi N, Chen T, Ferrari VA, et al. Myocarditis and other cardiovascular complications of the mRNA-based COVID-19 Vaccines. *Cureus* 2021;13(6):e15576.
[PUBMED](#)
15. Mansour J, Short RG, Bhalla S, Woodard PK, Verma A, Robinson X, et al. Acute myocarditis after a second dose of the mRNA COVID-19 vaccine: a report of two cases. *Clin Imaging* 2021;78:247-9.
[PUBMED](#) | [CROSSREF](#)
16. Kim HW, Jenista ER, Wendell DC, Azevedo CF, Campbell MJ, Darty SN, et al. Patients with acute myocarditis following mRNA COVID-19 vaccination. *JAMA Cardiol*. Forthcoming 2021. DOI: 10.1001/jamacardio.2021.2828.
[PUBMED](#) | [CROSSREF](#)
17. King WW, Petersen MR, Matar RM, Budweg JB, Cuervo Pardo L, Petersen JW. Myocarditis following mRNA vaccination against SARS-CoV-2, a case series. *Am Heart J Plus* 2021;8:100042.
[PUBMED](#) | [CROSSREF](#)
18. Korea Disease Control and Prevention Agency. *KDCA 2021.07.26 Regular Briefing Press Release*. <https://www.korea.kr/news/pressReleaseView.do?newsId=156463392#sitemap-layer>. Updated 2021. Accessed October 8, 2021.