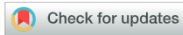

Case Report
Infectious Diseases,
Microbiology & Parasitology



Myocarditis-induced Sudden Death after BNT162b2 mRNA COVID-19 Vaccination in Korea: Case Report Focusing on Histopathological Findings

Sangjoon Choi ,¹ SangHan Lee ,¹ Jeong-Wook Seo ,² Min-ju Kim ,² Yo Han Jeon ,¹ Ji Hyun Park ,¹ Jong Kyu Lee ,¹ and Nam Seok Yeo ¹

¹Department of Forensic Medicine, Defense Institute of Forensic Science, Criminal Investigation Command, Ministry of National Defense, Seoul, Korea

²Department of Pathology, Incheon Sejong Hospital, Incheon, Korea



Received: Aug 24, 2021

Accepted: Oct 1, 2021

Address for Correspondence:

SangHan Lee, MD

Department of Forensic Medicine, Defense Institute of Forensic Science, Criminal Investigation Command, Ministry of National Defense, 22 Itaewon-ro, Yongsan-gu, Seoul 04383, Korea.

E-mail: sanghan111@gmail.com

© 2021 The Korean Academy of Medical Sciences.

This is an Open Access article distributed under the terms of the Creative Commons Attribution Non-Commercial License (<https://creativecommons.org/licenses/by-nc/4.0/>) which permits unrestricted non-commercial use, distribution, and reproduction in any medium, provided the original work is properly cited.

ORCID iDs

Sangjoon Choi

<https://orcid.org/0000-0003-2108-0575>

SangHan Lee

<https://orcid.org/0000-0003-0390-3494>

Jeong-Wook Seo

<https://orcid.org/0000-0003-0242-1805>

Min-ju Kim

<https://orcid.org/0000-0003-3850-9892>

Yo Han Jeon

<https://orcid.org/0000-0002-0353-7255>

Ji Hyun Park

<https://orcid.org/0000-0002-1534-0070>

Jong Kyu Lee

<https://orcid.org/0000-0002-0492-4417>

ABSTRACT

We present autopsy findings of a 22-year-old man who developed chest pain 5 days after the first dose of the BNT162b2 mRNA vaccine and died 7 hours later. Histological examination of the heart revealed isolated atrial myocarditis, with neutrophil and histiocyte predominance. Immunohistochemical C4d staining revealed scattered single-cell necrosis of myocytes which was not accompanied by inflammatory infiltrates. Extensive contraction band necrosis was observed in the atria and ventricles. There was no evidence of microthrombosis or infection in the heart and other organs. The primary cause of death was determined to be myocarditis, causally-associated with the BNT162b2 vaccine.

Keywords: Sudden Cardiac Death; Myocarditis; Coronavirus Disease 19; Vaccination; mRNA Vaccines; Adverse Event Following Immunization

INTRODUCTION

The coronavirus disease 2019 (COVID-19) pandemic, which started in January 2020 has affected people worldwide. Rapid vaccine development has enabled COVID-19 prevention. Two mRNA COVID-19 vaccines, BNT162b2 (Pfizer-BioNTech) and mRNA-1273 (Moderna) demonstrated safety and efficacy in clinical trials, and were granted emergency use authorization by the US Food and Drug Administration in December 2020.^{1,2} As the number of people vaccinated against COVID-19 has increased, there have been multiple reports of myocarditis as an adverse event following immunization,³⁻¹² which was not observed in clinical trials.

Myocarditis is histologically characterized by diffuse and/or focal inflammatory infiltrates within myocardial tissue, accompanied by myocyte damage without evidence of ischemia.¹³ Little is known about the histopathological characteristics of myocarditis following COVID-19 vaccination because endomyocardial biopsy is not a routine procedure for myocarditis and, due to its generally favorable prognosis,⁸ opportunities for autopsy studies are rare.¹⁰

Nam Seok Yeo 
<https://orcid.org/0000-0001-7254-6414>

Disclosure

The authors have no potential conflicts of interest to disclose.

Author Contributions

Conceptualization: Lee S. Data curation: Choi S, Jeon YH, Park JH, Lee JK, Yeo N, Kim MJ. Investigation: Choi S, Jeon YH, Park JH, Lee JK, Yeo N, Kim MJ. Visualization: Choi S, Seo JW. Writing – original draft: Choi S. Writing – review & editing: Choi S, Lee S, Seo JW. Supervision: Lee S, Seo JW

We recently observed a case of sudden cardiac death in a young male six days after receiving the first dose of the BNT162b2 mRNA vaccine and report the distinctive clinical and pathological findings of this case.

CASE DESCRIPTION

The deceased was 22-year-old male military recruit. His blood pressure was elevated on physical examination 17 and 7 months before his death (156/94 mmHg and 128/74 mmHg, respectively), but he was otherwise healthy. On June 13, 2021, 5 days after the first dose of BNT162b2 mRNA vaccination, he complained to a colleague of chest pain at 1:00 AM, during a smoke break, and went to bed. At 8:00 AM, he was found unconscious hunched beside the bed. He was taken to an emergency department and was found to have ventricular fibrillation on electrocardiography. Cardiopulmonary resuscitation was performed for two hours, but he could not be resuscitated.

An autopsy was performed 24 hours after his death. The deceased was well-nourished with no visible injuries on external examination. The heart weighed 470 g and had multiple petechiae on its surface. The pericardium was smooth with no fibrin deposition or exudate. The coronary arteries were patent, and the heart valves were unremarkable. The myocardium was of normal thickness and there was no dilation of the atria or ventricles. The myocardium was homogeneously brown with no obvious necrosis or fibrosis. On microscopic examination, diffuse inflammatory infiltration, with neutrophil and histiocyte predominance, was observed within the myocardium (Fig. 1A). Notably, the inflammatory infiltrates were dominant in the atria (Fig. 1A and B), and around the sinoatrial (SA) and atrioventricular (AV) nodes (Fig. 1C),

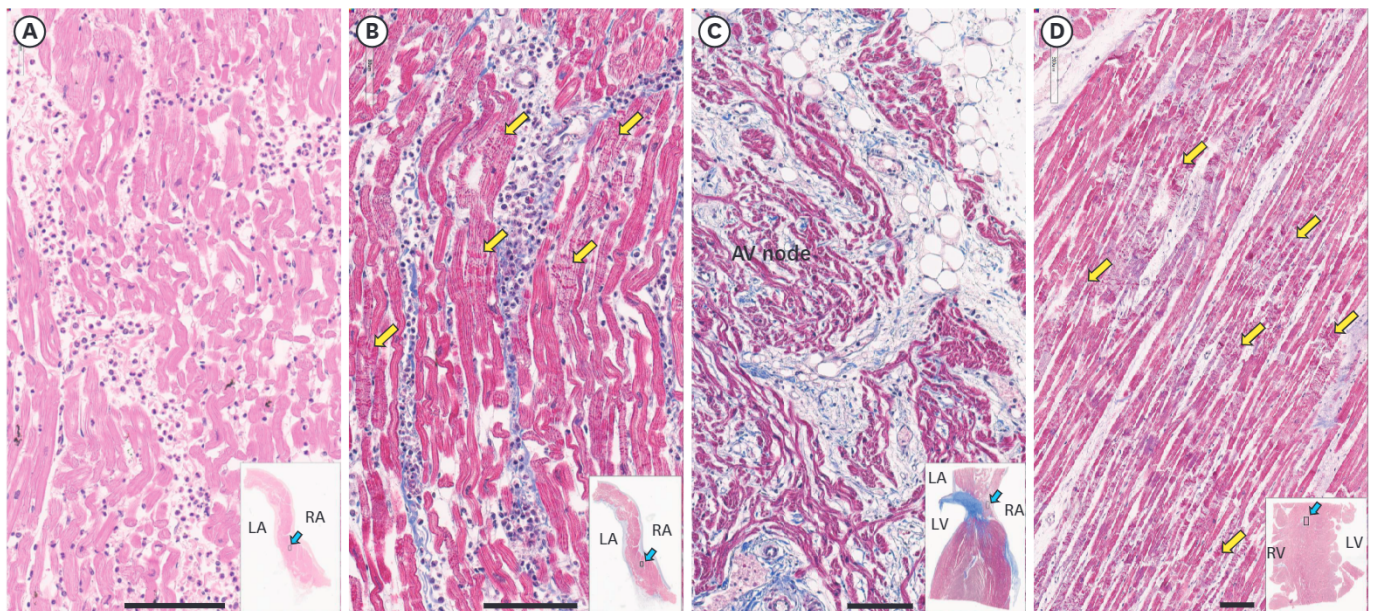


Fig. 1. Histopathology of the heart. (A) Hematoxylin and eosin stains of atrial septum shows massive inflammatory infiltration with neutrophil predominance. (B) The myocytes often show contraction band necrosis (yellow arrows), which were highlighted by Masson's trichrome staining. (C) The atrioventricular node area shows extension of atrial myocarditis to the superficial layer of the node. (D) The ventricular myocardium is free of inflammatory infiltrates, but there are multiple large foci of contraction band necrosis (yellow arrows) particularly in the left ventricular wall and the ventricular septum. Bars represent 100 μ m. The blue arrows in insets show where the section was taken from the low magnification views. Hematoxylin and eosin stain was used for the specimen shown in (A) and Masson's trichrome stain was used for the specimen shown in (B-D). RA = right atrium, LA = left atrium, RV = right ventricle, LV = left ventricle.

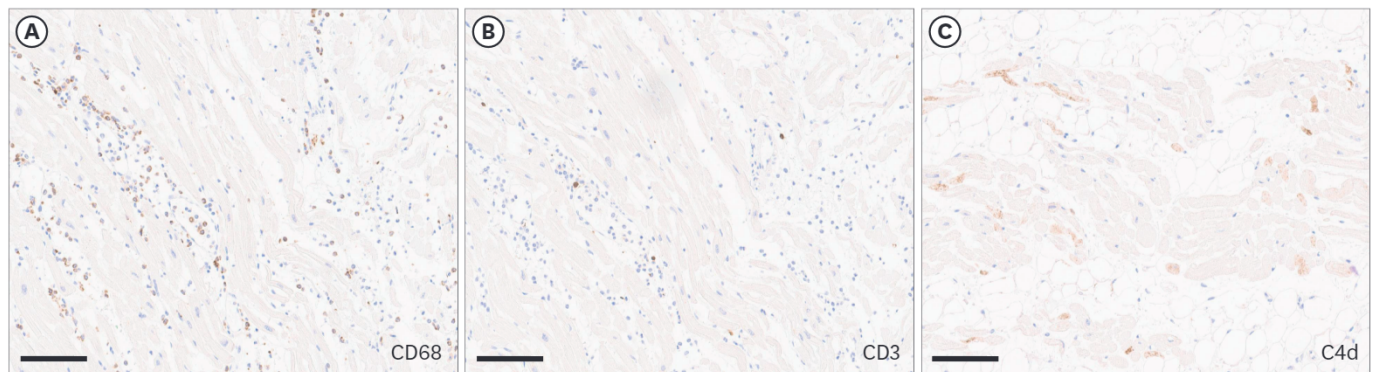


Fig. 2. Immunohistochemistry of the heart. **(A)** Immunohistochemical staining for CD68 shows that most of the inflammatory cells are histiocytes. **(B)** Most of the inflammatory cells are negative for CD3 staining, indicating a paucity of lymphocytes. **(C)** Positive staining for C4d shows scattered single-cell necrosis of atrial myocytes. Bars represent 100 μ m.

whereas ventricular area displayed minimal or no inflammatory cells (**Fig. 1D**). Occasional myocyte necrosis or degeneration was found adjacent to the inflammatory infiltrates, without abscess formation or bacterial colonization. There was also scattered single-cell necrosis of myocytes without accompanying inflammation. Multiple scattered foci of contraction band necrosis (CBN) was identified throughout the myocardium, predominantly in the left ventricle. No other specific pathological changes were found in the lung, liver, kidney, spleen, pancreas, or brain on macroscopic or microscopic examination.

Masson's trichrome staining highlighted dense eosinophilic intracellular strips of myocytes, consistent with CBN (**Fig. 1B and D**). CD68 and CD3 immunostaining showed a moderate number of histiocytes and sparse lymphocytes in the inflammatory infiltrates (**Fig. 2A and B**). Degenerated or ischemic myocytes exhibited positive C4d immunoreactivity (**Fig. 2C**).

The cause of death was determined to be myocarditis. Given that the myocarditis showed a temporal relationship to vaccine administration and there was no other explanation for the sudden cardiac death, on July 26, 2021, Korea Centers for Disease Control and Prevention acknowledged that myocarditis and vaccination were “possibly related” in this case.

Ethics statement

Informed consent for publication of clinical data was obtained from the deceased's family.

DISCUSSION

There were three main histological findings in the heart: 1) myocarditis predominantly involving the atrial wall, with neutrophil and histiocyte predominance; 2) non-inflammatory single-cell necrosis; and 3) diffuse CBN throughout the myocardium, predominantly in the left ventricle. These pathological findings were not evident on macroscopic examination. The only abnormal gross finding was cardiac enlargement, which may have been secondary to hypertension.

In this case, the myocarditis was histologically different from viral or immune-mediated myocarditis in that the inflammatory infiltrates were predominantly neutrophils and histiocytes, rather than lymphocytes. Multinucleated giant cells were not observed. The area of myocarditis was confined to the atrial wall, but the ventricles were free of cellular

infiltration. Inflammatory cells were also present in the SA and AV nodes. Myocyte necrosis or degeneration was observed adjacent to the inflammatory infiltrates. Neutrophil infiltration of the myocardium is an uncommon histological type of myocarditis, and is generally observed in immunocompromised patients with bacterial infection.¹⁴ The deceased was previously healthy and there were no signs of infective myocarditis. Dissemination of infective endocarditis and pneumonia were also excluded. The underlying mechanism of myocardial injury in this case is unclear, but it may have involved cytokine-mediated or histiocyte-linked immunologic injury to the myocardium. Isolated atrial myocarditis is very rare and thus is an unfamiliar disease entity to pathologists. To our knowledge, only two case reports of sudden cardiac death caused by isolated atrial myocarditis have been published previously.^{15,16} Previous reports noted that atrial myocarditis may be overlooked on postmortem examination because sampling of atrium is not routinely performed. In the present case, extensive myocardial sampling enabled accurate diagnosis. A total of 35 sections were examined (25 sections of ventricular and atrial myocardium and 10 sections of the conduction system) and 9 sections had evidence of myocarditis. Myocarditis is usually not apparent on gross examination. Even if the heart is grossly unremarkable, pathologists should examine a sufficient number (≥ 10) of atrial and ventricular sections in order not to overlook or misdiagnose the cause of death, especially if the deceased had myocarditis symptoms and a recent mRNA vaccination history.

Notably, single-cell necrosis (or single-cell ischemia) of myocytes without inflammation was observed in multiple sites throughout the atria. Several autopsy studies of the cardiovascular pathological findings of individuals who died of COVID-19 have also found single-cell necrosis, and this might be a distinctive pathological characteristic of COVID-19.¹⁷⁻¹⁹ Thus, myocardial injury due to COVID-19 vaccination may histologically present not only as myocarditis, but also as scattered single-cell necrosis, similar to myocardial lesions of COVID-19.

Another major histological finding was abundant CBN throughout the myocardium, especially in the left ventricle. CBN is usually observed after irreversible myocyte injury and is associated with ischemic heart disease or a catecholamine excess state.²⁰ The CBN in this case was extensive throughout the ventricular myocardium and we are cautious about drawing a conclusion about the causality. The association between the CBN and COVID-19 vaccination is unclear. The CBN may have occurred as a result of ventricular fibrillation or catecholamine administration during resuscitation. There was no evidence of coronary atherosclerosis or microthrombosis, which could explain the presence of CBN.

We were able to find only one previously published case report of a death due to myocarditis after COVID-19 vaccination with a comprehensive clinicopathological analysis. Verma et al.¹⁰ reported the case of a 42-year-old man, who presented with chest pain and dyspnea 2 weeks after the second dose of mRNA-1273 vaccination, and died 3 days after symptom onset. On microscopic examination, myocyte damage with a mixed inflammatory infiltrate of macrophages, lymphocytes, and eosinophils was observed in the myocardium of both ventricles, whereas the atria showed no evidence of myocarditis. In contrast, our case patient developed symptoms 5 days after the first dose of the BNT162b2 mRNA vaccine and died 7 hours later, and showed isolated atrial myocarditis with neutrophil and histiocyte predominance. The histopathological features described in Verma et al.'s report¹⁰ did not include CBN or single-cell necrosis of myocytes. This suggests that myocarditis after COVID-19 mRNA vaccination is heterogenous, both clinically and histologically.

Table 1. Demographic and clinical features of previously reported myocarditis following coronavirus disease 2019 vaccination

No.	Reference	No. of patients	Sex, M:F	Age, yr median (range)	Sx (No. of patients)	Histopathologic confirmation	Outcome (No. of patients)	Vaccine dose (No. of patients)	Type of vaccine (No. of patients)	Days from vaccination to Sx onset, median (range) ^a
1	Montgomery et al. ⁸	23	23:0	25 (20–51)	Chest pain (23/23)	Not done	Resolved (23/23)	1st (3/23) 2nd (20/23)	BNT162b2-mRNA (7/23) mRNA-1273 (16/23)	50 (12–96) ^a
2	Larson et al. ⁵	8	8:0	28.5 (21–56)	Chest pain (8/8) Fever (5/8)	Endomyocardial biopsy ^b	Resolved (8/8)	1st (1/8) 2nd (7/8)	BNT162b2-mRNA (5/8) mRNA-1273 (3/8)	3 (2–4)
3	Marshall et al. ⁷	7	7:0	17 (14–19)	Fever (5/7) Chest pain (7/7) Fatigue (3/7)	Not done	Resolved (7/7)	2nd (7/7)	BNT162b2-mRNA (7/7)	2 (2–4)
4	Rosner et al. ⁹	7	7:0	24 (19–39)	Chest pain (7/7) Fever (2/7)	Endomyocardial biopsy ^b	Resolved (7/7)	1st (2/7) 2nd (5/7)	BNT162b2-mRNA (5/7) mRNA-1273 (1/7) Ad26.CoV.S (1/7)	3 (2–7)
5	Snapiri et al. ¹¹	7	7:0	16.8 (16.2–17.6)	Chest pain (7/7) Fever (1/7)	Not done	Resolved (7/7)	1st (1/7) 2nd (6/7)	BNT162b2-mRNA (7/7)	2 (1–3)
6	Kim et al. ⁴	4	3:1	30 (23–70)	Chest pain (4/4) Fatigue (3/4) Fever (3/4)	Not done	Resolved (4/4)	2nd (4/4)	BNT162b2-mRNA (2/4) mRNA-1273 (2/4)	2.5 (1–5)
7	Mansour et al. ⁶	2	1:1	23 (21–25)	Chest pain (2/2) Fever (1/2)	Not done	Resolved (2/2)	2nd (2/2)	mRNA-1273 (2/2)	1.5 (1–2)
8	Verma et al. ¹⁰	2	1:1	43.5 (42–45)	Chest pain (2/2)	Endomyocardial biopsy Autopsy	Resolved (1/2) Died (1/2)	2nd (2/2)	BNT162b2-mRNA (1/2) mRNA-1273 (1/2)	12 (10–14)
9	Ammirati et al. ³	1	1:0	56	Chest pain	Not done	Resolved	2nd	BNT162b2-mRNA	3
10	Kim et al. ¹²	1	1:0	24	Chest pain	Not done	Resolved	2nd	BNT162b2-mRNA	1
11	Present study	1	1:0	22	Chest pain Fatigue	Autopsy	Died	1st	BNT162b2-mRNA	5

Sx = symptom, M = male, F = female.

^aThe authors reported time to symptom onset as hours with mean (range); ^bOne patient underwent endomyocardial biopsy in each study, but myocardial inflammation was not found.

The demographic and clinical characteristics of myocarditis after mRNA vaccination in previous reports are summarized in **Table 1**. Vaccine-associated myocarditis has been reported predominantly in young males after the second vaccination. Myocarditis was mainly diagnosed clinically based on elevated serum troponin and cardiac magnetic resonance imaging, and all patients except ours and the patient reported by Verma et al.¹⁰ recovered after receiving supportive care. The patient in this case showed similar clinical features, which supports a potential association between vaccination and myocarditis. However, given that other reported myocarditis cases were generally mild and the symptoms usually developed after the second vaccination, the clinical course of our case (sudden death 6 days after the first vaccination) is an extremely rare event. Considering the short time interval between the onset of the deceased patient's symptoms and his sudden death, the immediate cause of death was possibly an arrhythmia, rather than heart failure.

This is the first case in South Korea that the Korea Centers for Disease Control and Prevention acknowledged the causality of COVID-19 vaccination and myocarditis. This unique case provides an example of a serious adverse event following COVID-19 mRNA vaccination. It is unknown whether this case is related to the vaccine type or to a specific vaccine component. It is also unclear whether the location (atrium), type of inflammation (neutrophils and histiocytes), CBN, and single-cell necrosis without inflammation are specific characteristics of COVID-19 vaccine-associated myocarditis. Comprehensive clinical and pathological evaluation of additional cases is needed to clarify the relationship between COVID-19 vaccination and myocarditis.

REFERENCES

1. Oliver SE, Gargano JW, Marin M, Wallace M, Curran KG, Chamberland M, et al. The advisory committee on immunization practices' interim recommendation for use of Pfizer-BioNTech COVID-19 vaccine - United States, December 2020. *MMWR Morb Mortal Wkly Rep* 2020;69(50):1922-4.
[PUBMED](#) | [CROSSREF](#)
2. Oliver SE, Gargano JW, Marin M, Wallace M, Curran KG, Chamberland M, et al. The advisory committee on immunization practices' interim recommendation for use of Moderna COVID-19 vaccine - United States, December 2020. *MMWR Morb Mortal Wkly Rep* 2021;69(5152):1653-6.
[PUBMED](#) | [CROSSREF](#)
3. Ammirati E, Cavalotti C, Milazzo A, Pedrotti P, Soriano F, Schroeder JW, et al. Temporal relation between second dose BNT162b2 mRNA Covid-19 vaccine and cardiac involvement in a patient with previous SARS-COV-2 infection. *Int J Cardiol Heart Vasc*. Forthcoming 2021. DOI: 10.1016/j.ijcha.2021.100778.
[PUBMED](#) | [CROSSREF](#)
4. Kim HW, Jenista ER, Wendell DC, Azevedo CF, Campbell MJ, Darty SN, et al. Patients with acute myocarditis following mRNA COVID-19 vaccination. *JAMA Cardiol*. Forthcoming 2021. DOI: 10.1001/jamacardio.2021.2828.
[PUBMED](#) | [CROSSREF](#)
5. Larson KF, Ammirati E, Adler ED, Cooper LT Jr, Hong KN, Saponara G, et al. Myocarditis after BNT162b2 and mRNA-1273 vaccination. *Circulation* 2021;144(6):506-8.
[PUBMED](#) | [CROSSREF](#)
6. Mansour J, Short RG, Bhalla S, Woodard PK, Verma A, Robinson X, et al. Acute myocarditis after a second dose of the mRNA COVID-19 vaccine: a report of two cases. *Clin Imaging* 2021;78:247-9.
[PUBMED](#) | [CROSSREF](#)
7. Marshall M, Ferguson ID, Lewis P, Jaggi P, Gagliardo C, Collins JS, et al. Symptomatic acute myocarditis in seven adolescents following Pfizer-BioNTech COVID-19 vaccination. *Pediatrics* 2021;148(3):e2021052478.
[CROSSREF](#)
8. Montgomery J, Ryan M, Engler R, Hoffman D, McClenathan B, Collins L, et al. Myocarditis following immunization with mRNA COVID-19 vaccines in members of the US military. *JAMA Cardiol*. Forthcoming 2021. DOI: 10.1001/jamacardio.2021.2833.
[PUBMED](#) | [CROSSREF](#)
9. Rosner CM, Genovese L, Tehrani BN, Atkins M, Bakhshi H, Chaudhri S, et al. Myocarditis temporally associated with COVID-19 vaccination. *Circulation* 2021;144(6):502-5.
[PUBMED](#) | [CROSSREF](#)
10. Verma AK, Lavine KJ, Lin CY. Myocarditis after Covid-19 mRNA vaccination *N Engl J Med* 2021;385(14):1332-4.
[PUBMED](#) | [CROSSREF](#)
11. Snapiri O, Rosenberg Danziger C, Shirman N, Weissbach A, Lowenthal A, Ayalon I, et al. Transient cardiac injury in adolescents receiving the BNT162b2 mRNA COVID-19 vaccine. *Pediatr Infect Dis J* 2021;40(10):e360-3.
[PUBMED](#) | [CROSSREF](#)
12. Kim IC, Kim H, Lee HJ, Kim JY, Kim JY. Cardiac imaging of acute myocarditis following COVID-19 mRNA vaccination. *J Korean Med Sci* 2021;36(2):e229.
[PUBMED](#) | [CROSSREF](#)
13. Aretz HT, Billingham ME, Edwards WD, Factor SM, Fallon JT, Fenoglio JJ Jr, et al. Myocarditis. A histopathologic definition and classification. *Am J Cardiovasc Pathol* 1987;1(1):3-14.
[PUBMED](#)
14. Leone O, Pieroni M, Rapezzi C, Olivetto I. The spectrum of myocarditis: from pathology to the clinics. *Virchows Arch* 2019;475(3):279-301.
[PUBMED](#) | [CROSSREF](#)
15. Tse R, Garland J, Kesha K, Triggs Y, Modahl L, Milne D, et al. A rare case of isolated atrial myocarditis causing death with no post mortem computed tomography scan correlation. *Am J Forensic Med Pathol* 2018;39(2):123-5.
[PUBMED](#) | [CROSSREF](#)
16. Duffy M, O'Connor K, Milne D, Ondruschka B, Tse R, Garland J. Isolated atrial neutrophilic myocarditis: a rare cause of death and potential "Blind Spot" for postmortem computed tomography and postmortem examination. *Am J Forensic Med Pathol*. Forthcoming 2021. DOI: 10.1097/PAF.0000000000000684.
[CROSSREF](#)

17. Halushka MK, Vander Heide RS. Myocarditis is rare in COVID-19 autopsies: cardiovascular findings across 277 postmortem examinations. *Cardiovasc Pathol* 2021;50:107300.
[PUBMED](#) | [CROSSREF](#)
18. Jum'ah H, Loeffler A, Tomashefski JF Jr. Histopathological findings in the hearts of COVID-19 autopsies: a letter to cardiovascular pathology journal editor in response to Halushka et al. 2020. *Cardiovasc Pathol* 2021;52:107333.
[PUBMED](#) | [CROSSREF](#)
19. Fox SE, Akmatbekov A, Harbert JL, Li G, Quincy Brown J, Vander Heide RS. Pulmonary and cardiac pathology in African American patients with COVID-19: an autopsy series from New Orleans. *Lancet Respir Med* 2020;8(7):681-6.
[PUBMED](#) | [CROSSREF](#)
20. Baroldi G, Mittleman RE, Parolini M, Silver MD, Fineschi V. Myocardial contraction bands. Definition, quantification and significance in forensic pathology. *Int J Legal Med* 2001;115(3):142-51.
[PUBMED](#) | [CROSSREF](#)