

[ CASE REPORT ]

## Myocarditis Following a COVID-19 Messenger RNA Vaccination: A Japanese Case Series

Yoshiki Murakami<sup>1</sup>, Masaya Shinohara<sup>2</sup>, Yosuke Oka<sup>2</sup>, Ryo Wada<sup>2</sup>, Ryota Noike<sup>1</sup>, Hiroshi Ohara<sup>2</sup>, Tadashi Fujino<sup>1</sup> and Takanori Ikeda<sup>1</sup>

### Abstract:

COVID-19 vaccine-related myocarditis has been reported worldwide. We herein report two Japanese cases with suspected vaccine-related myocarditis. A 27-year-old man was admitted with chest pain 4 days after the second vaccination. An electrocardiogram (ECG) did not reveal any significant abnormalities. The second patient, a 37-year-old man, was admitted with chest pain 9 days after the first vaccination. His ECG exhibited ST-elevation in multiple leads. In both cases, cardiac magnetic resonance imaging findings were consistent with myocarditis. They recovered with symptomatic relief within a few days. These cases suggest that the benefit of COVID-19 vaccination exceeds the risk of vaccine-related myocarditis.

**Key words:** coronavirus, myocarditis, COVID-19 vaccination

(Intern Med 61: 501-505, 2022)

(DOI: 10.2169/internalmedicine.8731-21)

### Introduction

Messenger RNA (mRNA) vaccines against COVID-19 infections have been effective in curbing symptomatic cases worldwide. Since the emergency use authorization, a variety of vaccine-related adverse events and especially myocarditis and pericarditis have been described, particularly in adolescents and young adults (1, 2). Although the incidence of myocarditis following an anti-viral vaccination is unclear, anti-viral vaccine-associated myocarditis has been known to be a rare adverse event after smallpox, influenza, and hepatitis B vaccinations (3). A safety surveillance in the United States demonstrated that myocarditis and pericarditis following COVID-19 mRNA vaccinations occurred in very rare cases (4). On July 21, 2021, the Japanese Circulation Society released a statement that the benefits of COVID-19 vaccination in preventing COVID-19 infections exceed the risk of vaccine-related myocarditis and pericarditis. However, little information is available regarding the clinical features of myocarditis following COVID-19 vaccination in the Japanese population. Vaccination rates are still low in Japan, with one reason for this low rate being that many people are

concerned about the safety of the vaccine.

This case series describes two Japanese patients who developed myocarditis shortly after receiving their first or second vaccination.

### Case Reports

#### Case 1

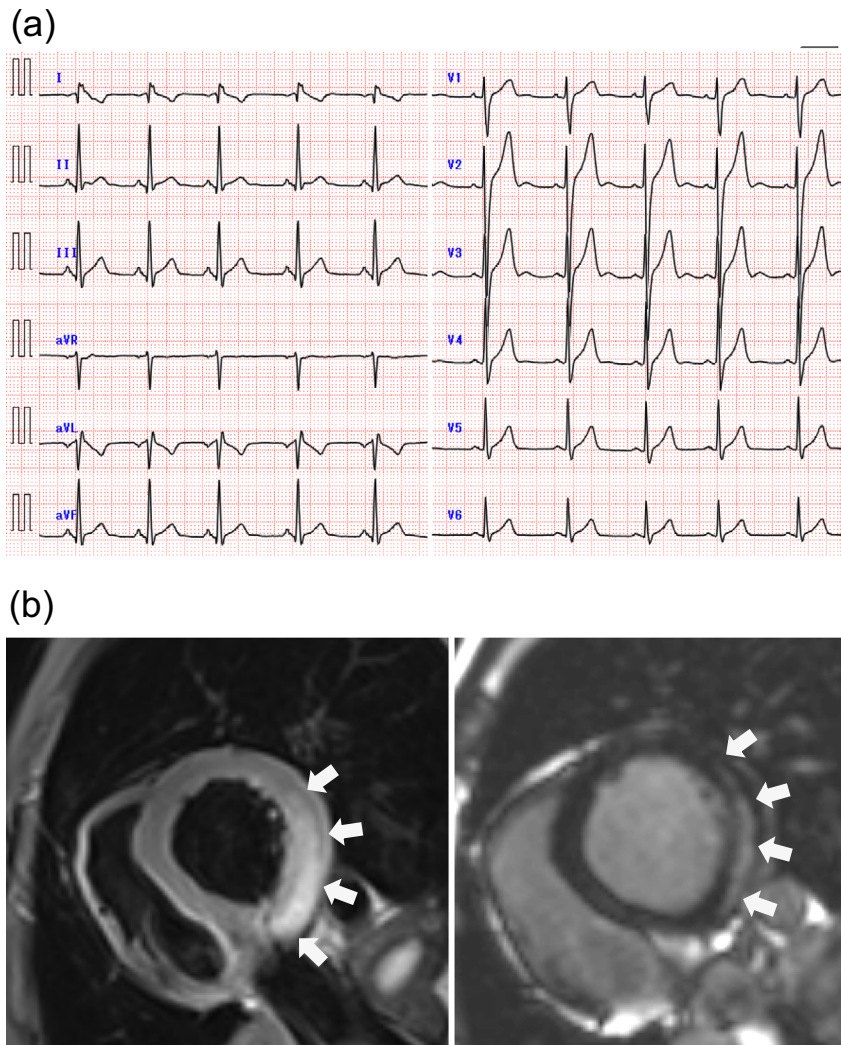
A previously healthy 27-year-old man presented to the emergency department with chest pain. He had initially experienced generalized chest pain three days after the second dose of the COVID-19 BNT162b2 mRNA vaccine (Pfizer-BioNTech). Within a couple of hours, the chest pain vanished. Four days after the vaccination, he developed chest pain again, which continued to worsen, and he was transferred to our hospital.

At the initial presentation, his blood pressure (BP) was 130/78 mmHg, heart rate (HR) 77 beats/min, respiration rate (RR) 16 breaths/min, and oxygen saturation (SpO<sub>2</sub>) 99% on room air. He had a fever of 37.8 °C. On a physical examination, no cardiac murmurs or friction rubs were noted on auscultation. The patient's initial electrocardiography (ECG)

<sup>1</sup>Department of Cardiovascular Medicine, Toho University Graduate School of Medicine, Japan and <sup>2</sup>Division of Cardiovascular Medicine, Department of Internal Medicine, Toho University Faculty of Medicine, Japan

Received: September 26, 2021; Accepted: October 12, 2021; Advance Publication by J-STAGE: November 27, 2021

Correspondence to Dr. Masaya Shinohara, masaya.shinohara@med.toho-u.ac.jp



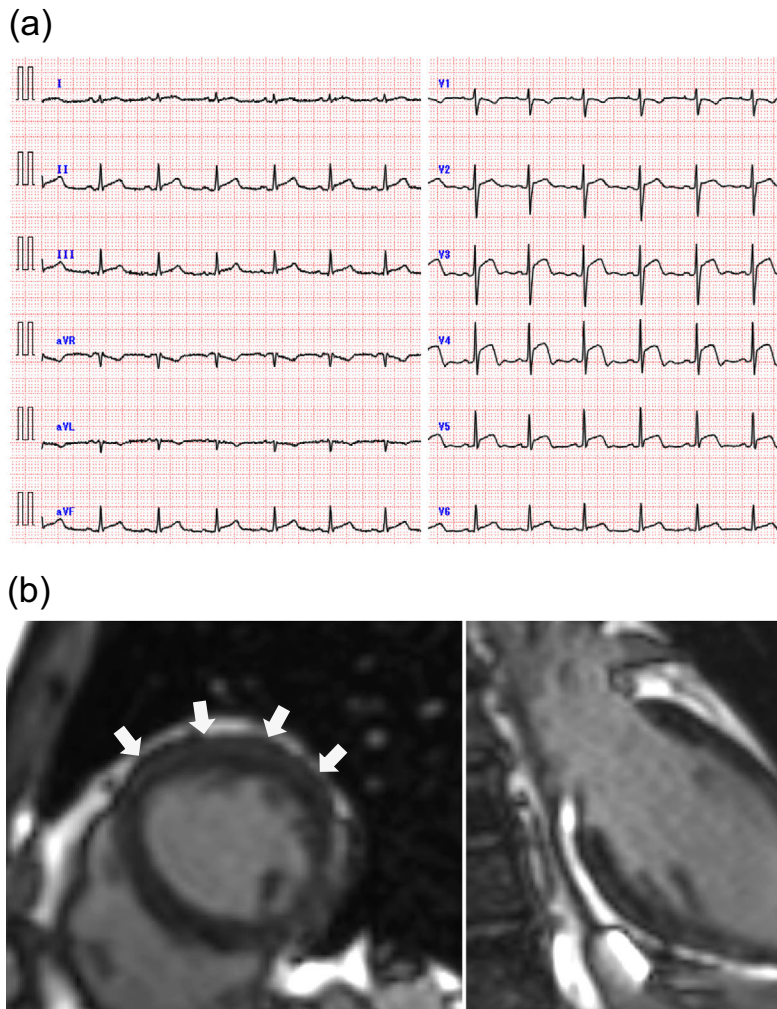
**Figure 1.** Electrocardiogram (ECG) and cardiac magnetic resonance imaging (CMRI) findings corresponding to Case 1. (a) The initial ECG on arrival showed no significant abnormalities. (b) CMRI T2-weighted short-axis view showed a high signal intensity in the infero-lateral segments at the left ventricular mid-basal level (white arrow in the left panel). Late gadolinium enhancement imaging showed subepicardial enhancement (white arrow on right panel) in the same areas as the T2 elevations.

findings showed no abnormalities, despite his continued chest pain (Fig. 1a). A laboratory examination revealed a high-sensitive troponin I level of 11.5 ng/mL (normal range: <0.09 ng/mL), B-type natriuretic peptide level of 27.4 pg/mL (normal range: <18.4 pg/mL), and C-reactive protein (CRP) level of 1.3 mg/dL (normal range: <0.2 mg/dL).

A transthoracic echocardiogram (TTE) revealed a left ventricular ejection fraction (LVEF) of 55% and left ventricular (LV) septal wall thickness of 9 mm without pericardial effusion. Computed tomographic angiography of the coronary arterial system demonstrated normal coronary arteries. Cardiac magnetic resonance imaging (CMRI) performed after admission showed a normal LVEF and the presence of a sub-epicardial late gadolinium enhancement (LGE) in the inferolateral segments at the LV mid-basal level, as well as a high signal intensity, which suggested myocardial edema on T2-weighted images (Fig. 1b).

A severe acute respiratory syndrome coronavirus 2 (SARS-CoV-2) rapid antigen test was negative. Antibodies against the parvovirus B19, Epstein-Barr (EB) virus, adenovirus, and herpes simplex virus 1 and 2 were all negative. He was thus admitted to our hospital with a diagnosis of myocarditis.

He was started on colchicine 0.5 mg twice per day and then transitioned to ibuprofen 200 mg three times per day. His symptoms improved completely within a few days. The peak troponin I level was 11.5 ng/mL on admission. Inverted T-waves on an ECG were recorded in the inferior limb leads on day 3. He was discharged on day 9 after an uneventful hospital stay. The ECG and laboratory abnormal findings had returned to normal or baseline values at the one-month follow-up.



**Figure 2.** Electrocardiogram (ECG) and cardiac magnetic resonance imaging (CMRI) findings corresponding to Case 2. (a) The initial ECG on arrival showed ST elevation in leads V2-V6 and inferior limb leads. (b) CMRI late gadolinium enhancement (LGE) short-axis view showed the presence of a sub-epicardial lesion in the antero-lateral segments at the left ventricular mid-apical level (white arrow in the left panel). CMRI LGE long-axis view showed the same finding (white arrows in the right panel).

## Case 2

A 38-year-old man presented to the emergency department with sudden chest pain 9 days after the first dose of the COVID-19 BNT162b2 mRNA vaccine (Pfizer-BioNTech).

On arrival at the hospital his body temperature was 37.6 °C, BP 146/101 mmHg, HR 117 beats/min, RR 16 breaths/min, and SpO<sub>2</sub> 99% on room air. ECG on arrival revealed ST elevation in leads V2-V6 and the inferior limb leads (Fig. 2a). A TTE revealed regional mild wall hypokinesis in the LV apex and an LV septal wall thickness of 9 mm without pericardial effusion. Laboratory tests revealed an elevated high-sensitive troponin I level of 8.6 ng/mL, BNP level of 67.2 pg/mL, and CRP level of 1.3 mg/dL. Emergent coronary angiography did not show any significant stenoses of the coronary arteries. A SARS-CoV-2 polymerase chain reaction test was negative. The virus antibodies were negative for EB virus, cytomegalovirus, adenovirus, and echovi-

rus.

His chest pain improved by day 3 with oral colchicine 0.5 mg twice per day and ibuprofen 200 mg three times per day. The peak value of the troponin I level was 8.6 ng/mL on admission, and the finding of ST elevation on the ECG persisted. During the hospital stay, no further episodes of chest pain or arrhythmias were observed on ECG monitoring. He was discharged on day 9. We performed CMRI 15 days after the onset. CMRI with LGE showed a sub-epicardial lesion in the antero-lateral segments at the LV mid-apical level, although T2-weighted imaging did not show a high signal intensity (Fig. 2b). This finding was consistent with myocarditis. The ECG and laboratory abnormal findings showed an improving trend at the two-week follow-up.

## Discussion

Since vaccine-related myocarditis is expected to be rare compared to viral myocarditis, speculating a causal relation-



ship between myocarditis and vaccination is difficult. Vaccine-related myocarditis mainly occurs after smallpox, influenza, hepatitis B, or other vaccinations (3). Most cases of vaccine-related myocarditis occur within 30 days after the vaccination. A majority of these cases recover without life-threatening complications (5, 6). Vaccine-associated autoimmunity can occur following such adverse effects after vaccination; this is a well-known phenomenon attributed to the cross-reactivity between the pathogenic antigens and similar human proteins (7). However, regarding mRNA COVID-19 vaccines, the nucleic acid formulation and accelerated development process imposed by the rapid global pandemic make this phenomenon more complicated. Further studies will be needed to conclusively reveal the mechanism underlying COVID-19 vaccine-related myocarditis.

We encountered two Japanese cases of myocarditis following a COVID-19 BNT162b2 mRNA vaccination. While Koizumi et al. described two Japanese cases of COVID-19 vaccine-related myocarditis after the second dose of a vaccination (8), one of our cases developed COVID-19 vaccine-related myocarditis after the first dose of a vaccination (Case 2), which is a novel point.

Our cases had several points in common. Both occurred in young adult men, and the chief complaint was the acute onset of marked chest pain within 10 days following the first or second dose of the COVID-19 vaccine. They did not have any acute SARS-CoV-2 infection. Even though the LV contraction on a TTE was almost normal, they both had remarkably elevated troponin I levels, and CMRI revealed LGE in the LV wall segments consistent with myocarditis. We speculated a possible causal relationship between myocarditis and vaccination. Both experienced the resolution of their symptoms within a few days and were discharged after an uneventful hospital stay. These findings confirmed that the myocarditis following a COVID-19 vaccination was mild, regardless of the number of times the vaccine had been received. The clinical features were similar to those of multiple series reported worldwide and suggest that the benefits of COVID-19 vaccination outweigh the low risk of vaccine-related myocarditis in the Japanese population.

However, since an Israeli article reported that a few previously healthy people died due to COVID-19 vaccine-related myocarditis (9), medical treatment should be sought for those with suspected myocarditis following COVID-19 vaccination. Both of our cases were treated with colchicine and non-steroidal anti-inflammatory drugs because their chief complaints were chest pain suggestive of inflammatory infiltration of the pericardium. In general, specific treatment, such as immunosuppressive and immunomodulatory therapy, is performed in cases of fulminant myocarditis or myocarditis with moderate-severe inflammation (10). In both of the present cases, we did not use steroids or intravenous immunoglobulin because they had a benign clinical course suggestive of mild inflammation in the myocardium. However, the optimum treatment for COVID-19 vaccine-related myocarditis has not been established and thus warrants further

investigation.

The risks and benefits of receiving a second dose of the COVID-19 vaccine for patients who experience myocarditis following the first dose of COVID-19 vaccine remain unknown. Patients who develop myocarditis following the first dose of the vaccine are recommended to delay their second dose until additional reports become available (11). Of note, given the lack of information available, the patient in Case 2 of the present study elected to forego receiving the second dose of the vaccine altogether. Correctly diagnosing COVID-19 vaccine-related myocarditis in populations with suspected myocarditis is important to avoid any risk when receiving a subsequent booster vaccination. Mild symptoms of myocarditis following a COVID-19 vaccination may lead to concern that physicians may underestimate the risk of development of myocarditis. Even if an endomyocardial biopsy is considered the gold standard, CMRI has been reported to be a useful non-invasive tool for making an early diagnosis of myocarditis, showing the presence of LGE and/or myocardial edema even in patients with a preserved LVEF. Of note, all of the case series of COVID-19 vaccine-related myocarditis worldwide reported that the CMRI findings were abnormal and suggestive of myocarditis, such as with LGE and myocardial edema at the time of the diagnosis (12, 13). Indeed, LGE on CMRI was detected in both our cases, although T2-weighted imaging in Case 2 did not show a high signal intensity due to the delayed performance of the CMRI examination. We need to avoid the under-use of CMRI for diagnosing myocarditis following COVID-19 vaccinations. In non-vaccine-associated myocarditis, the presence of LGE on CMRI in the LV segments is associated with the development of adverse cardiovascular events during follow-up (14).

The long-term outcomes of COVID-19 vaccine-related myocarditis remain unclear. Thus, further research with a longer follow-up duration is needed to elucidate the long-term prognosis of myocarditis following COVID-19 vaccination.

**The authors state that they have no Conflict of Interest (COI).**

## References

- Kim HW, Jenista ER, Wendell DC, et al. Patients with acute myocarditis following mRNA COVID-19 vaccination. *JAMA Cardiol* 6: 1196-1201, 2021.
- Montgomery J, Ryan M, Engler R, et al. Myocarditis following immunization with mRNA COVID-19 vaccines in members of the US military. *JAMA Cardiol* 6: 1202-1206, 2021.
- Su JR, McNeil MM, Welsh KJ, et al. Myopericarditis after vaccination. *Vaccine Adverse Event Reporting System (VAERS)*, 1990-2018. *Vaccine* 39: 839-845, 2021.
- Shay DK, Gee J, Su JR, et al. Safety monitoring of the Janssen (Johnson & Johnson) COVID-19 Vaccine-United States, March-April 2021. *MMWR Morb Mortal Wkly Rep* 70: 680-684, 2021.
- Keinath K, Church T, Nurth B, Hulten E. Myocarditis secondary to smallpox vaccination. *BMJ Case Rep* 2018: bcr2017223523, 2018.

6. Faix DJ, Gordon DM, Perry LN, et al. Prospective safety surveillance study of ACAM2000 smallpox vaccine in deploying military personnel. *Vaccine* **38**: 7323-7330, 2020.
7. Segal Y, Shoenfeld Y. Vaccine-induced autoimmunity: the role of molecular mimicry and immune cross reaction. *Cell Mol Immunol* **15**: 586-594, 2018.
8. Koizumi T, Awaya T, Yoshioka K, et al. Myocarditis after COVID-19 mRNA vaccines. *QJM*. Forthcoming.
9. Lazaros G, Klein AL, Hatziantoniou S, Tsioufis C, Tsakris A, Anastassopoulou C. The novel platform of mRNA COVID-19 Vaccines and myocarditis: clues into the potential underlying mechanism. *Vaccine* **39**: 4925-4927, 2021.
10. Maisch B. Cardio-immunology of myocarditis: focus on immune mechanisms and treatment options. *Front Cardiovasc Med* **6**: 48, 2019.
11. Luk A, Clarke B, Dahdah N, et al. Myocarditis and pericarditis following COVID-19 mRNA vaccination: practical considerations for care providers. *Can J Cardiol*. Forthcoming.
12. Starekova J, Bluemke DA, Bradham WS, Grist TM, Schiebler ML, Reeder SB. Myocarditis associated, with mRNA COVID-19 vaccination. *Radiology* **301**: E409-E411, 2021.
13. Bozkurt B, Kamat I, Hotez PJ. Myocarditis with COVID-19 mRNA vaccines. *Circulation* **144**: 471-484, 2021.
14. Aquaro GD, Perfetti M, Camastra G, et al. Cardiac MR with late gadolinium enhancement in acute myocarditis with preserved systolic function. *J Am Coll Cardiol* **70**: 1977-1987, 2017.

The Internal Medicine is an Open Access journal distributed under the Creative Commons Attribution-NonCommercial-NoDerivatives 4.0 International License. To view the details of this license, please visit (<https://creativecommons.org/licenses/by-nc-nd/4.0/>).

---

© 2022 The Japanese Society of Internal Medicine  
*Intern Med* 61: 501-505, 2022