


REVIEW

Acute myocardial infarction and myocarditis following COVID-19 vaccination

Y.N. Aye^{1,†}, A.S. Mai^{2,†}, A. Zhang¹, O.Z.H. Lim², N. Lin¹, C.H. Ng², M.Y. Chan^{1,2}, J. Yip^{1,2}, P.-H. Loh^{1,2,‡} and N.W.S. Chew ^{1,‡,*}

¹Department of Cardiology, National University Heart Centre, Singapore, Singapore and ²Yong Loo Lin School of Medicine. Singapore 117597

[†]These authors contributed equally as first authors.

[‡]These authors supervised the work equally as senior authors.

*Address correspondence to Dr N.W.S. Chew, Department of Cardiology, National University Heart Centre, National University Health System, Singapore, 5 Lower Kent Ridge Road, Singapore 119074, Singapore. email: nicholas_ws_chew@nuhs.edu.sg

Abstract

Emerging reports raise concerns on the potential association between the COVID-19 vaccines and cardiac manifestations. We sought to evaluate cardiac complications associated with COVID-19 vaccination in a pooled analysis from our institution's cohort study and systematic review. Consecutive patients admitted to a tertiary hospital in Singapore between 1 January 2021 and 31 March 2021, with the onset of cardiac manifestations within 14 days following COVID-19 vaccination, were studied. Furthermore, a systematic review was performed, with PubMed, Embase, Research Square, MedRxiv and LitCovid databases accessed from inception up to 29 June 2021. Relevant manuscripts reporting individual patient data on cardiac complications following COVID-19 vaccination were included. Thirty patients were included in the study cohort, with 29 diagnosed with acute myocardial infarction (AMI) and 1 with myocarditis. Five patients developed heart failure, two had cardiogenic shock, three intubated, and one had cardiovascular-related mortality. In the systematic review, 16 studies were included with 41 myocarditis and 6 AMI cases. In the pooled analysis of the study cohort and the systematic review, 35 patients had AMI and 42 had myocarditis. Majority were men, and myocarditis patients were younger than AMI patients. Myocarditis patients tended to present 72 h postvaccination, while AMI patients were older and typically presented 24 h postvaccination. Majority with AMI or myocarditis developed symptoms after the first and second vaccination dose, respectively. This pooled analysis of patients presenting with cardiac manifestations following COVID-19 vaccination highlights the differences between myocarditis and AMI presentations in temporal association with the vaccination.

Introduction

Three Food and Drug Administration-approved vaccines (Pfizer-BioNTech, Moderna and Janssen) demonstrated efficacy and safety without major adverse effects in clinical trials.¹ However, emerging reports raise concerns on the potential association of

coronavirus disease-2019 (COVID-19) vaccination and adverse cardiac events² without any known underlying mechanisms.³ We sought to evaluate cardiac complications associated with COVID-19 vaccination in a pooled analysis from our institution's cohort study and systematic review.

Submitted: 18 September 2021

© The Author(s) 2021. Published by Oxford University Press on behalf of the Association of Physicians. All rights reserved. For permissions, please email: journals.permissions@oup.com

Materials and methods

Consecutive patients admitted in a tertiary hospital in Singapore between 1 January 2021 and 31 March 2021, with the onset of cardiovascular manifestations within 14 days following COVID-19 vaccination, were retrospectively included. This time-frame was adopted as most vaccine-related adverse events occurred within 14 days.⁴ The study was approved by the local ethics committee (2021/00089-AMD0001).

The systematic review was registered with the International Prospective Register of Systematic Reviews database (CRD42021247341) and was conducted with reference to the Preferred Reporting Items for Systematic Reviews and Meta-Analyses guidelines.⁵ We accessed PubMed, Embase, Research Square, MedRxiv and LitCovid databases, and relevant papers were identified from inception up to 29 June 2021. Keywords synonymous with 'myocarditis', 'myocardial infarction', 'cardiovascular complications' and 'COVID-19 vaccination' were used in the search strategy. Only case reports and case series reporting individual patient data were included. Inclusion criteria comprised: (i) studies reporting patients experiencing cardiovascular and cardiac complications, (ii) following COVID-19 vaccination and (iii) without COVID-19 infection at presentation. Cardiac manifestations were presented separately as myocarditis and acute myocardial infarction (AMI). The diagnosis of myocarditis was identified through cardiac magnetic resonance imaging,⁶ while the diagnosis of AMI was identified through blood tests, electrocardiography and coronary angiography.⁷ The main outcomes are the characteristics, diagnostic results and management of patients who experienced cardiac manifestations following the COVID-19 vaccination. The data were compiled using summary statistics. Binary variables were expressed as the count with its percentage and continuous variables were expressed as a median with its interquartile range (IQR). Further details are given in [Supplementary material 1](#).

Results

Thirty patients were included in the study cohort, with 29 diagnosed with AMI (14 ST-segment elevation and 15 non-ST-segment elevation MI) and 1 with myocarditis. Median hospital stay was 4.5 days (IQR 4.0–6.2). Five patients developed heart failure, two had cardiogenic shock, three intubated, and one had cardiovascular-related mortality. In the systematic review,

48 articles were sought for retrieval and 16 studies were included in the final analysis, with 41 myocarditis and 6 AMI cases reported ([Supplementary material 1](#)).

In the pooled analysis of the study cohort and the systematic review of published data of 77 patients, 35 had AMI, and 42 had myocarditis. Majority were men, and myocarditis patients were younger than AMI patients ([Figure 1A](#)). Myocarditis patients developed symptoms after a median of 3 days (IQR 2–3) postvaccination, with AMI patients after a median of 1 day (IQR 1–2) ([Figure 1B](#)). Thirty-five (83%) myocarditis and six (33%) AMI patients developed symptoms after their second dose. Majority of the myocarditis (83%) and AMI patients (86%) had the Pfizer BioNTech. The remaining patients with myocarditis received the Moderna vaccine (14%) and Janssen vaccine (2%), while the other AMI patients received the Oxford-AstraZeneca vaccine (11%) and Moderna vaccine (3%).

Characteristics of the pooled cohort is summarized in [Table 1](#). Left ventricular ejection fraction was lower than normal for all patients. Thirty-two (76%) myocarditis patients had late gadolinium enhancements (LGE) on cardiac magnetic resonance imaging, with the majority having subepicardial LGE followed by midmyocardial LGE. Among AMI patients who underwent coronary angiogram, percutaneous coronary intervention was performed in 60% of patients, with the left anterior descending artery being the most common culprit vessel. Medical treatment varied depending on the underlying pathology with myocarditis patients receiving nonsteroidal anti-inflammatory drugs and colchicine, and AMI patients receiving statins, antiplatelet therapy and beta-blockers.

Discussion

This study is the first and largest of its kind to examine the temporal association between COVID-19 vaccinations and adverse cardiac events. Our findings demonstrated that patients developing cardiovascular manifestations associated with COVID-19 vaccination were predominantly male. Those with myocarditis were younger and tended to present 72 h postvaccination, while those with AMI were older and typically presented 24 h postvaccination. Majority of patients who presented with myocarditis developed symptoms after the second vaccination dose, while most patients with AMI developed symptoms after the first dose.

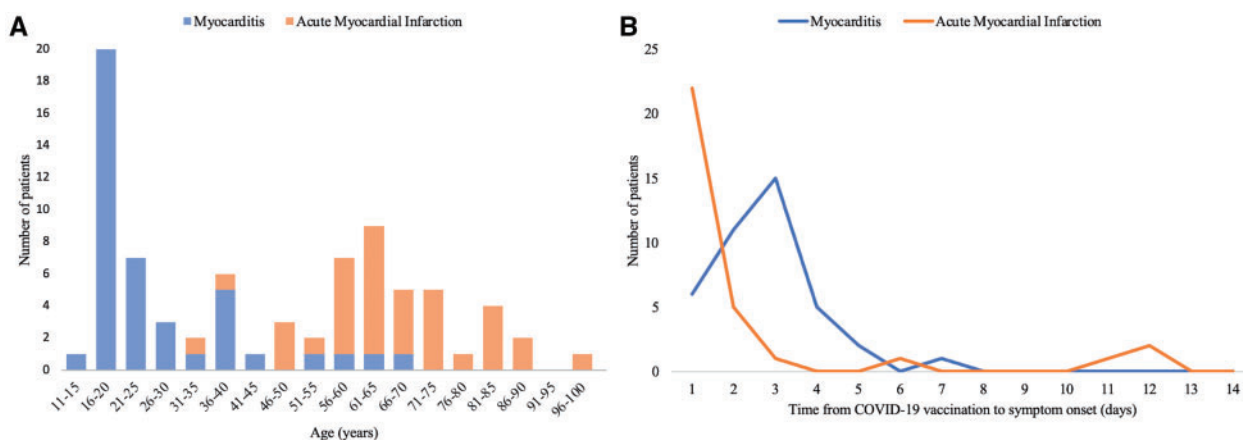


Figure 1. (A) Age distribution of patients presenting with myocarditis and acute myocardial infarction post-COVID-19 vaccination. (B) Distribution of time from COVID-19 vaccination to symptom onset for patients presenting with myocarditis and acute myocardial infarction with COVID-19 vaccination.

Table 1. Characteristics of combined patient data of patients with myocarditis and acute myocardial infarction following COVID-19 vaccination

	Myocarditis (N = 42)	Acute myocardial infarction (N = 35)
Patient and vaccination characteristics		
Age (years)	21 (17–30)	65 (59–74)
Sex (male)	38/42 (91)	28/35 (80)
Symptom onset after second vaccination dose	35/42 (83)	6/18 (33) ^a
Country of study		
USA	24/42 (57)	1/35 (3)
Israel	13/42 (31)	NA
Singapore	1/42 (2)	29/35 (83)
India	NA	4/35 (11)
Others ^b	4/42 (10)	1/35 (3)
Days from vaccination to symptom onset (days)	3 (2–3)	1 (1–2)
Symptom onset within one day postvaccination	6/42 (14)	22/32 (69) ^a
Vaccination profile		
mRNA vaccine		
Pfizer BioNTech	41/42 (98)	31/35 (89)
Moderna	35/42 (83)	30/35 (86)
Viral vector vaccine	6/42 (14)	1/35 (3)
Oxford-AstraZeneca	1/42 (2)	4/35 (11)
Janssen	NA	4/35 (11)
Past medical history		
Hypertension	1/42 (2)	NA
Hyperlipidemia	4/42 (10)	22/35 (63)
Diabetes mellitus	4/42 (10)	19/35 (54)
Chronic kidney failure	NA	18/35 (51)
Cancer	NA	5/35 (14)
Atrial fibrillation	NA	7/35 (20)
History of smoking	NA	3/35 (9)
Previous myocardial infarction	2/42 (5)	12/35 (34)
Previous percutaneous coronary intervention	NA	2/35 (6)
Previous coronary artery bypass grafting	NA	3/35 (9)
Previous stroke	NA	2/35 (6)
Laboratory variables		
C-reactive protein (mg/l)	NA	1/35 (3)
Peak troponin I (ng/l)	52 (27–79)	NA
Peak troponin T (ng/l)	8360 (6770–13 000)	8920 (1446–22 500)
12-lead electrocardiogram		
Presence of ST-segment elevation		
Diffuse	27/42 (64)	20/35 (57)
Anterior leads	8/42 (19)	NA
Lateral leads	9/42 (21)	7/35 (20)
Inferior leads	10/42 (24)	2/35 (6)
ST-segment myocardial infarction	5/42 (12)	7/35 (20)
Non-ST-segment myocardial infarction	NA	20/35 (57)
Transthoracic echocardiogram		
Left ventricular ejection fraction (%)	NA	15/35 (43)
Presence of regional wall motion abnormalities	54 (52–58)	50 (40–55)
Cardiac magnetic resonant imaging		
Presence of late gadolinium enhancement		
Subepicardial layer	11/42 (26)	25/28 (89) ^a
Midmyocardial layer	32/42 (76)	NA
Both layers	17/42 (41)	NA
Presence of edema		
Subepicardial layer	6/42 (14)	NA
Midmyocardial layer	9/42 (21)	NA
Both layers	26/42 (62)	NA
Coronary angiographic characteristics		
Underwent percutaneous coronary intervention	9/42 (21)	NA
Culprit vessel	26/42 (62)	NA
Left anterior descending artery	9/42 (21)	NA
Right coronary artery	7/42 (17)	NA
	10/42 (24)	7/35 (20)

(continued)

Table 1.. (continued)

	Myocarditis (N = 42)	Acute myocardial infarction (N = 35)
Left circumflex artery	NA	2/35 (5)
Others	NA	2/35 (5)
Multivessel disease	NA	7/35 (20)
Number of stents		
0	NA	4/35 (11)
1	NA	13/35 (37)
2	NA	4/35 (11)
Discharge medication		
NSAIDs	24/42 (57)	NA
Colchicine	13/42 (31)	NA
Aspirin	3/42 (7)	25/26 (96) ^a
P2Y ₁₂ inhibitor	NA	22/29 (76) ^a
Direct oral anticoagulants	NA	5/35 (14)
Beta-blockers	6/42 (14)	20/26 (77) ^a
ACE inhibitor/angiotensin converting enzyme	4/42 (10)	14/26 (54) ^a
Calcium channel blockers	NA	4/35 (11)
Nitrates	NA	3/35 (9)
Diuretics	NA	8/35 (23)
Statins	2/42 (5)	28/35 (80)

ACE, angiotensin-converting enzyme; NSAIDs, nonsteroidal anti-inflammatory drugs; mRNA, messenger ribonucleic acid; NA, data unavailable.

^aCensored for missing data.

^bItaly, Spain, Qatar and Poland. Continuous data presented as median (IQR); binary data presented as number (%).

Several hypotheses have been put forth to explain the mechanism underlying AMI following COVID-19 vaccination. Some argue that the prothrombotic state postvaccination is due to an autoimmune response against the platelets, which is clinically similar to autoimmune heparin-induced thrombocytopenia.^{8,9} Boivin and Martin,¹⁰ on the other hand, suggested that stress arising from receiving the COVID-19 vaccination could have led to demand ischemia, which culminated in a cardiovascular event. Furthermore, older adults tend to be polymorbid and the added stress from vaccination could serve as a trigger for the onset of AMI. In addition, postvaccination AMI could also be attributed to allergic vasospasm in response to the vaccine, which is termed Kounis syndrome, and it has been argued that the elevated levels of immunoglobulin E antibodies could be a risk factor for AMI.^{11,12} On the other hand, the pathophysiology of myocarditis following COVID-19 vaccination is likely to be different. Myocarditis was previously reported as a side effect of several vaccines, especially the smallpox vaccine.¹³ Though the mechanism is unknown, it is suggested that myocarditis could be a result of an autoimmune response arising from either the similarities between the vaccine and cardiac cell proteins, or the nonspecific inflammatory response following vaccination.¹⁴ Studies evaluating the pathophysiological mechanism of vaccine-related adverse events could help identify subjects at risk of developing these events.

Despite recent emerging literature supporting the temporal association between cardiac manifestations and vaccination, these findings are to be interpreted with caution as causality cannot be deduced. Nonetheless, health authorities must maintain vigilance through continued monitoring of serious COVID-19 vaccine side-effects, with the Dengvaxia controversy in the Philippines serving as a reminder.¹⁵ Population-based studies might help elucidate if myocarditis and AMI rates are higher in the vaccination era compared to prepandemic times. For now, COVID-19 vaccines remain the cornerstone in our fight against the contagion.

Conclusion

This pooled analysis of patients presenting with cardiac manifestations following the COVID-19 vaccination highlights the differences between myocarditis and AMI presentations in temporal association with the COVID-19 vaccination.

Supplementary material

Supplementary material is available at QJMED online.

Funding

None.

Conflict of interest. M.Y.C.: Speaker's fees and research grants Astra Zeneca, Abbott Technologies and Boston Scientific. The remaining authors have nothing to disclose.

Ethical approval

NHG Research – DSRB: 2021/00089-AMD0001.

References

- Rosner CM, Genovese L, Tehrani BN, Atkins M, Bakhshi H, Chaudhri S, et al. Myocarditis temporally associated with COVID-19 vaccination. *Circulation* 2021; **144**:502–5.
- Snapiri O, Rosenberg Danziger C, Shirman N, Weissbach A, Lowenthal A, Ayalon I, et al. Transient cardiac injury in adolescents receiving the BNT162b2 mRNA COVID-19 vaccine. *Pediatr Infect Dis J* 2021;
- Centers for Disease Control and Prevention (CDC). Myocarditis and pericarditis following mRNA COVID-19 vaccination. Accessed on 10 September 2021, <https://www.cdc.gov/coronavirus/2019-ncov/vaccines/safety/myocarditis.html>

4. Centers for Disease Control and Prevention (CDC). Joint CDC and FDA statement on Johnson & Johnson COVID-19 vaccine. Accessed on 10 September 2021, <https://www.fda.gov/news-events/press-announcements/joint-cdc-and-fda-statement-johnson-johnson-covid-19-vaccine>
5. Page MJ, McKenzie JE, Bossuyt PM, Boutron I, Hoffmann TC, Mulrow CD, et al. The PRISMA 2020 statement: an updated guideline for reporting systematic reviews. *BMJ* 2021; 372.
6. Caforio ALP, Pankuweit S, Arbustini E, Basso C, Gimeno-Blanes J, Felix SB, et al.; European Society of Cardiology Working Group on Myocardial and Pericardial Diseases. Current state of knowledge on aetiology, diagnosis, management, and therapy of myocarditis: a position statement of the European Society of Cardiology Working Group on Myocardial and Pericardial Diseases. *Eur Heart J* 2013; 34: 2636–48.
7. Ibanez B, James S, Agewall S, Antunes MJ, Bucciarelli-Ducci C, Bueno H, et al.; ESC Scientific Document Group. 2017 ESC Guidelines for the management of acute myocardial infarction in patients presenting with ST-segment elevation: the Task Force for the management of acute myocardial infarction in patients presenting with ST-segment elevation of the European Society of Cardiology (ESC). *Eur Heart J* 2018; 39: 119–77.
8. Greinacher A, Thiele T, Warkentin TE, Weisser K, Kyrle PA, Eichinger S. Thrombotic Thrombocytopenia after ChAdOx1 nCov-19 vaccination. *N Engl J Med* 2021; 384:2092–101.
9. Wise J. Covid-19: European countries suspend use of Oxford-AstraZeneca vaccine after reports of blood clots. *BMJ* 2021;372:n699.
10. Boivin Z, Martin J. Untimely myocardial infarction or COVID-19 vaccine side effect. *Cureus* 2021; 13:e13651.
11. Kounis NG, Koniari I, de Gregorio C, Velissaris D, Petalas K, Brinia A, et al. Allergic reactions to current available COVID-19 vaccinations: pathophysiology, causality, and therapeutic considerations. *Vaccines* 2021; 9:221.
12. Kounis NG, Mazarakis A, Tsigkas G, Giannopoulos S, Goudevenos J. Kounis syndrome: a new twist on an old disease. *Future Cardiol* 2011; 7:805–24.
13. Mei R, Raschi E, Forcesi E, Diemberger I, De Ponti F, Poluzzi E. Myocarditis and pericarditis after immunization: gaining insights through the Vaccine Adverse Event Reporting System. *Int J Cardiol* 2018; 273:183–6.
14. Segal Y, Shoenfeld Y. Vaccine-induced autoimmunity: the role of molecular mimicry and immune crossreaction. *Cell Mol Immunol* 2018; 15:586–94.
15. Chew NWS, Cheong C, Kong G, Phua K, Ngiam JN, Tan BYQ, et al. An Asia-Pacific study on healthcare workers' perceptions of, and willingness to receive, the COVID-19 vaccination. *Int J Infect Dis* 2021; 106:52–60.