

# Central retinal vein occlusion after mRNA SARS-CoV-2 vaccination: A case report

Beatriz Endo<sup>1,2</sup>, Silvana Bahamon<sup>1,2</sup>,  
Dayron F Martínez-Pulgarín<sup>2</sup>

A central retinal vein occlusion (CRVO) case in a patient developed with sudden blurred vision in some hemifield areas of his left eye, maintaining 20/20 vision 15-days after the COVID-19 vaccination. Initial retinal findings were venous dilation and tortuosity with dispersing dot hemorrhages. Fluorescein angiography (FA) and optical coherence tomography (OCT) confirmed a non-ischemic CRVO diagnosis, and a complete blood panel was requested with average results. An intravitreal steroid dose was applied. A decrease in best-corrected visual acuity (BCVA) (20/30) with more intraretinal hemorrhages was documented. An intravitreal dose of bevacizumab and oral apixaban were added with a final BCVA of 20/20 with decreased hemorrhages. There is no specific causal relationship between COVID-19 vaccines and CRVO. Without previous risk factors and positive treatment response, this case may correlate the first COVID-19 vaccine dose and the event.

**Key words:** CRVO, COVID-19, SARS-Cov2, vaccine

BNT162b2 is a mRNA vaccine developed by Pfizer-BioNTech to prevent the disease caused by severe acute respiratory syndrome coronavirus 2 (SARS-CoV-2).<sup>[1]</sup> We present a central retinal vein occlusion (CRVO) case that developed 15 days after the first COVID-19 vaccine dose. The purpose of this case report is to draw attention to the potential for sight-threatening complications in patients receiving this kind of vaccine. However, the event could have been coincidental to its use.

## Case Report

A 52-year-old male with no pathological or family history presented with sudden blurred vision in his left eye (LE),

especially in the nasal and superotemporal quadrant, for one day, without other symptoms. As relevant information, he received the first dose of the Pfizer–BioNTech vaccine 15 days prior.

His best-corrected visual acuity (BCVA) was 20/20 for both eyes. The fundus exam showed minimal dot hemorrhages in the upper quadrants of his LE, dilated tortuous veins in four quadrants, and disperse exudates; The right eye (RE) showed only changes in the macular RPE.

A FA was performed on admission showing a delay of normal fluorescence in the arterial phase in the LE. Early phases showed hypofluorescence near the temporal and inferonasal branches, with blocking areas corresponding to hemorrhages in the superior quadrants. In late phases, it was evident that there was a temporal branch occlusion given by the absence of venous filling and slight hyperfluorescence in the nasal and temporal portion of the optic nerve [Fig. 1]. Macular coherent optical tomography (OCT) was taken on the same day, ruling out macular edema.

A diagnosis of non-ischemic central retinal vein occlusion (CRVO) on LE was considered. In the absence of risk factors for CRVO, hemogram, antithrombin III, coagulation protein C and S, Factor V Leiden, homocysteine in blood, folic acid, rheumatoid factor, ANAS, VDRL, FTA-ABS, HIV, glycosylated hemoglobin, pre and postprandial glycemia, lipid profile, ambulatory monitoring of blood pressure, creatinine, and prostate-specific antigen (PSA) were requested.

After three days, all requested exam results were within normal ranges. An increase in intraretinal hemorrhages was observed in the fundus exam [Fig. 2], with no variations in the BCVA. An intravitreal dose of dexamethasone 0.4 mg/0.1 ml was administered, followed by an improvement in the fundus findings after six days.

Eleven days after the onset of symptoms, a slight decrease in BCVA of the LE (20/30) was observed with an increase of intraretinal spot hemorrhages. An intravitreal dose of bevacizumab 2.5 mg/0.1 ml and oral apixaban were ordered. Five days later, the BCVA improved to 20/20, and hemorrhages decreased. An IgG and IgM for COVID-19 were requested, which were positive according to the recent vaccination history.

## Discussion

To the best of our knowledge, there are no reported cases in the world literature documenting CRVOs related to vaccination for COVID-19. Common risk factors include cardiovascular disease, hypertension, glaucoma, diabetes mellitus, and, in

Access this article online	
<b>Quick Response Code:</b>	<b>Website:</b> www.ijjo.in
	<b>DOI:</b> 10.4103/ijjo.IJO_1477_21

<sup>1</sup>Department of Retina, Clínica de Oftalmología de Cali, Cali,  
<sup>2</sup>Vitreo-Retinal Fellowship Program, Pontificia Universidad Javeriana Cali, Cali, Colombia

**Correspondence to:** Beatriz Endo, Department of Retina, Clínica de Oftalmología de Cali, Cali - 760 036, Colombia. E-mail: beatrizendo84@gmail.com

Received: 29-May-2021

Revision: 21-Aug-2021

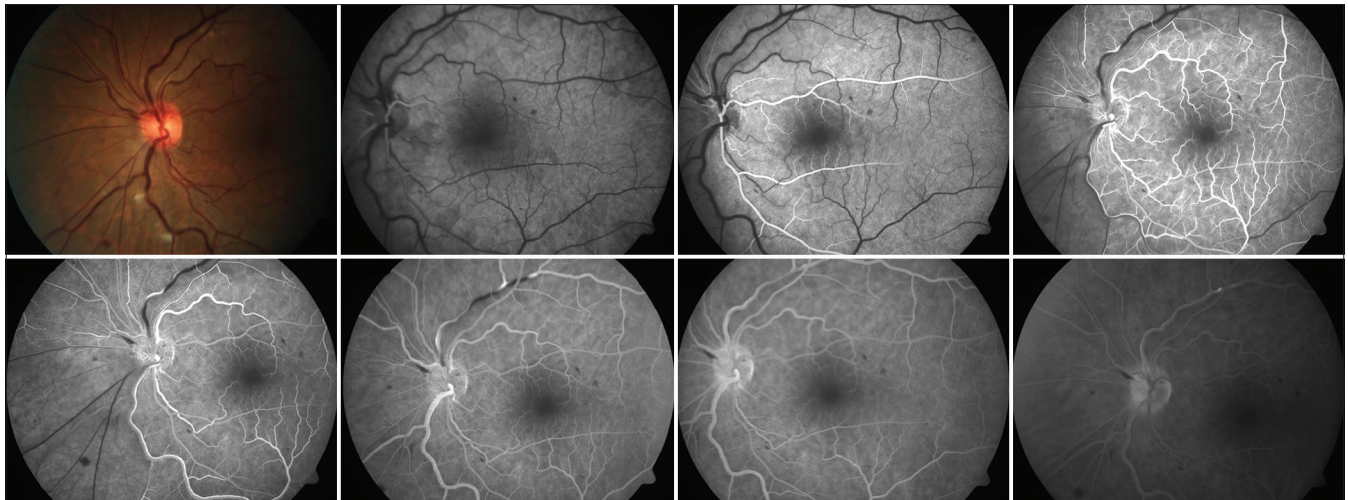
Accepted: 26-Aug-2021

Published: 25-Sep-2021

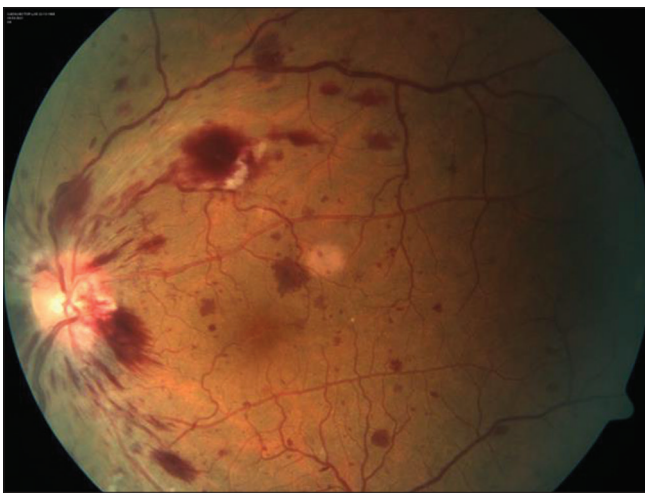This is an open access journal, and articles are distributed under the terms of the Creative Commons Attribution-NonCommercial-ShareAlike 4.0 License, which allows others to remix, tweak, and build upon the work non-commercially, as long as appropriate credit is given and the new creations are licensed under the identical terms.

**For reprints contact:** WKHLRPMedknow\_reprints@wolterskluwer.com

**Cite this article as:** Endo B, Bahamon S, Martínez-Pulgarín DF. Central retinal vein occlusion after mRNA SARS-CoV-2 vaccination: A case report. Indian J Ophthalmol 2021;69:2865-6.



**Figure 1:** Admission fluorescein angiography of the left eye showing blocking and hypoperfusion areas in temporal and inferonasal quadrants. Absence of venous filling was evidenced in late phases



**Figure 2:** Color fundus photography of the left eye showing dot-blot and flame hemorrhages, dilated tortuous veins, and blurred margins in the disc especially in the temporal quadrant

young patients, hematologic disorders.<sup>[2]</sup> Our patient had no previous history of any of these conditions.

In March 2021, concerns were raised worldwide over thromboembolic events after immunization with Oxford–AstraZeneca and Janssen vaccines<sup>[3,4]</sup> and thrombocytopenia and deep venous thrombosis after immunization with Pfizer vaccine.<sup>[5,6]</sup> There was suspicion around this being secondary to an atypical proinflammatory and procoagulant response similar to the one caused by COVID-19.

Nowadays, it is impossible to assure a causal relationship between COVID-19 vaccines and CRVO. However, the presence of this pathology in a patient without previous risk factors and a positive response to intravitreal steroids, antiangiogenics, and systemic anticoagulation may suggest a correlation between the COVID-19 vaccine and the event. This case may indicate a vaccine-induced CRVO.

## Conclusion

Our case represents CRVO following mRNA SARS-CoV-2 vaccination.

### Declaration of patient consent

The authors certify that they have obtained all appropriate patient consent forms. In the form, the patient(s) has/have given his/her/their consent for his/her/their images and other clinical information to be reported in the journal. The patients understand that their names and initials will not be published and due efforts will be made to conceal their identity, but anonymity cannot be guaranteed.

### Financial support and sponsorship

Nil.

### Conflicts of interest

There are no conflicts of interest.

## References

1. Lamb YN. BNT162b2 mRNA COVID-19 vaccine: First approval. *Drugs* 2021;81:495-501.
2. Lahey JM, Tunç M, Kearney J, Modlinski B, Koo H, Johnson RN, *et al.* Laboratory evaluation of hypercoagulable states in patients with central retinal vein occlusion who are less than 56 years of age. *Ophthalmology* 2002;109:126-31.
3. European Medicines Agency. COVID-19 Vaccine Janssen: EMA finds possible link to very rare cases of unusual blood clots with low blood platelets, 2021. Available from: <https://www.ema.europa.eu/en/news/covid-19-vaccine-janssen-ema-finds-possible-link-very-rare-cases-unusual-blood-clots-low-blood>. [Last accessed on 2021 Apr 23].
4. Merchant HA. CoViD vaccines and thrombotic events: EMA issued warning to patients and healthcare professionals. *J Pharm Policy Pract* 2021;14:32.
5. Carli G, Nichele I, Ruggeri M, Barra S, Tosetto A. Deep vein thrombosis (DVT) occurring shortly after the second dose of mRNA SARS-CoV-2 vaccine. *Intern Emerg Med* 2021;16:803-4.
6. Lee E-J, Cines DB, Gernsheimer T, Kessler C, Michel M, Tarantino MD, *et al.* Thrombocytopenia following Pfizer and Moderna SARS-CoV-2 vaccination. *Am J Hematol* 2021;96:534-7.