

Ben Y. Reis, Ph.D.

Boston Children's Hospital
Boston, MA

Noa Dagan, M.D.

Ran D. Balicer, M.D.

Clalit Research Institute
Tel Aviv, Israel
rbalicer@clalit.org.il

and Others

Drs. Reis and Barda and Drs. Dagan and Balicer contributed equally to this letter.

A complete list of authors is available with the full text of this letter at NEJM.org.

Supported by the Ivan and Francesca Berkowitz Family Living Laboratory Collaboration at Harvard Medical School and Clalit Research Institute.

Disclosure forms provided by the authors are available with the full text of this letter at NEJM.org.

This letter was published on October 20, 2021, at NEJM.org.

1. Lopez Bernal J, Andrews N, Gower C, et al. Effectiveness of Covid-19 vaccines against the B.1.617.2 (Delta) variant. *N Engl J Med* 2021;385:585-94.
2. Puranik A, Lenehan PJ, Silvert E, et al. Comparison of two highly-effective mRNA vaccines for COVID-19 during periods of Alpha and Delta variant prevalence. August 21, 2021 (<https://www.medrxiv.org/content/10.1101/2021.08.06.21261707v3>). preprint.
3. Herlihy R, Bamberg W, Burakoff A, et al. Rapid increase in circulation of the SARS-CoV-2 B.1.617.2 (Delta) variant — Mesa County, Colorado, April–June 2021. *MMWR Morb Mortal Wkly Rep* 2021;70:1084-7.
4. Frenck RW Jr, Klein NP, Kitchin N, et al. Safety, immunogenicity, and efficacy of the BNT162b2 Covid-19 vaccine in adolescents. *N Engl J Med* 2021;385:239-50.
5. Dagan N, Barda N, Kepten E, et al. BNT162b2 mRNA Covid-19 vaccine in a nationwide mass vaccination setting. *N Engl J Med* 2021;384:1412-23.

DOI: 10.1056/NEJMc2114290

Vaccine-Induced Thrombocytopenia with Severe Headache

TO THE EDITOR: Vaccine-induced immune thrombotic thrombocytopenia (VITT), a serious adverse event after vaccination with ChAdOx1 nCoV-19 (AstraZeneca) or Ad26.COV2.S (Johnson & Johnson–Janssen), is caused by platelet factor 4 (PF4)–dependent, platelet-activating antibodies.^{1,3} High-dose immune globulins and anticoagulation are the main treatments.^{4,5} In this report, we present evidence that vaccine-induced thrombocytopenia (VIT) without associated cerebral venous sinus thrombosis (CVST) or other thromboses and with severe headache as the heraldic symptom may precede VITT (“pre-VITT syndrome”).

Eleven patients presented with severe headache in the absence of CVST 5 to 18 days after ChAdOx1 nCoV-19 vaccination. All the patients had thrombocytopenia, high D-dimer levels, and high levels of anti-PF4–heparin IgG antibodies. During follow-up, intracranial hemorrhage occurred in three patients (Patients 1, 2, and 3), with radiologic evidence of new CVST in Patients 2 and 3 (Fig. 1, and Table S1 in the Supplementary Appendix, available with the full text of this letter at NEJM.org). Only two patients (Patients 2 and 4) were initially admitted with conditions that met the criteria for VITT; both patients had pulmonary embolism, and additional splanchnic vein thrombosis was present in Patient 2. In Patient 2, anticoagulation treatment had been initiated several days earlier for pulmonary embolism (without diagnosis of VITT) but was stopped after the onset of headache, shortly be-

fore CVST developed. In two patients (Patients 1 and 3), peripheral thromboses were eventually identified during follow-up. Thrombotic complications did not develop in seven of the patients (Patients 5 through 11); all but one of these patients received high-dose immune globulin, glucocorticoids, or therapeutic-dose anticoagulation within 5 days after headache onset. In contrast, in all four patients with subsequent thrombosis (Patients 1 through 4), therapeutic-dose anticoagulation either was not started until 6 to 9 days after headache onset or was stopped prematurely before the development of CVST.

Although the combination of thrombocytopenia and severe headache due to CVST has been recognized as the typical presentation of VITT,^{1,2} the experience with these 11 patients suggests that VIT with severe headache, elevated D-dimer levels, and strongly positive results on anti-PF4–heparin IgG enzyme-linked immunosorbent assay may precede VITT.

Our findings have immediate implications for clinical practice: in this pre-VITT syndrome, severe headache may not develop as a symptom secondary to CVST but instead may precede CVST by several days, potentially in association with microthrombosis in smaller cortical veins. Consequently, patients who present with severe headache 5 to 20 days after adenovirus vector vaccination against coronavirus disease 2019 should undergo immediate testing for thrombocytopenia and D-dimer levels and, if available,

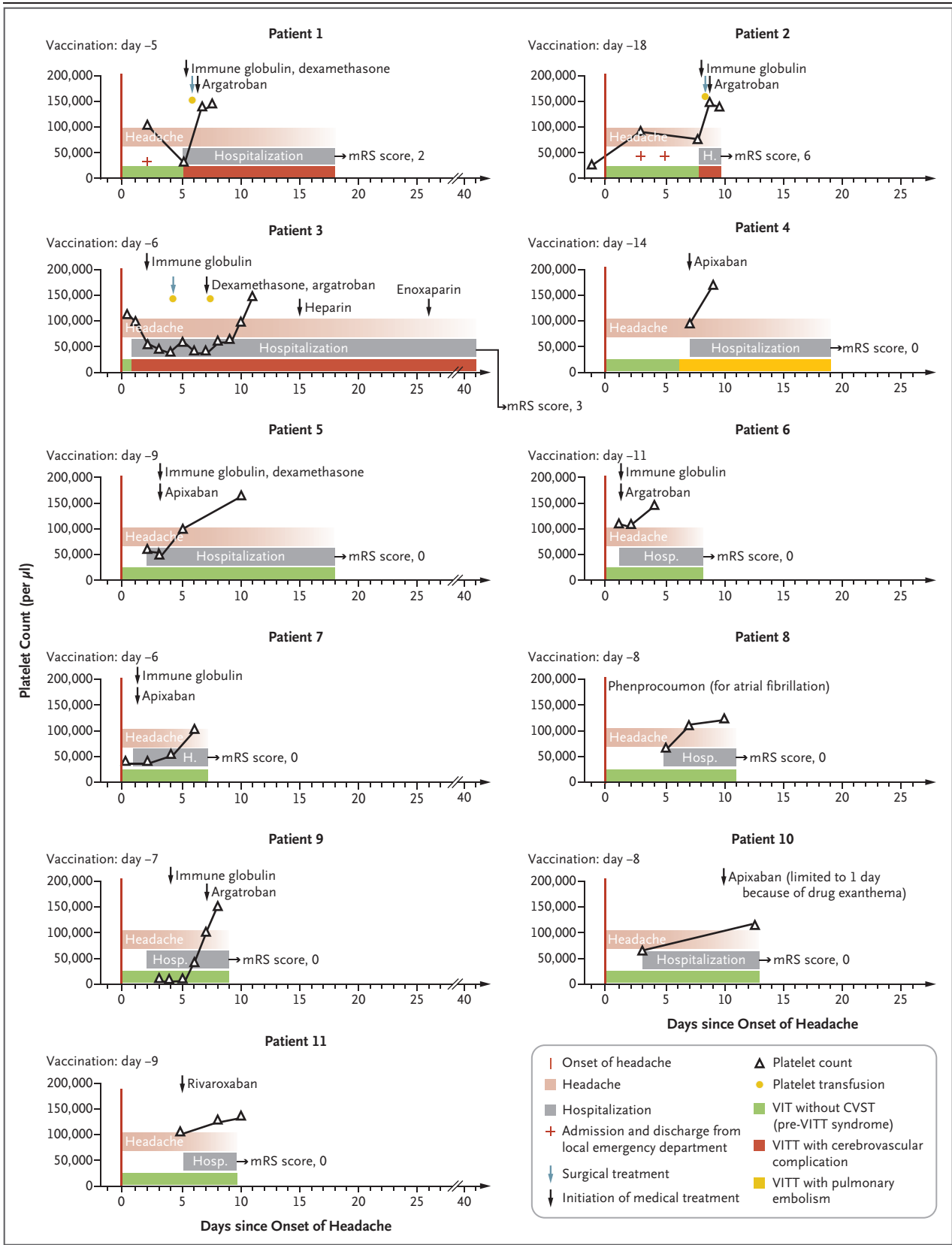


Figure 1 (facing page). Clinical and Laboratory Data for Patients with VIT and Severe Headache (Pre-VITT Syndrome).

Shown are the time courses of the manifestation of pre-VITT syndrome (defined by headache onset), hospital admission (including emergency department admission and discharge in Patients 1 and 2), platelet counts, and cerebrovascular complications (in Patients 1, 2, and 3), as well as medical and neurosurgical treatment (decompressive craniectomy). In each graph, the number of days since the onset of headache is shown on the x axis and platelet counts on the y axis. Outcomes were assessed with the modified Rankin scale (mRS); scores on the scale range from 0 to 6, with higher scores indicating greater disability (0 indicates no symptoms, and 6 indicates death). CVST denotes cerebral venous sinus thrombosis, VIT vaccine-induced thrombocytopenia, and VITT vaccine-induced immune thrombotic thrombocytopenia.

testing for anti-PF4–heparin IgG antibodies. When these antibodies are present at high titers, patients are at imminent risk for CVST, and it is likely that this condition can be prevented with immediate treatment, such as with intravenous immune globulin. The decision to initiate therapeutic-dose anticoagulation is a difficult one; the risk of emerging thrombosis, including CVST, has to be balanced against the risk of intracranial hemorrhage on an individual basis (e.g., with consideration of platelet count and fibrinogen levels).

Farid Salih, M.D.

Charité-Universitätsmedizin Berlin
Berlin, Germany
farid.salih@charite.de

Linda Schönborn, M.D.

Universitätsmedizin Greifswald
Greifswald, Germany

Siegfried Kohler, M.D.

Christiana Franke, M.D.

Martin Möckel, M.D.

Thomas Dörner, M.D.

Hans C. Bauknecht, M.D.

Christian Pille, M.D.

Jan A. Graw, M.D.

Charité-Universitätsmedizin Berlin
Berlin, Germany

Angelika Alonso, M.D.

University Hospital of Mannheim
Mannheim, Germany

Johann Pelz, M.D.

University Hospital of Leipzig
Leipzig, Germany

Hauke Schneider, M.D.

Antonios Bayas, M.D.

Monika Christ, M.D.

University Hospital of Augsburg
Augsburg, Germany

Joji B. Kuramatsu, M.D.

University Hospital of Erlangen
Erlangen, Germany

Thomas Thiele, M.D.

Andreas Greinacher, M.D.

Universitätsmedizin Greifswald
Greifswald, Germany
andreas.greinacher@med.uni-greifswald.de

Matthias Endres, M.D.

Charité-Universitätsmedizin Berlin
Berlin, Germany
matthias.endres@charite.de

Profs. Greinacher and Endres contributed equally to this letter.

Supported by Deutsche Forschungsgemeinschaft project number 374031971-TRR 240 (to Prof. Greinacher) and EXC-2049-390688087 NeuroCure under the German Excellence Strategy (to Prof. Endres) and by the Domagk-Programm of the Universitätsmedizin Greifswald (to Dr. Schönborn).

Disclosure forms provided by the authors are available with the full text of this letter at NEJM.org.

This letter was published on September 15, 2021, at NEJM.org.

1. Long B, Bridwell R, Gottlieb M. Thrombosis with thrombocytopenia syndrome associated with COVID-19 vaccines. *Am J Emerg Med* 2021;49:58-61.
2. Greinacher A, Thiele T, Warkentin TE, Weisser K, Kyrle PA, Eichinger S. Thrombotic thrombocytopenia after ChAdOx1 nCov-19 vaccination. *N Engl J Med* 2021;384:2092-101.
3. Scully M, Singh D, Lown R, et al. Pathologic antibodies to platelet factor 4 after ChAdOx1 nCov-19 vaccination. *N Engl J Med* 2021;384:2202-11.
4. Bussell JB, Connors JM, Cines DB, et al. Thrombosis with thrombocytopenia syndrome (also termed vaccine-induced thrombotic thrombocytopenia), version 1.6. *American Society of Hematology*, August 12, 2021 (<https://www.hematology.org/covid-19/vaccine-induced-immune-thrombotic-thrombocytopenia>).
5. Bourguignon A, Arnold DM, Warkentin TE, et al. Adjunct immune globulin for vaccine-induced thrombotic thrombocytopenia. *N Engl J Med* 2021;385:720-8.

DOI: 10.1056/NEJMc2112974

Efpeglenatide and Heart and Kidney Outcomes in Type 2 Diabetes

TO THE EDITOR: In the AMPLITUDE-O trial, Gerstein et al. (Sept. 2 issue)¹ found a lower risk of cardiovascular events among participants with

type 2 diabetes who received a weekly injection of efpeglenatide than among those who received placebo. This trial confirms the interest in gluca-