



**Letter to the Editor**

**A Rare Case of Superior Ophthalmic Vein Thrombosis and Thrombocytopenia Following ChAdOx1 nCoV-19 Vaccine Against SARS-CoV-2**

**Keywords:** COVID-19; Ophthalmic vein thrombosis; Thrombocytopenia.

**Published:** July 1, 2021

**Received:** June 6, 2021

**Accepted:** June 12, 2021

**Citation:** Panovska-Stavridis I., Pivkova-Veljanovska A., Trajkova S., Lazarevska M., Grozdanova A., Filipche V. A rare case of superior ophthalmic vein thrombosis and thrombocytopenia following ChAdOx1 nCoV-19 vaccine against SARS-CoV-2. *Mediterr J Hematol Infect Dis* 2021, 13(1): e2021048, DOI: <http://dx.doi.org/10.4084/MJHD.2021.048>

This is an Open Access article distributed under the terms of the Creative Commons Attribution License (<https://creativecommons.org/licenses/by-nc/4.0/>), which permits unrestricted use, distribution, and reproduction in any medium, provided the original work is properly cited.

**To the editor.**

Since December 2020, humankind, in an attempt to control the COVID-19 pandemic, experienced the biggest vaccine rollout and immunization process ever remembered. As of May 1, 2021, more than 1 billion doses of a COVID-19 vaccine have been administered worldwide. There are several COVID-19 vaccines available, but only four of them have received emergency use approval by EMA and/or FDA.<sup>1</sup> Ongoing studies are still analyzing their efficacy against the new emerging mutant SARS-CoV2 variants and their safety profile.<sup>2</sup>

We present a case of vaccine-induced prothrombotic immune thrombocytopenic (VIPIT) disorder following ChAdOx1 nCoV-19 vaccine in a 29 years old, previously healthy, Caucasian female, which manifested with superior ophthalmic vein (SOV) thrombosis and thrombocytopenia.<sup>3,4</sup> The patient was referred to our Clinic on March 30, 2021, complaining of severe headache, left orbital swelling, and blurred left eye vision. Initial findings showed thrombocytopenia of  $18 \times 10^9$  per L in association with high D-dimers levels of 35712  $\mu\text{g/L}$ . At physical examination, the patient showed left eyeball swelling with proptosis, limited ocular motility, and diplopia at the vertical gaze (**Figure 1a**).

The symptoms dated one day before admission, starting with flu-like symptoms and fever. She has received the first dose of vaccine against SARS-CoV-2, ChAdOx1 nCoV-19, ten days before admission. Her medical and pharmacological history were unremarkable negative. She also reported one day of fever after the vaccination. The CT scan of the head was normal. Diagnostic blood examinations showed a normal blood smear, apart from the thrombocytopenia, elevated CRP (142mg/L), and normal prothrombin, activated partial thromboplastin, and thrombin time and fibrinogen level (2.5g/L). The nasopharyngeal swab for SARS-CoV2 nucleic acid testing was negative, and

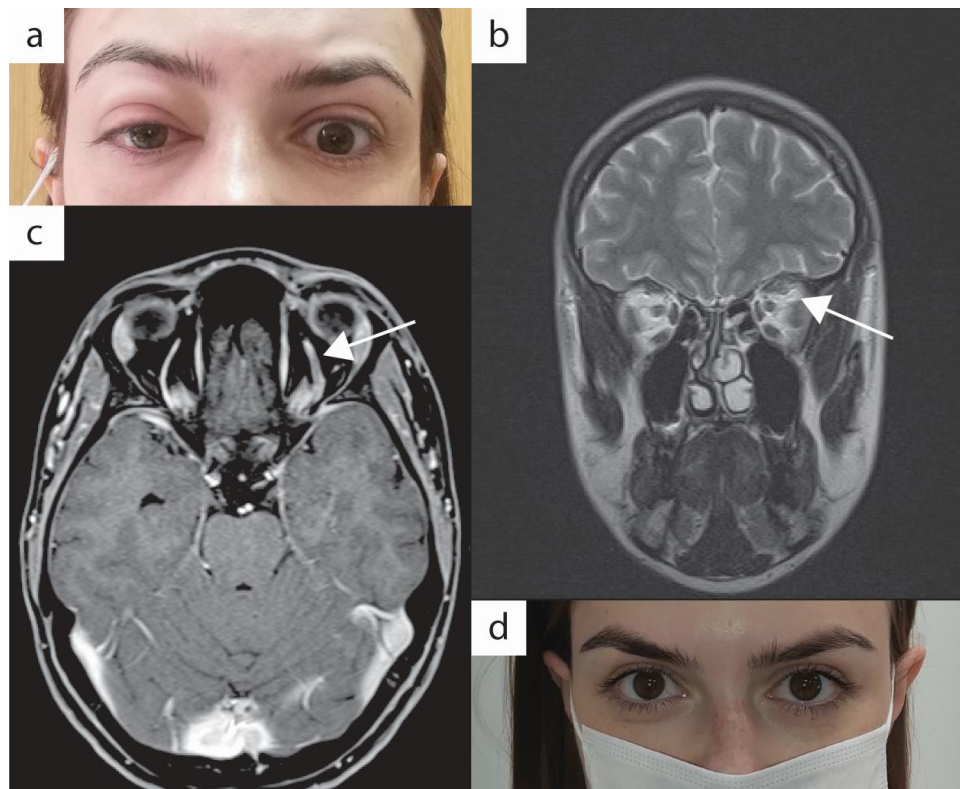
serology revealed the presence of SARS-CoV-RBD IgG 59.46 and IgM 1.5 AU/ml, although the patient had no history of infection since the pandemic started.

Contrast-enhanced MRI demonstrated central filling defects (**Figure 1b**) and hyper T2 signal (**Figure 1c**) in the left superior ophthalmic vein (SOV), revealing thrombosis.<sup>5</sup>

Screening for antibodies for Heparin/Platelet Factor 4 (PF4) complex using a particle gel immune assay (ID-PaGIA Heparin/PF4 Antibody test) revealed a very high level of antibodies agents the PF4 complex.<sup>6</sup>

Testing for hereditary thrombophilia (Factor V Leiden R506Q mutation, Prothrombin G20210A gene mutation) and other triggers for thrombosis and thrombocytopenia, including lupus anticoagulant, protein C and S activity, cardiolipin IgG and IgM antibodies, hepatitis B and C virus, HIV, cytomegalovirus, and Helicobacter pylori infection, were all negative.

The presence of elevated D-dimers in association with immune thrombocytopenia and MRI-confirmed thrombosis make the diagnosis of vaccine-induced prothrombotic immune thrombocytopenia (VIPIT) probable.<sup>3</sup> Treatment for this condition was initiated following the recommendation of the Drugs & Biologics Clinical Practice Guidelines Working Group and the Ontario COVID-19 Science Advisory Table.<sup>4</sup> Intravenous immunoglobulin (IVIg) 1 g/kg of body weight daily for two days, broad-spectrum antibiotics and direct oral anti-Xa inhibitor, Rivaroxaban, 15mg twice daily for 21 days were administrated. Afterward, immunosuppression was continued with oral prednisolone 1mg/kg bw for seven days, with tapering afterward. The patient recovered remarkably rapidly, all the symptoms resolved within 4 to 5 days (**Figure 1d**), platelets raised to normal level after a week of treatment, and the D-dimer levels went to normal after two weeks of treatment. The patient was discharged home after six



**Figure 1.** Clinical presentation of the VIPIT and SOV thrombosis after ChAdOx1 nCoV-19 vaccination. **A:** patient presentation at admission with marked proptosis, **B:** contrast enhanced MRI revealed SOV thrombosis, presented with widening SOV and filling defects, **C:** T2 sequence further confirmed SOV thrombosis with the enhanced signal intensity of SOV, **D:** no symptoms after five days of treatment, published with patient's permission.

days.

She is still on prednisolone and Rivaroxaban 20mg daily and will continue for another two months. Since April 9, 2021, the EMA has been listed the condition of unusual blood clots with low blood platelets occurring in the first two weeks after the ChAdOx1 nCoV-19 vaccine as a very rare side effect of this vaccine. A few weeks later, the FDA associated the same side effect

with the Janssen ad26.cov2.s (COVID-19) vaccine. Thus, both regulatory agencies underline that the benefits of both vaccines are far greater than their risk.<sup>7,8</sup>

Most of the reported VIPT patients presented with cerebral venous sinus and splanchnic vein thrombosis, but other rare thrombotic complications are possible, and our case of SOV thrombosis is the second-ever described.<sup>5</sup>

Irina Panovska-Stavridis<sup>1</sup>, Aleksandra Pivkova-Veljanovska<sup>1</sup>, Sanja Trajkova<sup>1</sup>, Menka Lazarevska<sup>3</sup>, Aleksandra Grozdanova<sup>4</sup> and Venko Filipche<sup>5</sup>.

<sup>1</sup> University Ss. Cyril and Methodius – Skopje, Medical Faculty, University Clinic of Hematology – Skopje, Republic of North Macedonia.

<sup>2</sup> University Ss. Cyril and Methodius – Skopje, Medical Faculty, University Clinic of Radiology – Skopje, Republic of North Macedonia.

<sup>3</sup> University Ss. Cyril and Methodius – Skopje, Faculty of Pharmacy – Skopje, Republic of North Macedonia.

<sup>4</sup> University Ss. Cyril and Methodius – Skopje, Medical Faculty, University Clinic for Neurosurgery – Skopje, Republic of North Macedonia.

**Competing interests:** The authors declare no conflict of Interest.

Correspondence to: Ass. Prof. Irina Panovska-Stavridis, MD. University Clinic of Hematology-Skopje, Majka Tereza 17, Skopje, Republic of North Macedonia. E-mail: [dr\\_irina@yahoo.com](mailto:dr_irina@yahoo.com)

## References:

1. WHO. WHO target product profiles for COVID-19 vaccines April 9, 2020. <https://www.who.int/publications/m/item/whotarget-product-profiles-for-COVID-19-vaccines> (accessed, Maj 5, 2021).
2. Voysey M, Clemens SAC, Madhi SA, et al. Safety and efficacy of the ChAdOx1 nCoV-19 vaccine (AZD1222) against SARS-CoV-2: an interim analysis of four randomised controlled trials in Brazil, South Africa, and the UK. *Lancet* 2021 J; 397(10269):99-111. [https://doi.org/10.1016/S0140-6736\(20\)32661-1](https://doi.org/10.1016/S0140-6736(20)32661-1)
3. Greinacher A, Thiele T, Warkentin TE, Weisser K, Kyrle PA, Eichinger S. Thrombotic thrombocytopenia after ChAdOx1 nCov-19 vaccination.

- N Engl J Med. 2021 Apr 9; NEJMoa2104840. <https://doi.org/10.1056/NEJMoa2104840>  
PMid:33835769 PMCID:PMC8095372
4. Pai M, Chan B, Stall NM, et al. Vaccine-induced immune thrombotic thrombocytopenia (VITT) following adenovirus vector COVID-19 vaccination. Science Briefs of the Ontario COVID-19 Science Advisory Table. 2021;2(17):1-7.  
<https://doi.org/10.47326/ocsat.2021.02.17.2.0>
  6. Bayas A, Menacher M2, Christ M, et al. Bilateral superior ophthalmic vein thrombosis, ischaemic stroke, and immune thrombocytopenia after ChAdOx1 nCoV-19 vaccination Lancet 2021 May 1; 397(10285):e11.  
[https://doi.org/10.1016/S0140-6736\(21\)00872-2](https://doi.org/10.1016/S0140-6736(21)00872-2)
  7. Strobel E. Use of the ID-PaGIA Heparin/PF4 Antibody Test as a screening test for heparin/platelet factor 4 antibodies. Blood Transfus. 2017;15(3):268-271.  
<https://doi.org/10.2450/2016.0302-15>
  8. <https://www.ema.europa.eu/en/news/astrazenecas-COVID-19-vaccine-ema-finds-possible-link-very-rare-cases-unusual-blood-clots-low-blood> (accessed, Maj 5, 2021)
  9. <https://www.fda.gov/emergency-preparedness-and-response/coronavirus-disease-2019-COVID-19/janssen-COVID-19-vaccine> (accessed, Maj 5, 2021)