

# Pulmonary embolism, transient ischaemic attack and thrombocytopenia after the Johnson & Johnson COVID-19 vaccine

Bilal Malik <sup>1</sup>, Atefeh Kalantary,<sup>1</sup> Kamal Rikabi,<sup>1</sup> Arvind Kunadi<sup>2</sup>

<sup>1</sup>Internal Medicine, McLaren Health Care Corp/ MSU, Flint, Michigan, USA

<sup>2</sup>Nephrology/ Internal Medicine, McLaren Health Care Corp/ MSU, Flint, Michigan, USA

## Correspondence to

Dr Bilal Malik;  
Bilal.Malik@mclaren.org

Accepted 25 June 2021

## SUMMARY

As with past illnesses, an approach has been taken to vaccinate the population and halt the spread of COVID-19. On 13 April 2021, the US Food and Drug Administration called for a halt in the administration of the Johnson & Johnson (J&J) COVID-19 vaccine due to reports of thrombosis and thrombocytopenia being associated with vaccination. We present the case of a 43-year-old woman with a history of dyslipidaemia, depression, gastro-oesophageal reflux disease and obesity presenting with dyspnoea, headache and light headedness of 3 days' duration. Ten days prior, she had received the J&J COVID-19 vaccine. She was found to have thrombocytopenia, elevated D-dimers, pulmonary emboli and presented 1 day after discharge with an arterial clot despite being on apixaban. Six other US-based cases of venous thrombotic events are being reviewed at present. Patients should be informed of the possibility of such events to provide informed consent.

## BACKGROUND

On 12 April 2021, the Advisory Commission on Immunisation Practices (ACIP) convened to review the serious complications experienced by six patients after taking the Johnson and Johnson (J&J) COVID-19 vaccination. The US Food and Drug Administration (FDA) and Centers for Disease Control and Prevention (CDC) jointly recommended a pause in the utilisation of the J&J vaccine pending further review.<sup>1,2</sup> Interestingly, all six patients who were reported in the above citations had experienced cerebral venous sinus thrombosis (CVST), were Caucasian females between the ages of 18 and 40 years old, and were found to be thrombocytopenic.<sup>2,3</sup> Scully *et al*<sup>4</sup> identified a similar trend with the AstraZeneca COVID-19 vaccine, whereby 23 patients developed CVST and thrombocytopenia within 1 week of vaccine uptake.<sup>4</sup> During the evaluation of the AstraZeneca vaccine, the UK Medicines and Healthcare Products Regulatory Agency (MHRA) and European Medicine Agency (EMA) both concluded that the thrombotic risk associated with vaccine uptake was not elevated relative to the risk in the general population.<sup>4</sup>

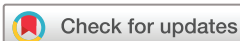Despite the acknowledgement of the possibility of thrombotic events as rare adverse events associated with such vaccines, the above agencies have emphasised the benefits outweighing the risks given the COVID-19 pandemic.<sup>4</sup> Similar conclusions have been drawn based on the US FDA, CDC and

EMA assessments on 20–25 April 2021, where they concluded that benefits outweighed the risks, warnings were to be added to the product information for the vaccines, and administration was to be resumed.<sup>5–7</sup> Additionally, the manufacturer of the J&J vaccine has also released a direct response to the authors of the case report titled, 'Thrombotic Thrombocytopenia after Ad26.COV2.S Vaccination',<sup>8</sup> stating that they did have a single case of CVST and thrombocytopenia during their clinical trial programme in which 50 000 patients received the active vaccine.<sup>9</sup> The adverse event was investigated at that point in time as well, resulting in no explicit causal relationship being established.<sup>9</sup> Of note, however, was the platelet factor 4 (PF4) positivity in the patient in question, which was also identified in other patients experiencing this entity. The authors also made a point of highlighting the incidence of CVST as rare (0.2–1.57 per 100 000 person-years) and the cases occurring with the AstraZeneca vaccine as 'within the range of the background incidence of CVST'.<sup>9</sup>

Today, we present the case of a 43-year-old Caucasian woman with no known history or predisposition for thrombosis. She had received the J&J vaccine and was discovered to have thrombocytopenia and a pulmonary embolism (PE) on CT scanning 10 days later. She was initially thought to have CVST based on a CT angiogram of the head and neck performed due to complaints of headaches and light headedness. This was later clarified to be a chorionic granulation as evidenced on MRI of the head and neck. She was managed in the intensive care unit with intravenous immunoglobulin (IVIG) and fondaparinux (Arixtra). Ultimately, she was discharged on oral anticoagulation with a non-heparin agent but did return 1 day later due to a suspected stroke-like episode where she experienced facial and right upper limb numbness and tingling. The cases mentioned in the ACIP, FDA and CDC reports all experienced CVST and thrombocytopenia. This is the first case, to the best of our knowledge, with a J&J vaccine recipient developing PE, thrombocytopenia, and a subsequent arterial clot despite being on anticoagulation. With an incidence of 0.87 per million vaccines administered, based on available data, the question of how concerning these findings arises in an already uncertain landscape.

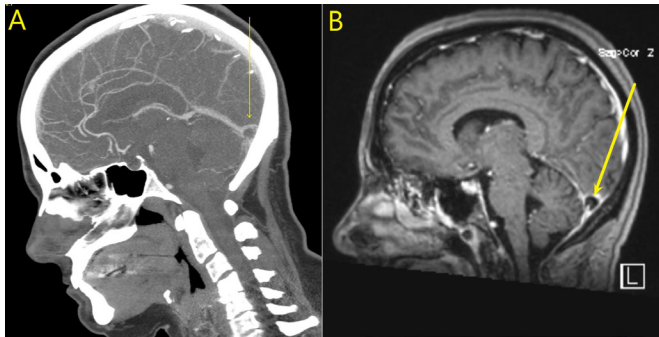
## CASE PRESENTATION

Our patient is a 43-year-old Caucasian woman with a history of hyperlipidaemia, anxiety, depression,



© BMJ Publishing Group Limited 2021. No commercial re-use. See rights and permissions. Published by BMJ.

**To cite:** Malik B, Kalantary A, Rikabi K, *et al*. *BMJ Case Rep* 2021;**14**:e243975. doi:10.1136/bcr-2021-243975

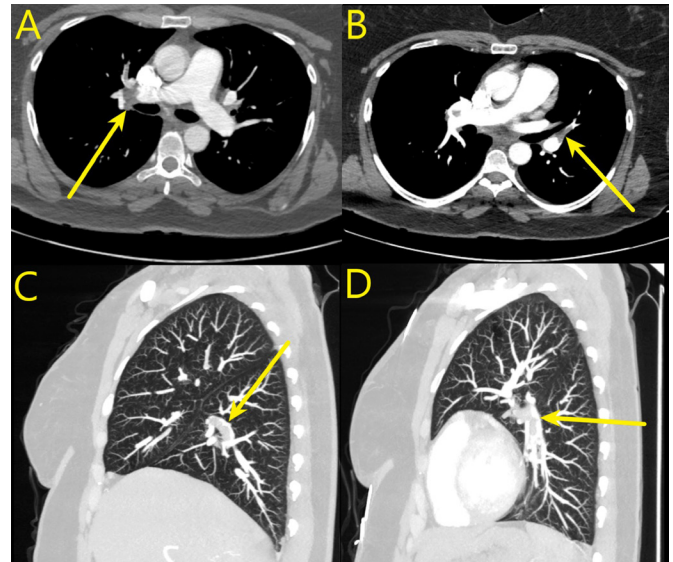


**Figure 1** Left (A): CT angiography of the head and neck demonstrating a filling defect in the confluence of the venous sinus. Right (B): MRI of the brain demonstrating the same, further delineating the lesion as an arachnoid granulation. Yellow arrows: Identify the lesion in both images.

obesity, obstructive sleep apnoea and gastro-oesophageal reflux disease who presented to the emergency department with a 3-day history of generalised headache, fever, body aches, chills, mild dyspnoea and lightheadedness. Approximately 10 days before her presentation, she received the J&J COVID-19 vaccine. She reported a maximum temperature of 103.8°F. She decided to seek evaluation due to the progressive nature of her headache, which had become unbearable to the patient at the time of her evaluation. CT angiography of her head and neck was performed and significant for a low-density rounded filling defect in the venous sinus confluence, worrisome for CVST (figure 1A). Complete blood count (CBC) and basic metabolic profile (BMP) were performed at this time and significant for thrombocytopenia with platelets of  $27000 \times 10^9/L$ . COVID-19 testing was negative. At this point, the patient was transferred to our facility for further workup and management.

On arrival, an MRI of the head was performed for further evaluation of the filling defect. MRI revealed a focal filling defect in the region of the sinus confluence, characterising it as the typical appearance for an arachnoid granulation (figure 1B). No intracranial haemorrhage or mass lesion was present on MRI. Vital signs were stable with a blood pressure of 124/80 mm Hg, heart rate of 65 beats/min, a temperature of 37.9°C, a respiratory rate of 20 breaths/min and an oxygen saturation of 96% on room air. On respiratory examination, the patient had good air entry bilaterally with no wheezing throughout the lung fields and no crackles at the lung bases. Neurological examination was within normal limits, with no focal motor or sensory deficits. Further laboratory evaluation was performed, and her D-dimer came back elevated at 35.20 mg/L. She denied any use of nicotine products or hormonal medications (hormone replacement therapy or oral contraceptive pills). Doppler images of bilateral upper and lower extremities were negative for any evidence of deep vein thrombosis (DVT). In conjunction with her dyspnoea, her elevated D-dimer prompted evaluation for a PE with CT pulmonary angiogram, which turned out positive for right upper lobe, right lower lobe, and left lower lobe lobar and segmental pulmonary emboli (figure 2).

Haematology was consulted for further workup of an underlying hypercoagulable condition. The patient denied any history of having experienced a blood clot in the past or any significant contributory family history. Given the call for pausing administration of the J&J vaccine just 1 week prior and the recent thrombotic complications with the AstraZeneca vaccine, the patient was given a dose of 60 g of IVIG and started on 7.5 mg



**Figure 2** CT angiography of the lungs. (A, C) Right pulmonary artery demonstrating emboli. (B, D) Left pulmonary artery demonstrating emboli. Yellow arrows point out filling defects (emboli) in each respective area.

of subcutaneous fondaparinux daily thereafter, with particular caution to avoid heparin products. Her pain was managed with as-needed fioricet (butalbital-acetaminophen-caffeine) and scheduled topiramate. Table 1 displays the results from an extensive haematologic workup. Of note, she was ultimately positive for PF4 antibody, anti-nuclear antibody (ANA) and slide review/peripheral smear significant for thrombocytopenia with increased mean platelet volume and platelet insufficiency. She received two total doses of 60 g of IVIG, which did successfully improve her platelet count to  $132 \times 10^3/\mu L$  over her 6-day admission. On discharge, she was prescribed apixaban 5 mg orally, two times per day for anticoagulation, and fioricet and topiramate for cephalalgia. Ultimately, there was no alternative explanation available besides her recent exposure to the J&J COVID-19 vaccination as the inciting event in the cascade of events that led up to her hospitalisation.

#### OUTCOME AND FOLLOW-UP

Unfortunately, 1 day after discharge, the patient presented with numbness and tingling of her face and right arm and was evaluated for a possible stroke with MRI brain without contrast, CT angiogram of the head and CT head without contrast. MRI and CT of the head without contrast were negative for any intracranial processes, but CT angiogram of the head and neck was positive for a non-occlusive right internal carotid artery (ICA) thrombus in the right carotid bulb/proximal right ICA. It measured 1.5 cm in the craniocaudal dimension (figure 3). The patient was diagnosed with a transient ischaemic attack (TIA) and admitted for further management. She is presently still living and was discharged home on fondaparinux 7.5 mg subcutaneously, once a day, for 1 month and is to be transitioned to apixaban 5 mg orally, two times per day, for 5 months, totalling 6 months of anticoagulant therapy. She will be followed up as an outpatient by her haematologist and primary care physician for further management.

#### DISCUSSION

The continued efforts to control the COVID-19 pandemic have led to the approval of multiple vaccines across the globe including

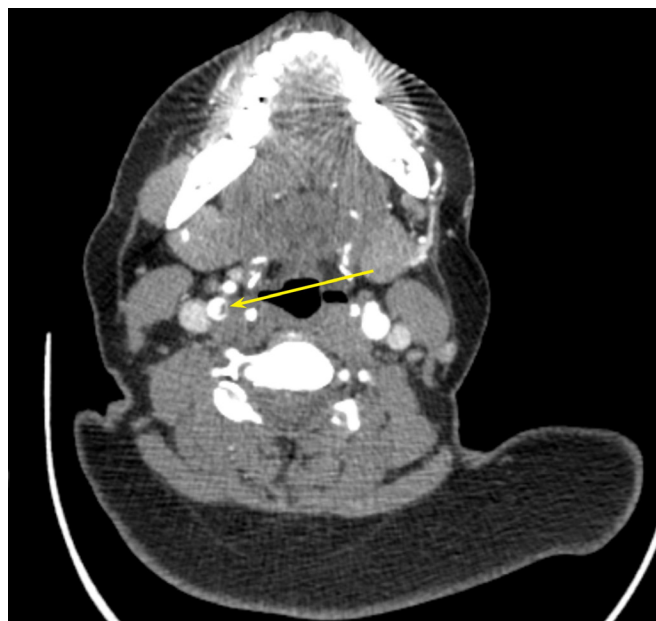**Table 1** Summary table outlining the workup performed to rule out underlying thrombotic disorders

Test	One-time tests	On admission	On discharge	On readmission
COVID-19 (Rapid Abbott)	–	Negative	–	Negative
Prothrombin Time (PT) (s)	–	12.2	–	–
Activated Partial Thromboplastin Time (aPTT) (s)	–	26.4	–	–
International Normalized Ratio (INR)	–	1.13	–	–
Fibrinogen (mg/dL)	–	142	–	–
Platelets ( $\times 10^3/\mu\text{L}$ )	–	21	132	168
Slide review	–	Decreased platelet sufficiency	Decreased platelet sufficiency	–
D-dimer (mg/L)	–	>35.20	–	–
White Blood Cell Count (WBC) ( $\times 10^3/\mu\text{L}$ )	–	7.14	5.77	6.14
Rheumatoid factor (IU/mL)	9	–	–	–
Anti-DS DNA	Negative	–	–	–
Anti-Smith antibody	Negative	–	–	–
Cardiolipin IgA/G/M (U/mL)	0.7/<1.6/1.8	–	–	–
Factor V Leiden mutation	Negative	–	–	–
Peripheral smear	Thrombocytopenia with high mean platelet volume (MPV)	–	–	–
Lactate Dehydrogenase (LDH) (U/L)	–	233	–	–
Indirect Coombs	Negative	–	–	–
Blood type ABO/Rh	O positive	–	–	–
anti-nuclear antibody (ANA)	Positive	–	–	–
Prothrombin factor II 20210G>A mutation	Negative	–	–	–
Antithrombin III activity	143 %	–	–	–
Antithrombin III antigen	113%	–	–	–
Protein C activity	113%	–	–	–
Protein C antigen	117%	–	–	–
Protein S activity	88%	–	–	–
Protein S antigen	113%	–	–	–
Hexagonal phospholipids	Negative	–	–	–
Heparin induced platelet Ab (HIT) (PF4 Ab) (Units-OD)	2.702	–	–	–
Platelet Ab direct flow cytometry	Negative	–	–	–
Factor VIII antigen	180%	–	–	–
Lupus inhibitor/anticoagulant	Negative, test suggestive of heparin effect	–	–	–
Creatinine (mg/dL)	–	0.8	0.8	0.87
Troponin I (ng/mL)	–	0.003	–	0.1070

PF4, platelet factor 4.

the Pfizer (BNT162b2mRNA), Moderna (mRNA-1273), J&J (Ad26.COV2.S) and AstraZeneca (AZD1222) vaccines. Multiple countries have reported a series of rare thromboembolic incidents, most commonly CSVT or DVT of the lower limbs, associated with thrombocytopenia and occurring 7–14 days after vaccination with certain COVID-19 vaccines.<sup>10</sup> These adverse events have led many countries, including Germany and the USA, to temporarily pause the administration of the vaccines in question to further investigate these cases.

CVST is a rare condition that affects 0.22–1.57 per 100 000 population annually and accounts for approximately 0.5%–1% of all strokes per year.<sup>9</sup> The median age of patients presenting with CVST is 37 years old and approximately 8% of patients are 65 years of age or older at the time of diagnosis. Multiple identifiable risk factors have been identified, including prothrombotic conditions (inherited or acquired), use of hormone therapy (including oral contraceptive pills), pregnancy and the post-partum period, malignancy, infection and mechanical precipitants (lumbar punctures). As of 12 April 2021, there have been

**Figure 3** CT angiogram demonstrating partially occlusive thrombus in the right internal carotid artery (yellow arrow).

six reported cases of CVST associated with thrombocytopenia (platelet counts  $<150\,000/\text{mm}^3$ ) within the USA after the administration of approximately 6.86 million doses of the J&J COVID-19 vaccination.<sup>9</sup>

The pathophysiological mechanism underlying these events has been termed vaccine-induced immune thrombotic thrombocytopenia (VITT) (now termed ‘thrombosis with thrombocytopenia syndrome (TTS)’ by the US FDA and CDC in a recent update).<sup>11</sup> It mimics heparin-induced thrombocytopenia (HIT) with a positive platelet-activating antibody to platelet-factor 4 (PF4 Ab)/heparin complexes, thrombocytopenia and a predisposition to forming thrombi. The mechanism is thought to be emulated by polyanionic constituents of the AZD1222 (AstraZeneca) vaccination.<sup>10</sup> The exact mechanism behind these adverse events in the J&J vaccination is thought to be similar to the process described for the AZD1222 vaccination.<sup>12</sup> The American Society of Hematology presented VITT/TTS as a medical entity in April 2021. The diagnostic criteria included (1) COVID-19 vaccination (AstraZeneca or J&J) within 4–30 days prior, (2) thrombosis (often cerebral or abdominal), (3) thrombocytopenia, (4) positive PF4 HIT ELISA.<sup>11</sup> All four criteria need to be met to qualify for the diagnosis, as in our patient. An additional finding unique to our patient in comparison to the six cases published in the article by See *et al*<sup>13</sup> was the development of TIA (arterial thrombus) 1 day after discharge, despite being on apixaban. Arterial thrombus formation itself is a rare phenomenon and our patient did not have any predisposing factors present at the time of assessment. Likely, her TIA and associated arterial thrombus were also associated with her hypercoagulable state, attributed herein to the uptake of the vaccination just 10 days prior.

No definitive treatment has been established thus far but the research conducted by von Hundelshausen *et al* suggested plasma exchange with plasma rather than albumin is an effective way of reducing the pathologic antibody load in the serum and providing correction of the hypofibrinogenemia.<sup>10</sup> In the same research, von Hundelshausen *et al* proposed an alternative treatment for TTS by using Bruton tyrosine kinase (Btk) inhibitors. Btk inhibitors are currently approved for B-cell malignancies

and act to pleiotropically target multiple pathways downstream of the gamma Fc receptor IIa (FcγRIIA). They have been demonstrated to effectively inhibit platelet aggregation, dense granule secretion, P-selectin expression and platelet-neutrophil aggregate formation stimulated by FcγRIIA cross-linking.<sup>10</sup> Moreover, platelet C-type lectin-like receptor-2 (CLEC-2) and glycoprotein Ib-mediated platelet activation, interaction and activation of monocytes and the release of neutrophil extracellular traps (as encountered in HIT) are also attenuated by Btk inhibitors.<sup>10</sup>

Despite the significant thrombocytopenia that can be encountered with these patients, the avoidance of platelet transfusions is critical. Additional platelets would provide a substrate for further antibody-mediated platelet activation and coagulopathy.<sup>10</sup> Since TTS mimics HIT (ie, it is PF4 Ab positive) and it is a hypercoagulable state, anticoagulation with a non-heparin anticoagulant, such as argatroban, danaparoid, fondaparinux or direct oral anticoagulants, is recommended.<sup>4</sup> Further workup to evaluate for alternative aetiologies of hypercoagulability or underlying procoagulant disorders, including thrombotic-thrombocytopenic purpura, atypical haemolytic uremic syndrome and antiphospholipid syndrome, should be performed before diagnosing TTS.<sup>14</sup> An alternative diagnosis could significantly impact management decisions. Physicians should have a low threshold for further evaluation in patients who recently received the J&J COVID-19 vaccine (ie, within 4–30 days) and present with signs/symptoms of thrombosis (DVT, CVST, intra-abdominal). Anticoagulation should be considered as detailed above.

### Patient's perspective

I felt like I had a stroke and that I might die. I did not feel safe at home because I thought to myself that anything could happen at any time. I was frustrated that in taking a step to safeguard myself against COVID-19, I experienced so many other complications. I am thankful to be alive, but even if I had to take the vaccine again I would do it in view of the risk that COVID-19 poses.

### Learning points

- ▶ Consider thrombosis with thrombocytopenia syndrome (TTS) as part of the differential diagnosis in a patient presenting with thrombosis (cerebral venous sinus thrombosis, deep vein thrombosis, pulmonary embolism) within 30 days of receiving AstraZeneca or Johnson & Johnson COVID-19 vaccines.
- ▶ Use the four criteria as outlined by the American Society of Hematology to diagnose TTS.
- ▶ In the appropriate clinical situation where the clinician's suspicion for TTS is high and there are no absolute contraindications, use non-heparin anticoagulants to anticoagulate the patient.
- ▶ Provide patients with information regarding the possibility of experiencing thrombotic events during the process of shared decision-making regarding vaccination.

**Contributors** BM, A Kalantary and KR contributed equally in the researching, writing and editing of the manuscript. A Kunadi supervised the project and made significant changes to the final manuscript. All authors were in agreement with the finalised manuscript to be submitted for publication. All authors agreed to be accountable for all aspects of the work in ensuring that questions related to the accuracy or integrity of any part of the manuscript are appropriately investigated and resolved.

**Funding** The authors have not declared a specific grant for this research from any funding agency in the public, commercial or not-for-profit sectors.

**Competing interests** None declared.

**Patient consent for publication** Obtained.

**Provenance and peer review** Not commissioned; externally peer reviewed.

This article is made freely available for use in accordance with BMJ's website terms and conditions for the duration of the covid-19 pandemic or until otherwise determined by BMJ. You may use, download and print the article for any lawful, non-commercial purpose (including text and data mining) provided that all copyright notices and trade marks are retained.

### ORCID iD

Bilal Malik <http://orcid.org/0000-0001-8762-7321>

### REFERENCES

- 1 Acpiinternist.org. Clot concerns with adenovirus COVID-19 vaccines, antibody treatment recommendations and data [Internet], 2021. Available: [https://acpiinternist.org/weekly/archives/2021/04/20/1.htm?utm\\_campaign=FY20-21\\_NEWS\\_INTERNICIST\\_DOMESTIC\\_042021\\_EML&utm\\_medium=email&utm\\_source=Eloqua](https://acpiinternist.org/weekly/archives/2021/04/20/1.htm?utm_campaign=FY20-21_NEWS_INTERNICIST_DOMESTIC_042021_EML&utm_medium=email&utm_source=Eloqua)
- 2 Shimabukuro T. ACIP April 14, 2021 Presentation Slides | Immunization Practices | CDC [Internet], 2021. Available: <https://www.cdc.gov/vaccines/acip/meetings/slides-2021-04.html>
- 3 Schuchat A, Marks P. Joint CDC and FDA Statement on Johnson & Johnson COVID-19 Vaccine [Internet], 2021. Centers for disease control and prevention. Available: <https://www.cdc.gov/media/releases/2021/s0413-JJ-vaccine.html>
- 4 Scully M, Singh D, Lown R, et al. Pathologic antibodies to platelet factor 4 after ChAdOx1 nCoV-19 vaccination. *N Engl J Med* 2021;384:2202–11.
- 5 European Medicines Agency. COVID-19 Vaccine Janssen: EMA finds possible link to very rare cases of unusual blood clots with low platelets - European Medicines Agency [Internet], 2021. Available: <https://www.ema.europa.eu/en/news/covid-19-vaccine-janssen-ema-finds-possible-link-very-rare-cases-unusual-blood-clots-low-blood>
- 6 Johnson & Johnson. Johnson & Johnson COVID-19 Vaccine Roll-out to Resume in Europe Following European Medicines Agency (EMA) Review, EMA Confirms Overall Benefit-Risk Profile Remains Positive [Internet], 2021. Available: <https://www.jnj.com/johnson-johnson-covid-19-vaccine-roll-out-to-resume-in-europe-following-european-medicines-agency-ema-review-ema-confirms-overall-benefit-risk-profile-remains-positive>
- 7 Centers for Disease Control and Prevention. CDC Recommends Use of Johnson & Johnson's Janssen COVID-19 Vaccine Resume [Internet], 2021. Available: <https://www.cdc.gov/coronavirus/2019-ncov/vaccines/safety/JJUupdate.html>
- 8 Muir K-L, Kallam A, Koepsell SA, et al. Thrombotic thrombocytopenia after Ad26.COV2.S vaccination. *New England Journal of Medicine* 2021;384:1964–5.
- 9 Sadoff J, Davis K, Douoguih M. Thrombotic Thrombocytopenia after Ad26.COV2.S Vaccination - Response from the Manufacturer. *N Engl J Med* 2021;384:1965–6.
- 10 von Hundelshausen P, Lorenz R, Siess W, et al. Vaccine-Induced immune thrombotic thrombocytopenia (VITT): targeting pathomechanisms with Bruton tyrosine kinase inhibitors. *Thromb Haemost* 2021. doi:10.1055/a-1481-3039. [Epub ahead of print: 13 Apr 2021].
- 11 et al Bussell J, Connors J, Cines D. Thrombosis with Thrombocytopenia Syndrome [Internet]. Hematology.org, 2021. Available: <https://www.hematology.org/covid-19/vaccine-induced-immune-thrombotic-thrombocytopenia>
- 12 Greinacher A, Thiele T, Warkentin TE, et al. Thrombotic thrombocytopenia after ChAdOx1 nCov-19 vaccination. *N Engl J Med* 2021;384:2092–101.
- 13 See I, Su JR, Lale A, et al. US case reports of cerebral venous sinus thrombosis with thrombocytopenia after Ad26.COV2.S vaccination, March 2 to April 21, 2021. *JAMA* 2021;325:2448.
- 14 Oldenburg J, Klamroth R, Langer F. Diagnosis and management of vaccine-related thrombosis following AstraZeneca COVID-19 vaccination: guidance statement from the GTH. *Hamostaseologie* 2021. doi:10.1055/a-1469-7481

Copyright 2021 BMJ Publishing Group. All rights reserved. For permission to reuse any of this content visit <https://www.bmj.com/company/products-services/rights-and-licensing/permissions/>  
BMJ Case Report Fellows may re-use this article for personal use and teaching without any further permission.

Become a Fellow of BMJ Case Reports today and you can:

- ▶ Submit as many cases as you like
- ▶ Enjoy fast sympathetic peer review and rapid publication of accepted articles
- ▶ Access all the published articles
- ▶ Re-use any of the published material for personal use and teaching without further permission

#### **Customer Service**

If you have any further queries about your subscription, please contact our customer services team on +44 (0) 207111 1105 or via email at [support@bmj.com](mailto:support@bmj.com).

Visit [casereports.bmj.com](http://casereports.bmj.com) for more articles like this and to become a Fellow