

Reported adverse effects following COVID-19 vaccination at a tertiary care hospital, focus on cerebral venous sinus thrombosis (CVST)

Laila Carolina Abu Esba & Majed Al Jeraisy

To cite this article: Laila Carolina Abu Esba & Majed Al Jeraisy (2021) Reported adverse effects following COVID-19 vaccination at a tertiary care hospital, focus on cerebral venous sinus thrombosis (CVST), *Expert Review of Vaccines*, 20:8, 1037-1042, DOI: [10.1080/14760584.2021.1940145](https://doi.org/10.1080/14760584.2021.1940145)

To link to this article: <https://doi.org/10.1080/14760584.2021.1940145>



© 2021 The Author(s). Published by Informa UK Limited, trading as Taylor & Francis Group.



Published online: 17 Jun 2021.



Submit your article to this journal [↗](#)



Article views: 3979



View related articles [↗](#)



View Crossmark data [↗](#)

Reported adverse effects following COVID-19 vaccination at a tertiary care hospital, focus on cerebral venous sinus thrombosis (CVST)

Laila Carolina Abu Esba^{a,b,c} and Majed Al Jeraisy^{a,b,c}

^aPharmaceutical Care Services, Ministry of the National Guard – Health Affairs, Riyadh, Saudi Arabia; ^bKing Abdullah International Medical Research Center, Riyadh, Saudi Arabia; ^cCollage of Pharmacy, King Saud Bin Abdulaziz University for Health Sciences, Riyadh, Saudi Arabia

ABSTRACT

Objectives: Several cases of unusual thrombotic events with thrombocytopenia were reported in several countries, in association with AstraZeneca's COVID-19 vaccine. The European medicines agency conducted a detailed review and concluded that there was no evidence to suggest an association of thrombotic events with the use of COVID-19 vaccine AstraZeneca.

Methods: King Abdulaziz Medical City is a 1500 bed tertiary care hospital in Riyadh, Saudi Arabia; this study describes spontaneously reported vaccine adverse effects received through the hospital's internal electronic safety reporting system from December 2020 to 13 April 2021.

We assessed each report for causality association utilizing the world health organization's (WHO) causality assessment of an adverse event following immunization (AEFI) classification 2nd Edition 2019.

Results: The majority of the reported events were mild to moderate, there were five serious events, one reported cardiac arrest, two cerebral venous sinus thrombosis, and two pulmonary embolism. Clinical and laboratory summary of the five patients are presented in detail.

Conclusions: Efforts of pharmacovigilance in mediating the rare risk of thrombosis associated with COVID-19 vaccine are crucial in providing awareness on the possible risk factors and signs/symptoms that should raise red flags.

ARTICLE HISTORY

Received 29 April 2021
Accepted 4 June 2021

KEYWORDS

COVID-19 vaccine; adverse effect; AstraZeneca COVID-19 vaccine; CVST; pharmacovigilance

1. Introduction

The Saudi Food and Drug Authority (SFDA) has approved two vaccines against coronavirus disease 2019 (COVID-19), Pfizer–BioNTech a messenger RNA–based vaccines, and COVID-19 vaccine AstraZeneca that encodes the spike protein antigen of SARS-CoV-2, encapsulated in lipid nanoparticles.

More than 6 million vaccine doses have been administered in Saudi Arabia up until 13 April 2021, representing approximately 8.9% of the country's population [1].

Early March 2021, several cases of unusual thrombotic events in combination with thrombocytopenia were reported in several European countries, in association with AstraZeneca's vaccine. Several countries including Austria and Denmark decided to suspend vaccination with COVID-19 vaccine AstraZeneca until further analysis of the reported cases were conducted by the drug regulatory authorities [2].

On 24 March 2021, the pharmacovigilance risk assessment committee of the European medicines agency (EMA) conducted a detailed review of the reported cases in Europe and the United Kingdom and concluded that there was no evidence to suggest an association of thrombotic events with the use of COVID-19 vaccine AstraZeneca. However, they did report that a signal was noted for rare events that would need further investigation, namely disseminated intravascular coagulation, cerebral venous sinus thrombosis (CVST), and hemorrhagic stroke [2].

With all the misinformation and promoted therapies that have shown to be ineffective in the battle against COVID-19 such as the use of hydroxychloroquine and lopinavir-Ritonavir, COVID-19 vaccines will remain an important tool in fighting this pandemic and alleged or exaggerated reports on their safety may play a role in increasing vaccine hesitancy. Here we describe the vaccine adverse effects reported at one of the largest hospitals in Riyadh, Saudi Arabia.

2. Method

King Abdulaziz Medical City is a 1500 bed tertiary care hospital in Riyadh, Saudi Arabia; this study describes spontaneously reported vaccine adverse effects received through the hospital's internal electronic safety reporting system from December 2020 to 13 April 2021.

All reports were included for analysis and the following information was extracted for each report: date reported, age and sex of the patient, comorbidities, the description of the adverse effect, type of COVID-19 vaccine and number of doses received, the time between dose and reaction, and outcome.

We describe in detail the case series of serious adverse effects reported including clinical/laboratory data available for those patients.

We assessed each report for causality association utilizing the world health organization's (WHO) causality assessment of

an adverse event following immunization (AEFI) classification 2nd Edition 2019, which is classified into (A) vaccine product-related reaction, (B) intermediate, and (C) coincidental (see [Figure 1](#) for full classification definition) [3].

The institutional review board (IRB) and ethical committee at King Abdullah International Medical Research Center (KAIMRC) (protocol RC21R/142/04) approved this study. Consent was not required by IRB due to retrospective design, and patients were treated during routine clinical practice.

3. Results

There were a total of 14 adverse effects related to COVID-19 vaccines reported through the hospital's reporting system up to and including 13 April 2021. In eight of the reports the type of COVID-19 vaccine administered was not reported, four were related to AstraZeneca, and two were related to Pfizer-BioNTech COVID-19 vaccine.

Among these patients, the median age was 30 years (range, 23–61); and 8 of 14 were women.

3.1. Non-serious adverse effects reported

The majority of the reported events were mild to moderate (9/14), and occurred within 24 h post vaccination. The most frequently reported were fever, fatigue, general body ache, epigastric pain, shortness of breath, and headache.

There were two patient-reported syncope events, both patients were stable and discharged after their emergency room (ER) visit.

Outcome: None of these events resulted in hospitalization, or required further treatments and no further visits were documented in these patient's records.

WHO-causality assessment result: all nine reactions were (A1) consistent causal association to immunization, vaccine product-related reaction.

3.2. Serious adverse effects reported

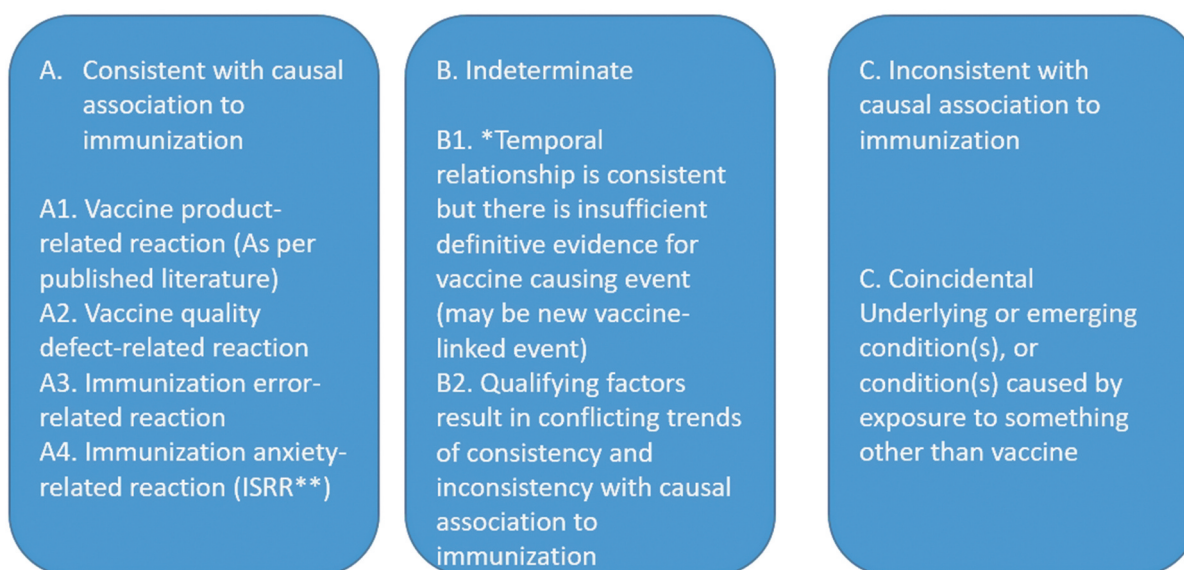
Up to and including 13 April 2021, there were 5/14 serious events, 1 reported cardiac arrest that resulted in death that occurred after the administration of a COVID-19 vaccine. The remaining four serious adverse reports included the following thrombotic events: CVST (in two patients), and pulmonary embolism (in two patients). Clinical and laboratory summary of the five patients are presented in [Table 1](#).

3.3. Description of the serious cases

Patient 1, a cardiac arrest in a 38-year-old male, who had taken COVID-19 vaccine (type unknown) at 9 a.m. in the morning, and was found unresponsive at around 8 p.m. of the same day. Emergency medical services arrived and cardiopulmonary resuscitation was initiated, a couple of cycles in the ambulance were done, but the patient was announced dead on arrival to the hospital. The patient was not a KAMC eligible patient so no medical records were available. The person accompanying the patient gave a vague history of a cardiac surgery done a couple of years back. No further laboratory investigations were conducted.

WHO-causality assessment result: (B1) Temporal relationship is consistent but there is insufficient definitive evidence that vaccine caused the event (it may be a new vaccine-linked event).

Patient 2, a 61-year-old female with multiple comorbidities (diabetes, hypertension, heart failure, and chronic obstructive pulmonary disease), she complained of diarrhea with immediate onset post COVID1-19 vaccine (type unknown). A few days



*B1 : Potential signal and maybe considered for investigation

** Immunization stress related response

Table 1. Clinical and laboratory summary of the patients with serious adverse effects

Characteristics	Patient 1	Patient 2	Patient 3	Patient 4	Patient 5
Age (years)	38	61	61	40	27
Sex	Male	Female	Female	Male	Male
Type of vaccine received	NS	NS	AstraZeneca	AstraZeneca	Pfizer
Number of vaccine doses received	NS	Second dose	NS	First dose	Second dose
Comorbidities	NS	DM, HTN, HF, COPD	DM, HTN, DLP, high liver enzymes	None	None
Smoking	NS	No	No	Yes	Yes
Time from vaccination to presentation (days)	Same day	9	14	14	6
Type of adverse effect	Cardiac arrest	Seizure and PE	CVST	CVST	PE
Platelet count on admission	Not done	315 x 10 ⁹ /L	143 x 10 ⁹ /L	128 x 10 ⁹ /L	206 x 10 ⁹ /L
HIT screen test	Not done	Not done	Not done	Negative	Not done
Anticoagulation treatment	None	Heparin followed by enoxaparin	Enoxaparin	Enoxaparin followed by apixaban	Enoxaparin followed by apixaban
WHO- causality	B1	B2	B1	A1	B2
Outcome	Fatal	Still hospitalized	Discharged	Discharged	Discharged

Abbreviations: aPTT: activated partial thromboplastin time, CVST: cerebral venous sinus thrombosis, INR: international normalized ratio, LMWH low-molecular-weight heparin. NS: not specified, PE: pulmonary embolism.

later, she was brought to the ER with decrease in level of consciousness, and was admitted due to multiple episodes of seizures and pulmonary embolism. This patient remained admitted at the time of submitting this report, she is in a stable condition, alert and conscious.

WHO-causality assessment result: (B2) Indeterminate, reviewing factors result in conflicting trends of consistency and inconsistency with causal association to immunization (i.e. it may be vaccine-associated as well as coincidental and it is not possible clearly to favor one or the other)

Patient 3 was a 61-year-old female with multiple comorbidities (diabetes, hypertension, dyslipidemia). She presented to ER with one-week history of unexperienced before left ear pain, headache, dizziness, nausea, and tinnitus that started two weeks after her first AstraZeneca COVID-19 vaccine dose, she was treated with analgesics and discharged. A few days later she was brought again to ER as she was disoriented, confused, and complained of eye pain and impaired vision, a brain CT showed CVST; a complete thrombosis of the left transverse sinus extending to the left sigmoid sinus and jugular vein. Platelet count was $143 \times 10^9/L$ on admission, pan CT showed no malignancies. She was treated with enoxaparin and discharged 7 days later with a national institutes of health stroke scale (NIHSS) score of 8.

WHO-causality assessment result: (B1) Indeterminate, temporal relationship is consistent but there is insufficient definitive evidence that vaccine caused the event (it may be a new vaccine-linked event). This is a potential signal and needs to be considered for further investigation.

Patient 4, a 40-year-old male with no past medical history, he received his first AstraZeneca COVID-19 vaccine dose and two weeks later presented to the ER with severe headache and nausea, he was treated with analgesics and discharged. He then presented two days later with worsening headache, a brain CT showed CVST. Platelet on admission was $128 \times 10^9/L$, heparin-induced thrombocytopenia test was negative, protein S deficiency (54.3%), functional protein C activity (146.4%). He was treated with enoxaparin for 3 days then discharged in a good condition on apixaban.

WHO-causality assessment result: (A1) consistent causal association to immunization, vaccine product-related reaction.

Patient 5, a 27 year-old male, with no past medical history, heavy smoker presented to the ER with chest pain and chest CT showed pulmonary embolism, he had received his second dose of Pfizer COVID-19 vaccine 2 days before presentation. He was treated with enoxaparin and discharged in a stable condition on apixaban.

WHO-causality assessment result: (B2) Indeterminate, reviewing factors result in conflicting trends of consistency and inconsistency with causal association to immunization (i.e. it may be vaccine-associated as well as coincidental and it is not possible clearly to favor one or the other)

4. Discussion

CVST is considered a rare type of thrombosis, hence the concern with the reported events post COVID-19 vaccination, the incidence has been reported to vary between

studies but lies in the range of 2–15.7 cases per million individuals [4–6].

In Saudi Arabia, the incidence seems low and resembles the incidence reported in other countries, taking into consideration the likelihood that the true incidence is underestimated due to lack of well-designed epidemiological studies. One study from king Abdulaziz hospital reported 111 cases over a 20-year period, approximately 5 cases per year and in another study from king Fahad hospital in Riyadh, they reported 22 cases over a 3-year period corresponding to 7 cases per year, reported risk factors included oral contraceptive use and pregnancy [7,8].

A plausible mechanism has been proposed as the clinical picture of thrombocytopenia and unusual sites of thrombosis beginning approximately 1–2 weeks after vaccination suggests a disorder that clinically resembles severe heparin-induced thrombocytopenia which is caused by platelet-activating antibodies [9].

In a recently published case series of patients who developed thrombosis and thrombocytopenia after vaccination with AstraZeneca vaccine in Germany and Austria, 9/11 had CVST, 3/11 splanchnic vein thrombosis and other thrombosis, 6/11 were fatal cases, and 5/11 patients had disseminated intravascular coagulation. The investigators used serum samples of the patients to detect platelet factor 4 (PF4)–heparin antibodies and a modified (PF4-enhanced) platelet-activation test to detect platelet-activating antibodies. Results showed that all patients who tested positive for antibodies against PF4–heparin also tested positive on the platelet-activation assay in the presence of PF4 independent of heparin, additional studies with PF4 or PF4–heparin affinity purified antibodies in two patients confirmed PF4-dependent platelet activation. The authors concluded a causal association between AstraZeneca COVID-19 vaccination and the rare development of immune thrombotic thrombocytopenia mediated by platelet-activating antibodies against PF4, which clinically mimics autoimmune heparin-induced thrombocytopenia [9].

In another case report on CVST in association with COVID-19 vaccine in a healthcare worker, the time frame of onset seems similar to our reported cases and the case series described above [10].

On the other hand, EMA concluded that the benefits of AstraZeneca's COVID-19 vaccination outweighs the risks. Its safety committee has decided however that unusual blood clots with low blood platelets should be listed as very rare side effects of COVID-19 vaccine AstraZeneca [11].

The SFDA formed a committee consisting of a group of experts to evaluate these adverse events reported voluntarily from the vaccinated people through the national application program (Sehaty) and reports from hospitals. On 19 April 2021 the SFDA

Sent a circulation related to the risk of thrombosis associated with COVID-19 vaccine AstraZeneca, they reported that 34 cases of thrombosis and thrombocytopenia were reported in the Kingdom. They also reassured that the benefits of vaccination outweighs the risks. Therefore, vaccination campaigns with both vaccines have continued, though shadowed by public fear about the thrombosis risk circulating in the media and a struggle to make sense of it all [12].

Some countries set specific age restrictions on who should receive the AstraZeneca COVID-19 vaccine EMA elaborates in its report on the limitations of interrupting the age risk group based from the cases reported, mainly highlighting the importance of considering differences between Member States in the age, gender, and prevalence of relevant co-morbidities in populations exposed to the different COVID-19 vaccines [13].

As drug regulatory authorities have decided that vaccination with COVID-19 vaccine AstraZeneca can proceed, and that the package leaflet be updated to list thrombotic events as a very rare adverse effect, it is crucial that clinicians recognize the diagnostic and therapeutic strategies of suspected vaccine-induced immune thrombotic thrombocytopenia. Greinacher et al. published a useful decision tree, and the British society for hematology also published a guidance on syndrome of thrombosis and thrombocytopenia occurring after coronavirus vaccination, this guide provides criteria for diagnosis of definite and unlikely cases and a guide on the management of probable cases [9,14].

While efforts of pharmacovigilance in mediating the rare risk of thrombosis associated with COVID-19 vaccine may arguably increase vaccine hesitancy, it is extremely crucial in providing awareness on the possible risk factors and signs and symptoms that should raise red flags, and continuous surveillance to ensure that the vaccine's benefits remain more than its risks.

In the two CVST cases described above both patients presented with severe headache and were sent home on analgesics, with better awareness of the possible risk of the vaccine causing CVST practitioners can consider it on their differential when patients present with severe headache within two weeks of receiving COVID-19 vaccine AstraZeneca.

Efforts to ensure documentation of the type of vaccine the patient has received, whether adverse effects occurred post first or second dose, and preferably the batch number of the vaccine are important to enable appropriate pharmacovigilance and tracing especially for such rare events.

Evidence on the safety of COVID-19 vaccines continue to emerge, a larger prospective observational studies in a country like United Kingdom with mass vaccination campaigns showed lower frequencies of adverse effects than reported in phase III trials [15]. Real world data in elderly patients have also shown safety and efficacy of both AstraZeneca and Pfizer COVID-19 vaccines [16].

5. Conclusion

Drug regulatory agencies should continue to monitor closely the association of COVID-19 AstraZeneca with CVST and re-evaluate its benefit over its risks as more report emerge.

Declaration of interest

The authors have no relevant affiliations or financial involvement with any organization or entity with a financial interest in or financial conflict with the subject matter or materials discussed in the manuscript. This includes employment, consultancies, honoraria, stock ownership or options, expert testimony, grants or patents received or pending, or royalties.

Reviewer disclosures

Peer reviewers on this manuscript have no relevant financial or other relationships to disclose.

Author Contributions

Both authors contributed to the conception and design of the review article and interpreting the relevant literature, and writing.

References

1. Saudi Arabia: the latest coronavirus counts, charts and maps. *Reuters*, 2021, Accessed 2021 Apr 11. Available from: <https://graphics.reuters.com/world-coronavirus-tracker-and-maps/countries-and-territories/saudi-arabia/>
2. Signal assessment report on embolic and thrombotic events (SMQ) with COVID-19 vaccine (Chadox1-5 [Recombinant]) – COVID-19 vaccine astrazeneca (other viral vaccines). *Ema.Europa.Eu*, 2021, cited 2021 Apr 11. Available from: https://www.ema.europa.eu/en/documents/prac-recommendation/signal-assessment-report-embolic-thrombotic-events-smq-covid-19-vaccine-chadox1-5-recombinant-covid_en.pdf
3. World Health Organization. Causality assessment of an adverse event following immunization (AEFI). In: User manual for the revised WHO Classification. Second ed. Geneva, Switzerland: WHO; 2018.
4. Capecchi M, Abbattista M, Martinelli I. Cerebral venous sinus thrombosis. *J Thromb Haemost*. 2018 Oct;16(10):1918–1931. Epub 2018 Jul 11. PMID: 29923367...
5. Coutinho JM, Zuurbier SM, Aramideh M, et al. The incidence of cerebral venous thrombosis: a cross-sectional study. *Stroke*. 2012 Dec;43(12):3375–3377. Epub 2012 Sep 20. PMID: 22996960.
6. Devasagayam S, Wyatt B, Leyden J, et al. Cerebral venous sinus thrombosis incidence is higher than previously thought: a retrospective population-based study. *Stroke*. 2016 Sep;47(9):2180–2182. Epub 2016 Jul 19. PMID: 27435401.
7. Algahtani HA, Abdu AP, Shami AM, et al. Cerebral venous sinus thrombosis in Saudi Arabia. *Neurosciences (Riyadh)*. 2011 Oct;16(4):329–334. PMID: 21983375.
8. Kajtazi NI, Zimmerman VA, Arulneyam JC, et al. Cerebral venous thrombosis in Saudi Arabia. Clinical variables, response to treatment, and outcome. *Neurosciences (Riyadh)*. 2009 Oct;14(4):349–354. PMID: 21048649.
9. Greinacher A, Thiele T, Warkentin TE, et al. Thrombotic thrombocytopenia after ChAdOx1 nCov-19 vaccination. *N Engl J Med*. 2021 Apr 9. Epub ahead of print. PMID: 33835769. DOI:10.1056/NEJMoa2104840
10. Graf T, Thiele T, Klingebiel R, et al. Immediate high-dose intravenous immunoglobulins followed by direct thrombin-inhibitor treatment is crucial for survival in Sars-Covid-19-adenoviral vector vaccine-induced immune thrombotic thrombocytopenia VITT with cerebral sinus venous and portal vein thrombosis. *J Neurol*. 2021 May 22:1–3 Epub ahead of print. PMID: 34023956; PMCID: PMC8140563. DOI:10.1007/s00415-021-10599-2.
11. Astrazeneca'S COVID-19 vaccine: EMA finds possible link to very rare cases of unusual blood clots with low platelets - European Medicines Agency. *European Medicines Agency*, 2021. cited 2021 Apr 10. Available from: <https://www.ema.europa.eu/en/news/astrazenecas-covid-19-vaccine-ema-finds-possible-link-very-rare-cases-unusual-blood-clots-low-blood>
12. Astrazeneca'S COVID-19 Vaccine. *Spa.Gov.Sa*, 2021. cited 2021 Apr 20. Available from: <https://www.spa.gov.sa/viewstory.php?lang=ar&newsid=2219569>
13. Kelland K, Guarascio F. Italy, Britain suggest age limits for astrazeneca vaccine but still recommend it. *U.S.*, 2021. cited 2021 Apr 14. Available from: <https://www.reuters.com/article/health-coronavirus-astrazeneca-idUSKBN2BU1R0>

14. Guidance produced from the expert haematology panel (EHP) focussed on syndrome of thrombosis and thrombocytopenia occurring after coronavirus vaccination. *B-S-H.Org.Uk*, 2021. cited 2021 Apr 11. Available from: https://b-s-h.org.uk/media/19512/guidance-version-10-on-mngmt-of-thrombosis-with-thrombocytopenia-occurring-after-c-19-vaccine_20210401.pdf
15. Menni C, Klaser K, May A, et al. Vaccine side-effects and SARS-CoV-2 infection after vaccination in users of the COVID Symptom Study app in the UK: a prospective observational study. *Lancet Infect Dis*. 2021 Apr 27;S1473-3099(21):00224.Epub ahead of print. PMID: 33930320; PMCID: PMC8078878.
16. Lopez Bernal J, Andrews N, Gower C, et al. Effectiveness of the Pfizer-BioNTech and Oxford-AstraZeneca vaccines on covid-19 related symptoms, hospital admissions, and mortality in older adults in England: test negative case-control study. *BMJ*. 2021 May 13;373:n1088