

Petechial skin rash associated with CoronaVac vaccination: first cutaneous side effect report before phase 3 results

Due to the newness of the virus, side effects of vaccines specific to SARS-CoV-2 are not yet known. CoronaVac, a purified inactivated SARS-CoV-2 vaccine developed by Sinovac Biotech (Beijing, China), has been shown to induce SARS-CoV-2-specific neutralising antibodies in mice, rats, non-human primates and in macaques.¹ CoronaVac was shown to be well tolerated and did not cause dose-related safety concerns in phase 1 and 2 clinical studies involving healthy individuals aged 18–59 years² and those aged 60 years and older.³ The most common symptom was injection site pain, and hypersensitivity reactions were the least reported side effects.² We do not know the phase 3 efficacy and side effect results of CoronaVac, although vaccination has started. Turkey has decided on the CoronaVac within the vaccine market and is currently continuing the vaccination of elderly people following health workers. Here we share up-to-date data on an elderly person who developed post-vaccination side effects in the form of a petechial rash.

An 82-year-old woman presented with weakness, burning in the legs and a rash. A diffuse petechial rash was observed on both lower extremities during dermatological examination (figure 1A,B). It was learned that she had been vaccinated with CoronaVac 1 day before the petechial rash appeared, and that there were no symptoms other than weakness and burning in the legs approximately 10 hours after vaccination. A complete blood test,

routine biochemical parameters, C-reactive protein, D-dimer levels, platelet count and coagulation parameters were normal. Urinalysis showed no signs of proteinuria or haematuria. Serological tests for viral hepatitis and HIV were negative. Antinuclear antibodies, antineutrophil cytoplasmic antibodies and cardiolipin antibodies were within normal ranges. Complement levels and serum proteinograms were normal. PCR and rapid IgM, IgG antibodies for SARS-COV-2 testing were negative. The patient had been using hydroxychloroquine 400 mg regularly for the last 3 years for seronegative rheumatoid arthritis, and olmesartan for 2 years for hypertension. She was taking no drug other than these and the vaccine. Prednisolone 5 mg, which she had been using for 6 months for seronegative arthritis, was discontinued 3 weeks before the vaccine in order not to prevent the effect of the vaccine. She was diagnosed with petechial rash as a vaccine-induced hypersensitivity reaction based on the clinical picture, history and laboratory analysis. According to the objective causality assessment by the Naranjo probability scale,⁴ the causal association between CoronaVac and the petechial rash was probable (Naranjo score=6).

The lesions regressed almost completely after 2 days and completely disappeared after 1 week. In the meantime, when safety in vaccine effect was reported if prednisolone was <20 mg in the newly published guideline by the American College of Rheumatology,⁵ the discontinued prednisolone was restarted 1 week after complete remission of the rash and this time, while she was using it for 2 weeks, the corresponding second dose of vaccine was administered. Probably as a result of this, no skin reaction was observed after

the second dose. Skin symptoms such as petechial exanthems⁶ and cutaneous leucocytoclastic vasculitis⁷ in COVID-19 are well defined and common. Here, the presence of viral proteins in the endothelial cells of the dermal vessels is thought to be responsible for the pathogenesis of petechiae purpura.⁶ As for vasculitis, it is thought that the accumulation of immune complexes that activate the complement cascade cause small vessel wall damage.⁷

Vaccine-associated hypersensitivity reactions are not infrequent; however, IgE or complement-mediated anaphylactic or serious delayed-onset T cell-mediated systemic reactions are extremely rare. Hypersensitivity may result either from the active vaccine component or one of the other components. Post vaccination acute-onset hypersensitivity reactions involve localised adverse events and systemic reactions varying from urticaria/angioedema to anaphylaxis, rarely. Delayed-type reactions happen generally within hours or days following exposure, although symptom onset can be seen after 2–3 weeks. The most frequent signs of delayed-type reactions are cutaneous eruptions such as maculopapular petechial rash. Delayed reactions are usually self-limiting conditions that do not contraindicate the administration of future booster doses of the same vaccine.⁸ Therefore, we decided to administer the second dose to our patient 28 days after the first dose.

The occurrence of a CoronaVac-related mucocutaneous eruption has been reported as 4% in phase 1/2 clinical studies involving healthy adults aged 60 years and older. Because the phase 3 results on CoronaVac have not yet been published, we are not sufficiently aware of CoronaVac-related cutaneous or systemic side effects.³ Hence, postmarketing safety surveillance is needed to identify rare serious adverse events, and case reports are crucial in this. As far as we are aware, this is the first cutaneous side effect following CoronaVac vaccination reported before the phase 3 results have been published.

Filiz Cebeci¹,¹ İlkey Kartal²

¹Department of Dermatology, Istanbul Medeniyet University, Istanbul, Turkey

²Department of Endocrinology, Istanbul Medeniyet University, Istanbul, Turkey

Correspondence to Professor Filiz Cebeci, Dermatology, Istanbul Medeniyet University, Istanbul 34720, Turkey; cebecifiliz@yahoo.com

Contributors FC is the primary physician of the patient discussed in this paper and supervised the process, created the idea, designed the process, reviewed the article, took part in patient care, data collection, literature review, writing and preparation

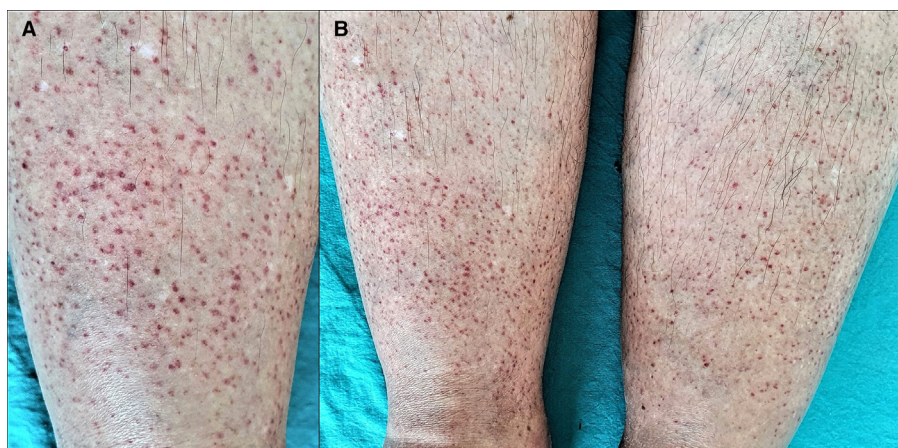


Figure 1 (A) Close view of the petechial rash on the right leg. (B) Bilaterally located petechial rash in the lower extremities.

of the manuscript. IK took part in the diagnosis and patient evaluation and reviewed the article.

Funding The authors have not declared a specific grant for this research from any funding agency in the public, commercial or not-for-profit sectors.

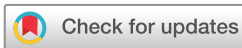Competing interests None declared.

Patient consent for publication Not required.

Provenance and peer review Not commissioned; internally peer reviewed.

This article is made freely available for use in accordance with BMJ's website terms and conditions for the duration of the covid-19 pandemic or until otherwise determined by BMJ. You may use, download and print the article for any lawful, non-commercial purpose (including text and data mining) provided that all copyright notices and trade marks are retained.

© European Association of Hospital Pharmacists 2021. No commercial re-use. See rights and permissions. Published by BMJ.



To cite Cebeci F, Kartal İ. *Eur J Hosp Pharm* Epub ahead of print: [please include Day Month Year]. doi:10.1136/ejhp-2021-002794

Eur J Hosp Pharm 2021;0:1–2.
doi:10.1136/ejhp-2021-002794

ORCID iD

Filiz Cebeci <http://orcid.org/0000-0002-9109-3892>

REFERENCES

- Gao Q, Bao L, Mao H, *et al.* Development of an inactivated vaccine candidate for SARS-CoV-2. *Science* 2020;369:77–81.
- Zhang Y, Zeng G, Pan H, *et al.* Safety, tolerability, and immunogenicity of an inactivated SARS-CoV-2 vaccine in healthy adults aged 18–59 years: a randomised, double-blind, placebo-controlled, phase 1/2 clinical trial. *Lancet Infect Dis* 2021;21:181–92.
- Wu Z, Hu Y, Xu M, *et al.* Safety, tolerability, and immunogenicity of an inactivated SARS-CoV-2 vaccine (CoronaVac) in healthy adults aged 60 years and older: a randomised, double-blind, placebo-controlled, phase 1/2 clinical trial. *Lancet Infect Dis* 2021;395. doi:10.1016/S1473-3099(20)30987-7. [Epub ahead of print: 03 Feb 2021].
- Naranjo CA, Busto U, Sellers EM, *et al.* A method for estimating the probability of adverse drug reactions. *Clin Pharmacol Ther* 1981;30:239245.
- ACR COVID-19 Vaccine Clinical Guidance Task Force. COVID-19 vaccine clinical guidance summary for patients with rheumatic and musculoskeletal diseases, 2021. Available: <https://www.rheumatology.org/Portals/0/Files/COVID-19-Vaccine-Clinical-Guidance-Rheumatic-Diseases-Summary.pdf>
- Diaz-Guimaraens B, Dominguez-Santas M, Suarez-Valle A, *et al.* Petechial skin rash associated with severe acute respiratory syndrome coronavirus 2 infection. *JAMA Dermatol* 2020;156:820–2.
- Mayor-Ibarguren A, Feito-Rodriguez M, Quintana Castaneda L, *et al.* Cutaneous small vessel vasculitis secondary to COVID-19 infection: a case report. *J Eur Acad Dermatol Venereol* 2020;34:e541–2.
- McNeil MM, DeStefano F. Vaccine-associated hypersensitivity. *J Allergy Clin Immunol* 2018;141:463–72.