

Medical Sciences, Zealand University Hospital, University of Copenhagen, Copenhagen, Denmark

E-mail: hans.christian.ring@regionh.dk

Conflict of interest: the authors declare that they have no conflicts of interest.

Accepted for publication 6 July 2021

References

- 1 Wark KJL, Cains GD. The microbiome in hidradenitis suppurativa: a review. *Dermatol Ther (Heidelb)* 2021; **11**: 39–52.
- 2 Ring HC, Thorsen J, Jørgensen AH *et al*. Predictive metagenomic analysis reveals a role of cutaneous dysbiosis in the development of hidradenitis suppurativa. *J Invest Dermatol* 2020; **140**: 1473–6.
- 3 Tan-Lim CSC, Esteban-Ipac NAR, Recto MST *et al*. Comparative effectiveness of probiotic strains on the prevention of pediatric atopic dermatitis: a systematic review and network meta-analysis. *Pediatr Allergy Immunol* 2021; <https://doi.org/10.1111/pai.13514>.
- 4 Ring HC, Bay L, Kallenbach K *et al*. Normal skin microbiota is altered in pre-clinical hidradenitis suppurativa. *Acta Derm Venereol* 2017; **97**: 208–13.
- 5 Ring HC, Thorsen J, Saunte DM *et al*. The follicular skin microbiome in patients with hidradenitis suppurativa and healthy controls. *JAMA Dermatol* 2017; **153**: 897–905.

Vesiculobullous skin reactions induced by COVID-19 mRNA vaccine: report of four cases and review of the literature

doi: 10.1111/ced.14835

Dear Editor,

Vaccines are proving to be the most important medical tool to prevent and control the current COVID-19 pandemic.¹ The skin is one of the organs in which postvaccination adverse effects are frequently detected.² The potential for vaccines to act as triggers of autoimmune reactions is a well-known adverse effect. COVID-19 mRNA vaccines might stimulate myeloid or plasmacytoid dendritic cells, generating an imbalance in the downstream cytokine pathways that play a crucial role in autoimmunity and autoinflammation.³ Bullous drug-induced reactions (BDRs) are considered to be one of the most severe cutaneous adverse reactions.⁴ We report four patients who developed severe BDR after receiving mRNA COVID-19 vaccines.

All four patients were men, with a mean age of 81.5 years (range 71–86 years; Table S1). The date of onset of BDR symptoms began between 3 and 17 days after vaccination with the BioNTech/Pfizer mRNA COVID-19 vaccine (Comirnaty®). In Patients 1, 2 and 3, physical examination revealed urticated and erythematous plaques and tense bullae measuring 10–30 mm in

diameter on an erythematous base, located on the trunk, forearms (Fig. 1a,b) and wrist (Fig. 1e). Patient 4 had a slightly different presentation with only small vesiculobullae, some in a rosette-like pattern, but limited to the thighs (Fig. 1h). Pruritus was very intense in all patients. No mucous membrane or eye involvement was detected in any of the patients, and they had no generalized symptoms. Histopathological examination of biopsies taken from the patients showed subepidermal (Fig. 1c,i) or subcorneal (Fig. 1c,f,i) blisters with eosinophils, and immunofluorescence showed positivity for IgG and C3 (Fig. 1d), IgG alone (Fig. 1g) or IgA (Fig. 1j) at the dermoepidermal junction (DEJ) in perilesional skin.

Drug reactions with blisters are a major concern for patients and physicians, and include bullous pemphigoid (BP) and linear IgA bullous dermatosis (LABD).

BP is a subepidermal autoimmune bullous dermatosis characterized by linear deposition of IgG and C3 along the DEJ. Dysregulation of the T-cell immune response and synthesis of IgG and IgE autoantibodies against these hemidesmosomal proteins (BP180 and BP230) lead to neutrophil chemotaxis and degradation of the basement membrane zone (BMZ). There has been an increase in the incidence rates of BP due to population ageing and also an increase in drug-induced cases.³ It is hypothesized that BP might be triggered by external factors in some genetically predisposed individuals. In these cases, exposure to vaccine might dysregulate the immune response, resulting in inactivation of regulatory T cells and stimulation of B-cell clones that recognize self-antigens, thereby inducing autoantibody production against hemidesmosomal proteins. Various vaccines have been reported to trigger BP.⁴ There is no specific biomarker of drug-induced BP, and the clinical presentation and immunopathological findings may be indistinguishable from the classic form. However, the prognosis is usually better, with rapid disease control and fewer or no recurrences once the culprit medication is withdrawn, which may suggest its role as a triggering factor.⁵

LABD is a rare acquired subepidermal immunoglobulin-mediated vesiculobullous disease characterized by linear deposition of IgA along the BMZ. Although most reported cases are idiopathic, there is a subset of patients with drug-induced LABD. The triggering factor of the autoimmune mechanism in LABD also remains unknown.⁶

Various drugs or vaccines have been associated with BDRs but no previous cases linked to mRNA vaccines have been reported, to our knowledge. The pathogenesis of these BDRs and the relationship with mRNA vaccines are unclear. Interestingly, oral vesiculobullous lesions have been reported as an early sign of COVID-19, and immunohistochemistry detects SARS-CoV-2 spike protein in the lesions.⁷

Recently, data have been published on a reaction between the SARS-CoV-2 spike protein antibody and tissue proteins, including transglutaminase (TGase)2, TGase3,

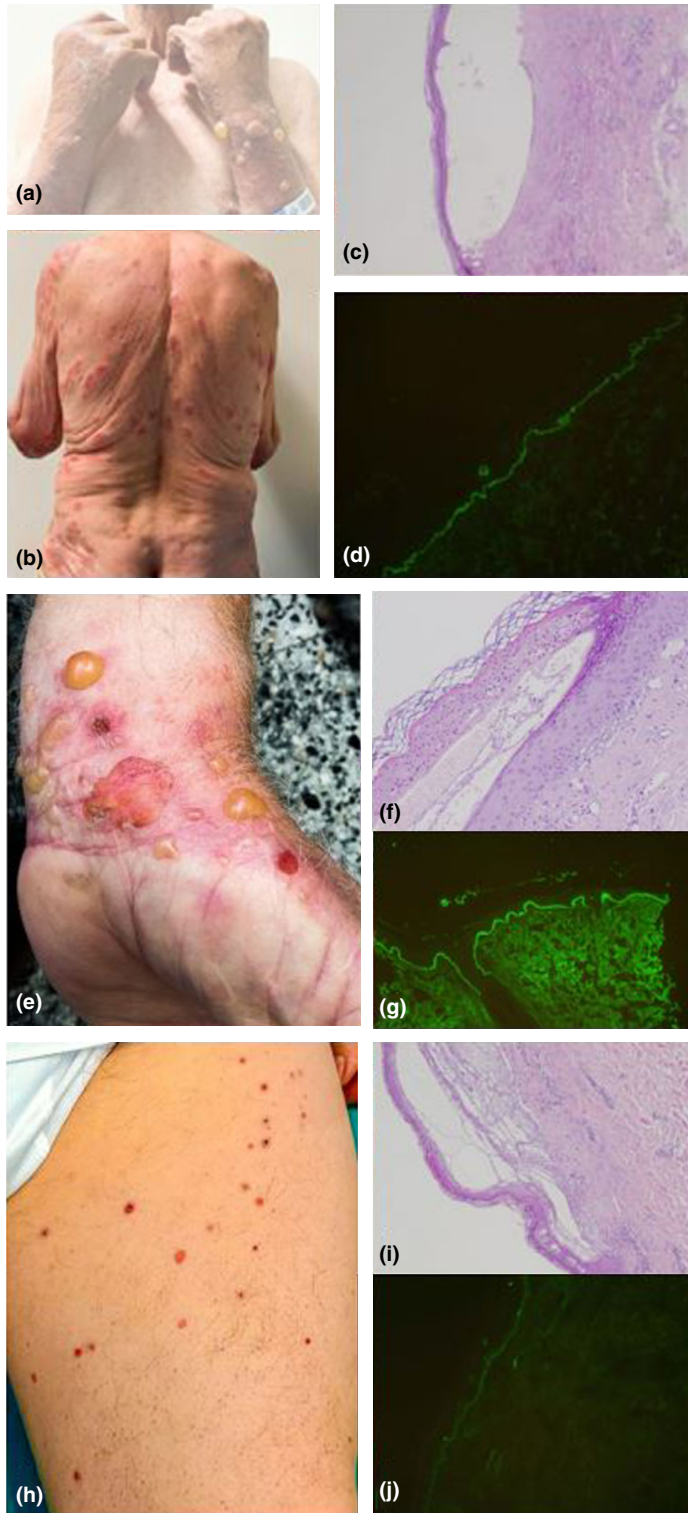


Figure 1 (a–d) Patient 2: (a,b) vesiculobullous lesions on (a) the forearms and (b) the back; (c) subepidermal blister with eosinophils in the dermis; and (d) strong positivity for C3 at the dermoepidermal junction (DEJ). (e–g) Patient 3: (e) vesiculobullous lesions on the wrist; (f) subcorneal blister with neutrophils embedded in serous transudate, with displacement over the granular layer; and (g) strong positivity for IgG at the DEJ. (h–j) Patient 4: (h) small vesicles on the thigh; (i) subepidermal bleb with eosinophils; and (j) perilesional skin with positivity for IgA at the DEJ. (c,f,i) Haematoxylin and eosin, original magnification $\times 200$; (d,g,j) immunofluorescence, original magnification $\times 200$.

extractable nuclear antigen, myelin basic protein, mitochondria, nuclear antigen, α -myosin, thyroid peroxidase, collagen, claudin 5 + 6 and S100B.⁸



Several interprotein crosslinks in the epidermis hold together a multiprotein assembly. TGases play a key role in assembling the cornified structure. TGase2 appears to

play intracellular functions in surface epithelial cells and in the underlying fibroblasts, while TGase3 is expressed in the upper epidermal layers and is localized in the cytoplasm. TGase3 is a well-known autoantigen in dermatitis herpetiformis, a blistering disease characterized by granular IgA deposits in the papillary dermis. These findings suggest that TGase3 may be the autoantigen involved in producing the skin phenotype. Furthermore, S100B has been described to be a potential biomarker for melanocyte cytotoxicity.

We hypothesize that these crossreactions between SARS-CoV-2 spike protein antibody and tissue proteins such as TGase2, TGase3, collagen and S100B may play a role in developing these immune-mediated skin disorders. As the mechanisms are still unclear, we have to consider that sensitization may occur over time, meaning that a reaction consistent with a BDR may occur rapidly upon renewed use of the drug. Finally, we stress the importance of reporting adverse skin reactions related to these new mRNA vaccines by healthcare professionals in order to promote pharmacovigilance systems and vaccine safety.

Acknowledgement

We thank Dr B. Vivanco-Allende of the Pathological Anatomy Department, Asturias Central University Hospital for her contribution to the immunofluorescence analysis of the biological samples.

P. Coto-Segura,¹ M. Fernández-Prada,^{2,3}  M. Mir-Bonafé,¹  B. García-García,¹ I. González-Iglesias,⁴ P. Alonso-Penanes,⁵ M. González-Guerrero,⁶ A. Gutiérrez-Palacios,⁶ E. Miranda-Martínez⁶ and F. Martín-Torres^{3,7,8}

¹Dermatology Department, Hospital Alvarez Buylla, Mieres;

²Vaccines Unit, Preventive Medicine and Public Health Department, Hospital Alvarez Buylla, Mieres; ³WHO Collaborating Centre for

Vaccine Safety, Santiago de Compostela, Spain; ⁴Emergency Department, Hospital Alvarez Buylla, Mieres; ⁵Dermatology

Department, Hospital Universitario de Cabueñes, Gijón, Spain;

⁶Pathological Anatomy Department, Hospital Alvarez Buylla, Mieres,

Spain; ⁷Translational Pediatrics and Infectious Diseases, Hospital

Clínico Universitario, Universidad de Santiago de Compostela (USC),

Santiago de Compostela, Spain and ⁸Genetics, Vaccines and Pediatric

Infectious Diseases Research Group (GENVIP), Instituto de

Investigación Sanitaria de Santiago, Universidad de Santiago de

Compostela (USC), Santiago de Compostela, Spain
E-mail: mariafdezprada@gmail.com

Conflict of interest: the authors declare that they have no conflicts of interest.

Accepted for publication 6 July 2021

References

- Martínez-Baz I, Miqueleiz A, Casado I *et al.* Effectiveness of COVID-19 vaccines in preventing SARS-CoV-2 infection

and hospitalisation, Navarre, Spain, January to April 2021. *Euro Surveill* 2021; **26**: 2100438.

- Blumenthal KG, Freeman EE, Saff RR *et al.* Delayed large local reactions to mRNA-1273 vaccine against SARS-CoV-2. *N Engl J Med* 2021; **384**: 1273–7.
- Mockenhaupt M. Bullous drug reactions. *Acta Derm Venereol* 2020; **100**: adv00057.
- Walmsley N, Hampton P. Bullous pemphigoid triggered by swine flu vaccination: case report and review of vaccine triggered pemphigoid. *J Dermatol Case Rep* 2011; **5**: 74–6.
- Stavropoulos PG, Soura E, Antoniou C. Drug-induced pemphigoid: a review of the literature. *J Eur Acad Dermatol Venereol* 2014; **28**: 1133–40.
- Díaz MS, Morita L, Ferrari B *et al.* Linear IgA bullous dermatosis: a series of 17 cases. *Actas Dermosifiliogr (Engl Ed)* 2019; **110**: 673–80.
- Soares CD, Carvalho RA, Carvalho KA *et al.* Letter to Editor: oral lesions in a patient with Covid-19. *Med Oral Patol Oral Cir Bucal* 2020; **25**: e563–4.
- Vojdani A, Kharrazian D. Potential antigenic cross-reactivity between SARS-CoV-2 and human tissue with a possible link to an increase in autoimmune diseases. *Clin Immunol* 2020; **217**: 108480.

Supporting Information

Additional Supporting Information may be found in the online version of this article:

Table S1. Clinical, demographic, vaccine-related variables and histopathological and immunohistochemical characteristics.

Data S1. Bibliography.

Vitiligo in a COVID-19-vaccinated patient with ulcerative colitis: coincidence?

doi: 10.1111/ced.14842

Dear Editor,

The COVID-19 pandemic has been a global emergency since January 2020. It became clear that it could only be controlled by vaccines; fortunately, several vaccines were developed by the end of 2020. These include mRNA vaccines, which received approval from the US Food and Drug Administration for emergency use.¹ However, as time has passed, a number of adverse events (AEs) have been reported in association with all the vaccines. We report the possible association of vitiligo with the Pfizer-BioNTech vaccine BNT162b2 (Cominarty®) in a patient with ulcerative colitis (UC).

A 58-year-old man presented with white macular plaques distributed symmetrically across his face (Fig. 1), which had appeared 1 week after receiving his first dose of vaccine. The plaques were clinically consistent with