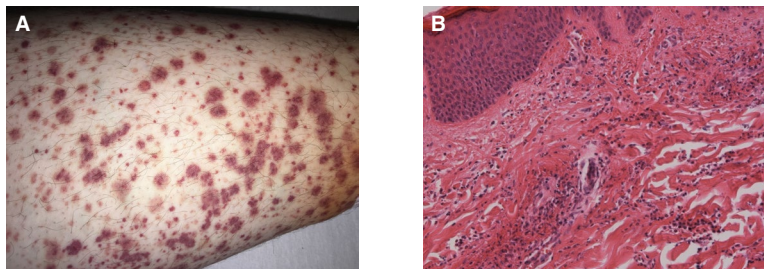


- Global Burden of Disease 2010 study. *Ann Rheum Dis* 2014;73:1316–22.
32. Price-Haywood EG, Burton J, Fort D, Seoane L. Hospitalization and mortality among black patients and white patients with Covid-19. *N Engl J Med* 2020;382:2534–43.
33. Kim AH, Sparks JA, Liew JW, Putman MS, Berenbaum F, Duarte-Garcia A, et al. A rush to judgment? Rapid reporting and dissemination of results and its consequences regarding the use of hydroxychloroquine for COVID-19 [editorial]. *Ann Intern Med* 2020;172:819–21.
34. Peckham H, de Groot NM, Raine C, Radziszewska A, Ciurtin C, Wedderburn LR, et al. Male sex identified by global COVID-19 meta-analysis as a risk factor for death and ITU admission. *Nat Commun* 2020;11:6317.

DOI 10.1002/art.41910

Clinical Images: Leukocytoclastic vasculitis after vaccination with a SARS-CoV-2 vaccine



The patient, a 42-year-old White woman, presented to the emergency room with a 1-week history of rash on the lower legs, which had first appeared 4 days after vaccination with the BioNTech/Pfizer SARS-CoV-2 vaccine. The rash—with the typical appearance of cutaneous small vessel vasculitis (SVV)—spread from the lower limbs up to the gluteal area over the course of a few days (A). Application of topical steroids did not lead to improvement. Physical examination showed no other conditions, except for hypertension and severe obesity (body mass index 47 kg/m²). Typical causes of cutaneous SVV (1) were considered, and concomitant medication or infection could be ruled out as possible triggers. Besides slightly elevated levels of inflammation markers, laboratory test results for complement components C3 and C4, CH50, IgM, IgA, immunofixation, and renal and liver parameters were normal. IgG and thyroid-stimulating hormone were slightly elevated (20.3 gm/liter and 8.3 μU/liter, respectively). Chest radiography, echocardiography, and ultrasound examination of the abdomen revealed normal results, as did serologic tests for autoimmune antibodies (classic/perinuclear antineutrophil cytoplasmic antibody, rheumatoid factor, anti-citrullinated protein antibody, antinuclear antibody [titer 1:160 with nuclear fine speckled pattern] and negativity for a panel of extractable nuclear antigen antibodies [including Jo-1, U1 RNP, Scl-70, Sm, and Ro/La antibodies]), and screening for viral infections (hepatitis B and C, cytomegalovirus, Epstein-Barr virus, coxsackievirus, and HIV) and cryoglobulins. Following analysis of a skin biopsy sample from the patient's left ankle (B), leukocytoclastic vasculitis was diagnosed. The skin tissue was also assessed by immunostaining, but results were not evaluable. Prednisolone treatment was started, at an initial dose of 30 mg/day which was later increased to 60 mg/day due to poor response. With this treatment the rash resolved over the next 5 days. Leukocytoclastic vasculitis is typically found to be idiopathic in up to 50% of cases; however, due to its emergence in this patient shortly after she had received the SARS-Cov-2 vaccination, we think a possible connection to the vaccine should be considered. To our knowledge, this might be the first case of the development of leukocytoclastic vasculitis after vaccination against SARS-CoV-2, whereas cutaneous SVV has been described in a patient following SARS-CoV-2 infection (2), and also SVV has been observed in patients after various other vaccinations, such as those against influenza or pneumococci (3). Since experience with the new COVID-19 vaccines is limited—as they have been in use for <1 year—further investigations and observations are essential.

Author disclosures are available at <https://onlinelibrary.wiley.com/action/downloadSupplement?doi=10.1002%2Fart.41910&file=art41910-sup-0001-Disclosureform.docx>.

- Gota CE, Calabrese LH. Diagnosis and treatment of cutaneous leukocytoclastic vasculitis [review]. *Int J Clin Rheumatol* 2013;8:49–60.
- Gottlieb M, Long B. Dermatologic manifestations and complications of COVID-19 [review]. *Am J Emerg Med* 2020;38:1715–21.
- Cao S, Sun D. Leukocytoclastic vasculitis following influenza vaccination. *BMJ Case Rep* 2017;2017:bcr-2016-217755.

Anne Erler, MD 
 John Fiedler
 Anna Koch
 Frank Heldmann, MD
 Zeisigwaldkliniken Bethanien Chemnitz
 Chemnitz, Germany
 Alexander Schütz, MD
 Institute of Pathology at Elsapark
 Leipzig, Germany