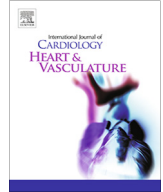




Contents lists available at ScienceDirect

IJC Heart &amp; Vasculature

journal homepage: [www.journals.elsevier.com/ijc-heart-and-vasculature](http://www.journals.elsevier.com/ijc-heart-and-vasculature)

## Correspondence

## Lymphohistocytic myocarditis after Ad26.COV2.S viral vector COVID-19 vaccination

Francisco Ujueta<sup>a,\*</sup>, Roshanak Azimi<sup>b</sup>, Matthew R. Lozier<sup>a</sup>, Robert Poppiti<sup>b</sup>, Ari Ciment<sup>c</sup><sup>a</sup> Columbia University Division of Cardiology at Mount Sinai Medical Center, Miami Beach, FL, United States<sup>b</sup> The Arkadi M. Rywlin M.D. Department of Pathology and Laboratory Medicine at Mount Sinai Medical Center, Miami Beach, FL, United States<sup>c</sup> Department of Pulmonology and Critical Care at Mount Sinai Medical Center, Miami Beach, FL, United States

Coronavirus disease (COVID-19) has caused approximately 4.38 million deaths worldwide with 208 million individuals infected. In addition, many with COVID-19 disease or post-COVID-19 infection have experienced cardiac involvement, such as myocarditis, or cardiac arrhythmias [1]. Fortunately, development of modified RNA (mRNA) and viral vector vaccines have curbed the incidence and mortality from COVID-19 [2]. Although countries, have demonstrated a decreased incidence of infection resulting from increased rates of COVID-19 vaccination, many individuals remain unvaccinated due to concerns of potential side-effects or complications. This journal published a case report on April 2021 suggesting a possible association between the Pfizer (mRNA) vaccine and myocarditis [3]. Further reports have supported the association between the mRNA vaccine and the development of myocarditis in young adults and an older adult with previous history of COVID-19 [4,5]. It is important to make the distinction that this patient obtained a viral vector vaccine and no similar case of myocarditis has been reported.

A 62-year-old Caucasian female visiting from Uruguay presented to the emergency department complaining of progressive body aches, weakness and worsening fatigue approximately 4 days after administration of the Ad26.COV2.S (Janssen Johnson & Johnson<sup>®</sup>) viral vector COVID-19 vaccine. The patient denied any recent infectious symptoms including fever, chills, myalgia, diarrhea, cough, or rhinitis prior to vaccine administration. She had a medical history significant for melanoma status post-surgical resection and treatment with Pembrolizumab over one year prior (discontinued due to pneumonitis) as well as essential thrombocytosis currently receiving treatment with Anagrelide. Prior to this presentation, the patient was exercising daily with her husband and participating in competitive sports without any complaints. She denied any history of tobacco or illicit drug use.

On arrival, her blood pressure was 96/67 mmHg, heart rate 123 beats per minute, oxygen saturation 96% on room air and temperature of 35.7 °C. Electrocardiogram (ECG) revealed sinus tachycardia with T wave inversions in the septal leads with right atrial

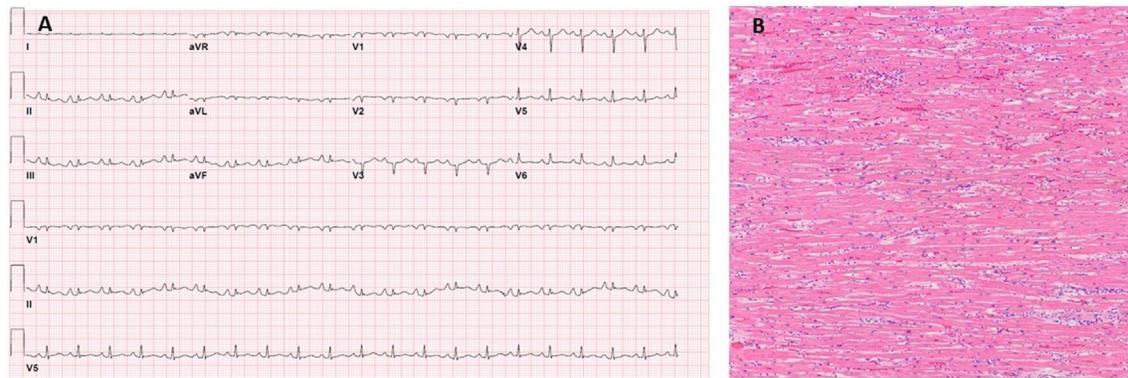
enlargement (Fig. 1a). The chest-x-ray did not reveal any acute abnormalities. Laboratory tests revealed a troponin elevation of 4.7, lactic acid of 7.8, NT-Pro-BNP of 30,064, and leukocytosis of 28.88 with left shift without peripheral eosinophilia (Table 1). SARS-19 rapid test (Cepheid<sup>®</sup>) was negative. Bedside echocardiogram revealed a severe biventricular cardiomyopathy with left ventricular ejection fraction of 29%, and a small pericardial effusion with no evidence of increased intrapericardial pressure (supplementary Fig. 1A & B, Video Supplementary). Urgent cardiac angiography was completed which demonstrated a cardiac output 5.1 L/min, cardiac index 3.26 L/min/m<sup>2</sup>, left ventricular end-diastolic pressure 37 mmHg, and no obstructive disease on maximum dose of Norepinephrine. Right heart catheterization demonstrated pulmonary artery pressure of 36/30 mm Hg, with a mean of 33 mm Hg. The patient was transferred to the intensive care unit with increasing vasopressor support with maximal dosing of Vasopressin, Phenylephrine, and Epinephrine. Intravenous (IV) Methylprednisolone 60 mg bolus was administered every 8 h, and intravenous immunoglobulin was ordered but not administered [7]. A cardiac arrest code was called 18 h after presentation, and the patient expired after several rounds of advanced cardiovascular life support. Consent was obtained for an autopsy.

The autopsy was performed 9-hours postmortem. No remarkable changes were observed on the body surface. Autopsy revealed about 15 cc of straw-colored fluid in the pericardial sac. The heart weighed 250 g with unremarkable gross changes. No apparent coronary artery disease was appreciated. No focal lesions suggestive of acute or chronic hypoxic injury were identified. Microscopic view of the myocardial biopsy showing scattered positive CD3 immunostaining supporting T cell infiltration (Fig. 1b). Multiple immunohistochemistry staining like CD163 supports the diagnosis of lymphohistocytic myocarditis with sparse eosinophils (Supplementary Fig. 2).

Both lungs were congested and heavy (right 630 g and left 650 g). There were 850 and 320 cc of serosanguineous fluid on right and left pleural cavities, respectively. Grossly, multiple nodules were identified in all lobes of the lungs, ranging from 0.5 to 1.5 cm in size. The cut surfaces showed a variety of consistencies and colors from a firm red pink to a semisolid white with grumous material. Sampling of tissue from all nodules showed multiple sites

\* Corresponding author at: Columbia University Division of Cardiology at Mount Sinai Medical Center, 4300 Alton Road, Suite # 2070A, Miami Beach, FL 33140, United States.

E-mail address: [Francisco.ujeta@msmc.com](mailto:Francisco.ujeta@msmc.com) (F. Ujueta).



**Fig. 1.** (A) Admission electrocardiogram. Sinus tachycardia, possible left atrial enlargement, low voltage QRS, Septal infarct, age undetermined. (B) Extensive interstitial edema with inflammatory infiltrate composed predominantly of histiocytes in the myocardium of the left ventricle (hematoxylin-eosin, magnification 200×).

**Table 1**

Clinical Laboratories.

	Emergency Room	12-hours	Reference Range
<b>Complete blood count</b>			
White blood cell count (10 <sup>3</sup> /uL)	28.88	37.65	4.8–10.8 10 <sup>3</sup> /uL
Lymphocytes Absolute count (10 <sup>3</sup> /uL)	1.28	3.64	1–4 10 <sup>3</sup> /uL
Lymphocyte (%)	4.4	9.7	16–45 %
Eosinophils (10 <sup>3</sup> /uL)	0.02	0.07	0–0 10 <sup>3</sup> /uL
Eosinophils (%)	0.1	0.2	0–5%
Hemoglobin (g/dL)	18.5	13.5	12–16 g/dL
Hematocrit (%)	56.9	42.5	37–47%
Platelets (10 <sup>3</sup> /uL)	940	633	150–450 10 <sup>3</sup> /uL
<b>Complete metabolic panel</b>			
Creatinine	1.12	1.04	0.55–1.02 mg/dL
Blood urea nitrogen	32	30	7–18 mg/dL
Glucose	195	201	74–106 mg/dL
Sodium	132	142	136–145 mmol/L
Potassium	3.9	5.4	3.5–5.1 mmol/L
ALT	35	74	13–56 u/L
AST	59	137	15–39 u/L
Total Bilirubin	0.6	0.8	0.20–1.0 mg/dL
INR	1.1	4.2	0.1–1.1
<b>Cardiac Markers</b>			
Troponin I	4.7	6.4	0.0–0.06 ng/mL
NT-Pro-BNP	30,064	31,802.70	10–300 pg/mL
<b>Inflammatory markers</b>			
hs C-Reactive protein	49		0.16–3.00 mg/L
ESR	6		0–20 mm/HR
<b>Others</b>			
LDH	402		84–246 u/L
Procalcitonin	0.13		0.05–0.09 ng/mL
Lactic acid	7.8	13.5	0.4–2.0 mmol/L
TSH	1.58		0.35–3.74 uIU/mL
CPK	1,109	1,319	26–192 u/L
D-dimer		2.33	
Complement C3		36	90–180 mg/dL
Complement C4		10.4	10–40 mg/dL
Legionella Ag		Negative	
Influenza A & B		Not detected	
RSV PCR		Not detected	
Respiratory pathogen PCR		Not detected	(>15 viral pathogens)

of metastasis of melanoma in both lungs. Examination of blood vessels revealed numerous sites of thrombotic microangiopathy.

Although a definite conclusion cannot be made on the cause of this patients' lymphohistiocytic myocarditis, a potential relationship between the viral vector COVID-19 vaccine can be suggested.

Recent reports suggest a potential relationship between the mRNA vaccine and myocarditis in adults [3]. In addition, this journal in April presented a case of myocarditis in a patient with a previous history of SARS-CoV-2 infection after his second mRNA COVID-19 vaccine has been reported [4]. It is important to make the distinc-

tion that this patient obtained a viral vector vaccine. Eosinophilic myocarditis has been shown to present with acute biventricular heart failure, cardiogenic shock, myocardial infarction like syndrome and thrombosis, with or without peripheral eosinophilia [8]. Similarly, this patient presented with signs and symptoms of acute myocardial infarction with elevated troponin, NT-ProBNP, electrocardiogram T wave abnormalities with emergent coronary angiography not revealing any significant obstructive disease. Although the myocardial infiltrate in this case was predominately lymphohistiocytic, eosinophils were also present.

This case suggests a potential relationship between the viral vector COVID-19 vaccine and the patient's lymphohistiocytic myocarditis resulting in severe biventricular cardiomyopathy and death. Although there have been no previous reports of cardiac involvement with the viral vector vaccine, the timing of the event and the lack of other identifiable etiologies suggest a relationship. Acute myocarditis may also be due to immune checkpoint inhibitors [9]. This patient was previously treated with Pembrolizumab for malignant melanoma, but the last administration was over one year ago making this medication the unlikely cause. Although acute viral illness has also been well documented as a cause of myocarditis [6,10], the lack of signs, symptoms, and negative viral panel polymerase chain reaction make this etiology unlikely. Treatment guidelines recommend high dose steroids and possible benefit from administration of IVIG [7]. Although this patient received high doses of IV steroids, IVIG was not able to be administered due to rapid deterioration and patient death. Another important intervention which may improve patient outcome is mechanical support with VA-ECMO [7]. In conclusion, this study suggests a potential relationship between the COVID-19 viral vector vaccine and lymphohistiocytic myocarditis. Although limited reports are currently available, increased vaccination will provide physicians data to further explore a possible relationship between cardiac involvement and the COVID-19 viral vector vaccine.

#### Declaration of Competing Interest

The authors declare that they have no known competing financial interests or personal relationships that could have appeared to influence the work reported in this paper.

#### Appendix A. Supplementary material

Supplementary data to this article can be found online at <https://doi.org/10.1016/j.ijcha.2021.100869>.

#### References

- [1] R.M. Inciardi, L. Lupi, G. Zaccone, et al., Cardiac Involvement in a Patient With Coronavirus Disease 2019 (COVID-19), *JAMA Cardiol.* 5 (7) (2020) 819, <https://doi.org/10.1001/jamacardio.2020.1096>.
- [2] N. Dagan, N. Barda, E. Kepten, O. Miron, S. Perchik, M.A. Katz, M.A. Hernán, M. Lipsitch, B. Reis, R.D. Balicer, BNT162b2 mRNA Covid-19 Vaccine in a Nationwide Mass Vaccination Setting, *N. Engl. J. Med.* 384 (15) (2021) 1412–1423, <https://doi.org/10.1056/NEJMoa2101765>, Epub 2021 Feb 24. PMID: 33626250; PMCID: PMC7944975.
- [3] S. Abu Mouch, A. Roguin, E. Hellou, A. Ishai, U. Shoshan, L. Mahamid, M. Zoabi, M. Aisman, N. Goldschmid, N. Berar Yanay, Myocarditis following COVID-19 mRNA vaccination, *Vaccine* (2021), <https://doi.org/10.1016/j.vaccine.2021.05.087>, S0264-410X(21)00682-4. Epub ahead of print. PMID: 34092429; PMCID: PMC8162819.
- [4] E. Ammirati, C. Cavalotti, A. Milazzo, P. Pedrotti, F. Soriano, J.W. Schroeder, N. Morici, C. Giannattasio, M. Frigerio, M. Metra, P.G. Camici, F. Oliva, Temporal Relation Between Second Dose BNT162b2 mRNA Covid-19 Vaccine and Cardiac involvement in a Patient with Previous SARS-COV-2 Infection, *Int. J. Cardiol. Heart Vasc.* (2021) 100778, <https://doi.org/10.1016/j.ijcha.2021.100778>, Epub ahead of print. PMID: 33842684; PMCID: PMC8020086.
- [5] K.F. Larson, E. Ammirati, E.D. Adler, L.T. Cooper, K.N. Hong, G. Saponara, D. Couri, A. Cereda, A. Procopio, C. Cavalotti, F. Oliva, T. Sanna, V.A. Ciconte, G. Onyango, D.R. Holmes Jr., D.D. Borgeson, Myocarditis after BNT162b2 and mRNA-1273 Vaccination, *Circulation* (2021), <https://doi.org/10.1161/CIRCULATIONAHA.121.055913>, Epub ahead of print. PMID: 34133884.
- [6] M. Kerneis, K. Bihan, J.-E. Salem, COVID-19 vaccines and myocarditis, *Arch. Cardiovasc. Dis.* 114 (6-7) (2021) 515–517.
- [7] E. Ammirati, M. Frigerio, E.D. Adler, C. Basso, D.H. Birnie, M. Brambatti, M.G. Friedrich, K. Klingel, J. Lehtonen, J.J. Moslehi, P. Pedrotti, O.E. Rimoldi, H.P. Schultheiss, C. Tschöpe, L.T. Cooper Jr., P.G. Camici, Management of Acute Myocarditis and Chronic Inflammatory Cardiomyopathy: An Expert Consensus Document, *Circ. Heart Fail.* 13 (11) (2020) e007405.
- [8] M. Brambatti, M.V. Matassini, E.D. Adler, K. Klingel, P.G. Camici, E. Ammirati, Eosinophilic Myocarditis: Characteristics, Treatment, and Outcomes, *J. Am. Coll. Cardiol.* 70 (19) (2017) 2363–2375, <https://doi.org/10.1016/j.jacc.2017.09.023>, PMID: 29096807.
- [9] S.S. Mahmood, M.G. Fradley, J.V. Cohen, A. Nohria, K.L. Reynolds, L.M. Heinzerling, R.J. Sullivan, R. Damrongwatanasuk, C.L. Chen, D. Gupta, M.C. Kirchberger, M. Awadalla, M.Z.O. Hassan, J.J. Moslehi, S.P. Shah, S. Ganatra, P. Thavendiranathan, D.P. Lawrence, J.D. Groarke, T.G. Neilan, Myocarditis in Patients Treated With Immune Checkpoint Inhibitors, *J. Am. Coll. Cardiol.* 71 (16) (2018) 1755–1764, <https://doi.org/10.1016/j.jacc.2018.02.037>, Epub 2018 Mar 19. PMID: 29567210; PMCID: PMC6196725.
- [10] R. Dennert, H.J. Crijns, S. Heymans, Acute viral myocarditis, *Eur. Heart J.* 29 (17) (2008) 2073–2082, <https://doi.org/10.1093/eurheartj/ehn296>.