

Pericarditis after administration of the BNT162b2 mRNA COVID-19 vaccine



Pericarditis tras la administración de la vacuna de ARNm BNT162b2 contra la COVID-19

To the Editor,

The first reported case of myocarditis after administration of the BNT162b2 vaccine (BioNTech-Pfizer, Germany-United States) against COVID-19 was recently published.¹

According to the *Brighton Collaboration*, myocarditis and pericarditis are theoretical risks of vaccination against SARS-CoV-2 due to immunopathological mechanisms and should be considered adverse events of special interest, with close monitoring of their development in vaccinated people or of an increase in their incidence vs that expected.² Multiple cases of pericarditis have been reported after SARS-CoV-2 infection,³ but there have been no published cases of pericarditis after vaccination against COVID-19.

Here, we report 2 cases of pericarditis after administration of the BNT162b2 vaccine. Both patients have consented to the publication of their clinical cases. In addition, these adverse events have been reported to the Spanish Pharmacovigilance System for Medicines for Human Use.

Case 1 concerns a 36-year-old man with a history of acute idiopathic pericarditis in 2013, who was under any routine treatment. He presented to the emergency department with crushing chest pain that began some hours before. The pain was not effort-related but increased with deep breathing and when the patient was lying down and improved when he was sitting up. The

patient stated that the pain was similar to that of the previous episode of pericarditis. He had no fever and did not report any recent respiratory infections. He had no history of COVID-19. He had received the second dose of the BioNTech-Pfizer mRNA vaccine 11 days before symptom onset.

During his stay in our center, the patient was hemodynamically stable, with adequate saturation. Physical examination revealed no abnormal findings (no murmur or pericardial friction rub).

Electrocardiography (*figure 1A*) demonstrated sinus tachycardia with no clear signs of pericarditis. Blood tests showed leukocytosis ($11.60 \times 10^3/\mu\text{L}$) with neutrophilia ($8.7 \times 10^3/\mu\text{L}$), without elevated acute phase reactants (C-reactive protein, 1.80 mg/L; D-dimer, 117 ng/mL). Myocardial damage markers were negative, with high-sensitivity troponin of 9 (0-72) ng/L. Chest radiography showed no pertinent findings.

The patient was discharged with clinical judgment of incipient acute pericarditis, although he met only 1 diagnostic criterion (pain with pericarditis characteristics). Given the clinical suspicion, treatment was begun with nonsteroidal anti-inflammatory agents (ibuprofen, 600 mg/8 h) and colchicine. The patient was evaluated in the outpatient cardiology clinic 48 hours later and the diagnosis of pericarditis was confirmed after a new electrocardiogram (*figure 1B*) revealed PR interval shortening with incipient submillimeter, concave, and generalized ST-segment elevation that was not present on the previous electrocardiogram. Transthoracic echocardiography showed no pericardial effusion or other abnormalities. The patient exhibited a favorable clinical course, with complete cessation of the pain, and he remains asymptomatic.

Case 2 concerns an 80-year-old man with a history of paroxysmal atrial fibrillation treated with pulmonary vein

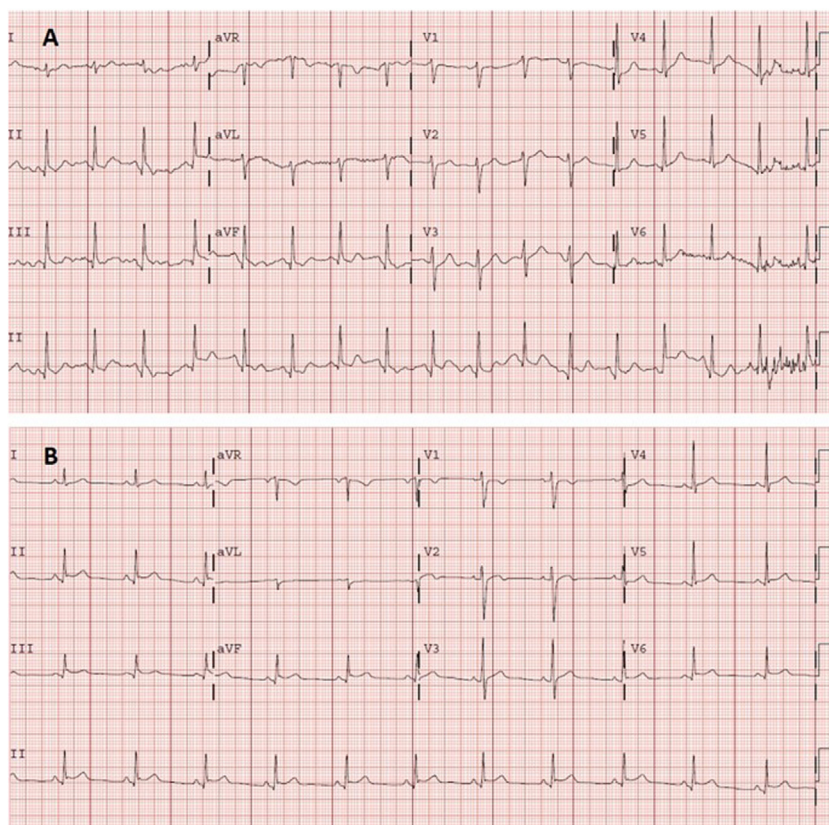


Figure 1. A: electrocardiogram obtained in the emergency department. Sinus tachycardia at 105 bpm, normal axis (90°). Normal PR interval (120 ms). Narrow QRS. Nonsignificant Q wave in the inferior wall. Without acute repolarization abnormalities. Corrected QT in the normal range. B: electrocardiogram obtained 2 days later in the cardiology clinic. Sinus rhythm at 75 bpm, normal axis. Normal PR interval (120 ms), with a PR segment decrease. Narrow QRS. Concave and generalized ST-segment elevation. Corrected QT in the normal range.

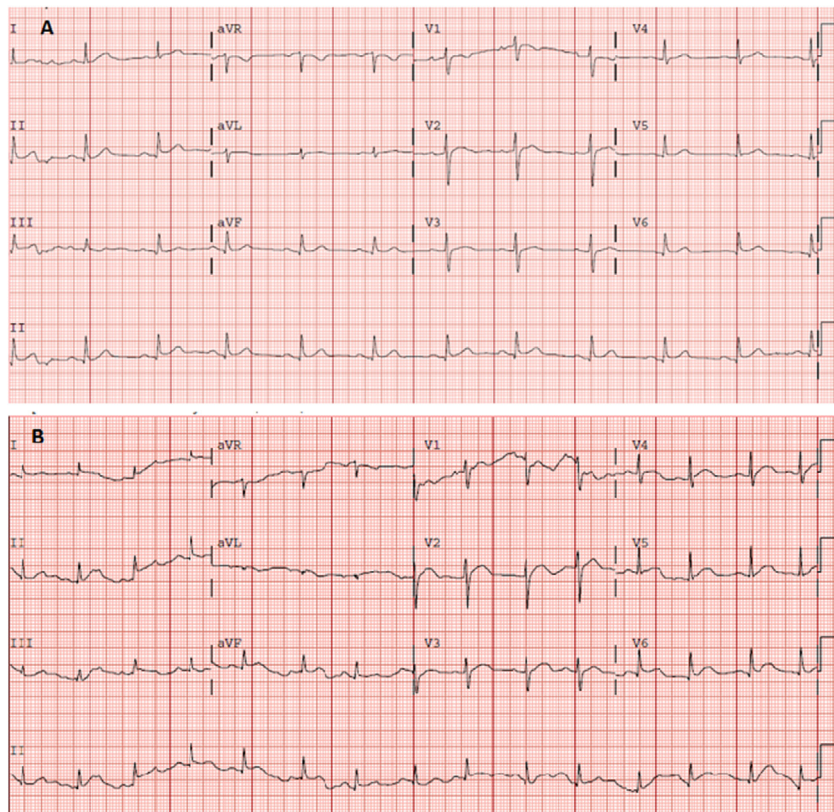


Figure 2. A: electrocardiogram obtained in the emergency department showing sinus rhythm at 75 bpm. Normal axis. Narrow QRS and ST-segment elevation in the inferolateral wall. Corrected QT in the normal range. B: electrocardiogram obtained 5 days later showing sinus rhythm at 85 bpm. Normal axis. Narrow QRS. Generalized ST-segment elevation with concave morphology. Corrected QT in the normal range.

cryoablation in 2009. He was referred to the emergency department by his primary care physician after 4 days of pain localized to the left hemithorax. The pain was not effort-related and worsened with deep breathing. He had no fever and did not report recent respiratory infections. He had received the second dose of the BioNTech-Pfizer mRNA vaccine 11 days before symptom onset. He had no history of COVID-19.

The patient was hemodynamically stable, with good saturation, and with no abnormalities on physical examination (no murmur or pericardial friction rub).

Electrocardiography (figure 2A) revealed ST-segment elevation localized to the inferior (II, III, and aVF) and lower lateral (V₄-V₆) walls, with decreased voltages in these leads. Blood tests showed elevated acute phase reactants (C-reactive protein, 58 mg/L; D-dimer, 586 ng/mL) and a normal complete blood count. Myocardial damage markers were negative, with high-sensitivity troponin of 7 ng/L. Chest radiography showed no pertinent findings.

Pericarditis was diagnosed based on the pain with pericarditis characteristics and the compatible electrocardiogram. The patient was discharged under treatment with nonsteroidal anti-inflammatory agents and colchicine and with withdrawal of his antiplatelet regimen. The patient attended the emergency department again 5 days later with colchicine-related diarrhea; he was found to have leukocytosis ($14.56 \times 10^3/\mu\text{L}$) with neutrophilia ($12.5 \times 10^3/\mu\text{L}$), persistent inflammatory parameters (C-reactive protein, 56.3 mg/L; fibrinogen, 736 mg/dL), and compatible electrocardiogram (figure 2B). Transthoracic echocardiography performed in the outpatient clinic showed minimal but universal pericardial effusion.

In both cases, the study was completed with postvaccination serology, which showed a positive vaccine response (antiprotein S

antibodies) at 333 and 133 UA/mL, respectively, without serological evidence of previous COVID-19 infection (antinucleocapsid antibodies).

Although causality could not be established, a suspected adverse drug reaction is reasonable due to the temporal correlation (both cases occurring 11 days after the second dose), as well as the biological plausibility of an autoimmune response or a crossreaction due to molecular mimicry.⁴

In conclusion, we present 2 cases of pericarditis occurring after anti-SARS-CoV-2 vaccination. We wish to highlight the importance of monitoring and documenting adverse events experienced by patients after vaccination and reporting those that are severe or unknown.⁵

Acknowledgments

We appreciate the approval of the patients to publish their clinical cases, as well as the help of the Pharmacovigilance Center of the Community of Madrid.

FUNDING

None.

AUTHORS' CONTRIBUTIONS

A. Ramírez-García is the main author of the text. S. Lozano Jiménez is the principal reviewer of the clinical cases. A. Ramírez-García, S. Lozano Jiménez, I. Darnaude, A. Gil Cacho, and R. Aguado-

Noya attended to and diagnosed the patients. J. Segovia is the chief of the cardiology department of the hospital.

CONFLICTS OF INTEREST

None of the authors have any conflicts of interest to declare.

Almudena Ramírez-García,^{a,*} Sara Lozano Jiménez,^b
Ignacio Darnaude Ximénez,^a Alberto Gil Cacho,^c
Ramón Aguado-Noya,^c and Javier Segovia Cubero^b

^aServicio de Farmacología Clínica, Hospital Universitario Puerta de Hierro-Majadahonda, Majadahonda, Madrid, Spain

^bServicio de Cardiología, Hospital Universitario Puerta de Hierro-Majadahonda, Majadahonda, Madrid, Spain

^cServicio de Urgencias, Hospital Universitario Puerta de Hierro-Majadahonda, Majadahonda, Madrid, Spain

* Corresponding author:

E-mail address: Almudena.ramirez@salud.madrid.org
(A. Ramírez-García).

Available online 16 July 2021

REFERENCES

- García JB, Ortega PP, Antonio Bonilla Fernández J, León AC, Burgos LR, Dorta EC. Miocarditis aguda tras administración de vacuna BNT162b2 contra la COVID-19. *Rev Esp Cardiol*. 2021. <http://dx.doi.org/10.1016/j.recesp.2021.03.009>.
- Law B, Sturkenboom M. D2.3 Priority List of Adverse Events of Special Interest: COVID-19. *Brighton Collaboration*. 2020. Disponible en: https://brightoncollaboration.us/wp-content/uploads/2020/06/SPEAC_D2.3_V2.0_COVID-19_20200525_public.pdf. Consultado 15 May 2021
- Diaz-Arocutipa C, Saucedo-Chinchay J, Imazio M. Pericarditis in patients with coronavirus disease 2019: a systematic review. *J Cardiovasc Med (Hagerstown)*. 2021. <https://doi.org/10.2459/JCM.0000000000001202>
- Talotta R. Do COVID-19 RNA-based vaccines put at risk of immune-mediated diseases? In reply to "Potential antigenic cross-reactivity between SARS-CoV-2 and human tissue with a possible link to an increase in autoimmune diseases". *Clin Immunol*. 2021;224:108665.
- Esteban Calvo C, Gil López-Oliva A, Ibáñez Ruiz C. RAM Reacciones adversas a medicamentos Boletín Informativo del Centro de Farmacovigilancia de la Comunidad de Madrid. 2021;28(1.). Disponible en: <http://www.madrid.org/bvirtual/BVCM050298.pdf>. Consultado 15 May 2021

<https://doi.org/10.1016/j.rec.2021.06.005>

1885-5857/ © 2021 Sociedad Española de Cardiología. Published by Elsevier España, S.L.U. This is an open access article under the CC BY-NC-ND license (<http://creativecommons.org/licenses/by-nc-nd/4.0/>).

Mortality risk in COVID-19 patients with right bundle branch block



Riesgo de mortalidad en pacientes con COVID-19 con bloqueo de rama derecha

To the Editor,

Recent analyses have demonstrated that COVID-19 patients with pre-existing cardiovascular risks and/or comorbidities have a higher risk of death in the short-term. However, the prognostic role of right bundle branch block (RBBB) in these patients has not yet been evaluated. The aim of this study was to perform a brief meta-analysis on the prognostic impact of RBBB on short-term mortality in COVID-19 patients. The study was performed in accordance with the Preferred Reporting Items for Systematic Reviews and Meta-analyses (PRISMA) guidelines. The MEDLINE and Scopus databases were systematically searched for articles, published in English, from the inception of the COVID-19 pandemic (January 2020) through 1 May 2021 using the following Medical Subject Heading (MESH) terms: "COVID-19" AND "Arrhythmias" OR "Right bundle branch block". Inclusion criteria were: a) studies enrolling participants with a confirmed diagnosis of COVID-19; b) providing data on the presence/absence of RBBB among survivors (S) and nonsurvivors (NS), allowing us to calculate an unadjusted odds ratio (OR) when not provided; and c) reporting all-cause mortality by the presence or absence of RBBB. We excluded case reports, review articles, editorials/letters, and case series with less than 10 participants, randomized controlled trials and studies including duplicate populations and investigations evaluating the electrocardiographic consequences of specific COVID-19 therapy. References from the included studies were screened to potentially identify other investigations meeting the inclusion criteria. Ethical approval and informed consent were not required as the study did not directly enrol human participants. The quality of the included studies was graded using the Newcastle-Ottawa quality assessment scale (NOS). Mortality risk

data were pooled using the Mantel-Haenszel random effects models with odds ratios (OR) as the effect measure with 95% confidence intervals (CI). Heterogeneity among studies was assessed using Higgins and Thompson I² statistic where I² values correspond to the following levels of heterogeneity: low (< 25%), moderate (25%-75%) and high (> 75%). The presence of potential publication bias was verified by visual inspection of the funnel plot. Due to the low number of included studies (< 10), small-study bias was not examined as our analysis was underpowered to detect such bias. A predefined sensitivity analysis (leave-one-out analysis) was performed removing 1 study at a time, to evaluate the stability of our results. All meta-analyses were conducted using Comprehensive Meta-Analysis software, version 3 (Biostat, United States). The initial search resulted in 2049 articles (951 in PubMed and 1098 in Scopus, respectively). After we removed duplicates (n = 885) and applied our inclusion criteria, 6 studies,¹⁻⁶ enrolling 1904 patients (mean age 64.7 years old, 1176 males) were included in the analysis. All the investigations were of high quality according to the NOS. The most frequent comorbidities were arterial hypertension and diabetes mellitus. Conversely, the prevalence of heart failure, coronary artery disease and chronic obstructive pulmonary disease were not systematically reported in the reviewed investigations, making a comprehensive evaluation impossible (table 1). The mortality rate was 17.0% (n = 324). RBBB was present in 150 COVID-19 participants (7.8% of cases). On pooled analysis, RBBB was significantly associated with a higher risk of death in the short-term (OR, 2.96; 95%CI, 2.04-4.30; P ≤ .0001; I² = 0%) (figure 1A). Visual inspection of the relative funnel plot revealed no significant evidence of publication bias (figure 1B). Sensitivity analysis slightly changed the combined OR, which remained statistically significant across a range from 2.38 (95%CI, 1.48-3.84) to 3.24 (95%CI, 2.16-4.85), suggesting that no single study had an undue impact on the study outcome. The results of present analysis suggest a higher mortality risk in COVID-19 patients with RBBB. We decided to analyze the impact on RBBB since several analyses have demonstrated that right