

Juan Calderón-Colmenero,^a José A. García-Montes,^b
Alberto Aranda-Frausto,^a Francisco Castillo-Castellón,^a
Edgar Lupinta-Paredes,^b and Jorge L. Cervantes-Salazar^{c,*}

^aDepartamento de Cardiología Pediátrica, Instituto Nacional de Cardiología Ignacio Chávez, Ciudad de México, Mexico

^bDepartamento de Cardiología Intervencionista en Cardiopatías Congénitas, Instituto Nacional de Cardiología Ignacio Chávez, Ciudad de México, Mexico

^cDepartamento de Cirugía Cardíaca Pediátrica y Cardiopatías Congénitas, Instituto Nacional de Cardiología Ignacio Chávez, Ciudad de México, Mexico

* Corresponding author:

E-mail address: jorgeluis.cervantes@gmail.com

(J.L. Cervantes-Salazar).

REFERENCES

1. Calderón J, Cervantes J, Curi P. Tronco arterioso común. In: Attie F, Calderón J, Zabal C, Buendía A, eds. In: *Cardiología pediátrica*. 2.a ed. México: Médica Panamericana; 2013:267–275.
2. Espínola N, Muñoz L, González R, et al. Tronco arterioso común en adultos. *Arch Cardiol Mex*. 2008;78:210–216.
3. Calderón J, Sandoval J, Beltrán M. Hipertensión pulmonar asociada con cardiopatías congénitas y síndrome de Eisenmenger. *Arch Cardiol Mex*. 2015;85:32–49.
4. van der Feen D, Bartelds B, de Boer RA, et al. Assessment of reversibility in pulmonary arterial hypertension and congenital heart disease. *Heart*. 2019;105:276–282.
5. Roberts K, McElroy J, Wong W, et al. *BMPR2* mutations in pulmonary arterial hypertension with congenital heart disease. *Eur Respir J*. 2004;24:371–374.
6. Liu D, Liu Q, Guan L, et al. *BMPR2* mutation is a potential predisposing genetic risk factor for congenital heart disease associated pulmonary vascular disease. *Int J Cardiol*. 2016;211:132–136.

<https://doi.org/10.1016/j.rec.2021.03.005>

1885-5857/© 2021 Sociedad Española de Cardiología. Published by Elsevier España, S.L.U. All rights reserved.

Acute myocarditis after administration of the BNT162b2 vaccine against COVID-19



Miocarditis aguda tras administración de vacuna BNT162b2 contra la COVID-19

To the Editor,

Adverse reactions to vaccines are usually insignificant, but there have been reports of myopericarditis after vaccination.¹ Recently, several cases have been published of myopericarditis associated with severe acute respiratory syndrome coronavirus 2 (SARS-CoV-2) infection.^{2,3}

We describe the case of a 39-year-old male physician, with a past medical history of asthma, autoimmune hypothyroidism, chronic atrophic gastritis, an isolated episode of atrial fibrillation, and recurrent spontaneous pneumothorax with left apical lobectomy. In recent months, he had undergone several PCR and serology screening tests for SARS-CoV-2 infection, all of which were negative. The patient gave informed consent for the write-up and publication of this clinical case.

As per the COVID-19 vaccination program, he received the first dose of the BNT162b2 vaccine, with no significant adverse reactions. At 6 hours postvaccination with the second dose, 21 days after the first, he noted a persistent fever of above 38 °C, which was

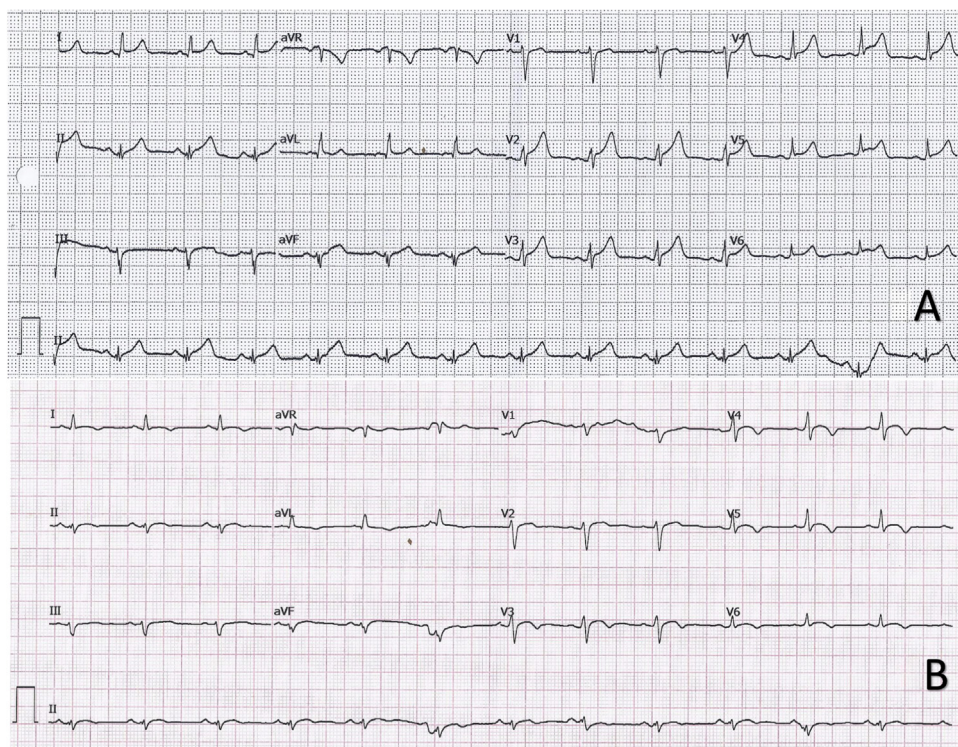


Figure 1. A: electrocardiogram showing sinus rhythm with a reduced PR interval in I and V5-V6 and diffuse ST elevation with upward concavity. B: electrocardiogram in sinus rhythm with < 1 mm elevation and upward concavity in V3-V6 and negative T waves in I, II, aVL, and V3-V6.