

# Symptomatic Acute Myocarditis in 7 Adolescents After Pfizer-BioNTech COVID-19 Vaccination

Mayme Marshall, MD,<sup>a</sup> Ian D. Ferguson, MD,<sup>b</sup> Paul Lewis MD, MPH,<sup>a</sup> Preeti Jaggi, MD,<sup>c</sup> Christina Gagliardo, MD,<sup>d,e</sup> James Stewart Collins, MD,<sup>f</sup> Robin Shaughnessy, MD,<sup>a</sup> Rachel Caron, BA,<sup>a</sup> Cristina Fuss, MD,<sup>g</sup> Kathleen Jo E. Corbin, MD, MHS,<sup>b</sup> Leonard Emuren, MBBS, PhD,<sup>b</sup> Erin Faherty, MD,<sup>b</sup> E. Kevin Hall, MD,<sup>b</sup> Cecilia Di Pentima, MD, MPH,<sup>d,e</sup> Matthew E. Oster, MD, MPH,<sup>c</sup> Elijah Paintsil, MD,<sup>b</sup> Saira Siddiqui, MD,<sup>d</sup> Donna M. Timchak, MD,<sup>d,h</sup> Judith A. Guzman-Cottrill, DO<sup>a</sup>

Trials of coronavirus disease 2019 (COVID-19) vaccination included limited numbers of children, so they may not have detected rare but important adverse events in this population. We report 7 cases of acute myocarditis or myopericarditis in healthy male adolescents who presented with chest pain all within 4 days after the second dose of Pfizer-BioNTech COVID-19 vaccination. Five patients had fever around the time of presentation. Acute COVID-19 was ruled out in all 7 cases on the basis of negative severe acute respiratory syndrome coronavirus 2 real-time reverse transcription polymerase chain reaction test results of specimens obtained by using nasopharyngeal swabs. None of the patients met criteria for multisystem inflammatory syndrome in children. Six of the 7 patients had negative severe acute respiratory syndrome coronavirus 2 nucleocapsid antibody assay results, suggesting no previous infection. All patients had an elevated troponin. Cardiac MRI revealed late gadolinium enhancement characteristic of myocarditis. All 7 patients resolved their symptoms rapidly. Three patients were treated with nonsteroidal antiinflammatory drugs only, and 4 received intravenous immunoglobulin and corticosteroids. In this report, we provide a summary of each adolescent's clinical course and evaluation. No causal relationship between vaccine administration and myocarditis has been established. Continued monitoring and reporting to the US Food and Drug Administration Vaccine Adverse Event Reporting System is strongly recommended.

On December 11, 2020, the US Food and Drug Administration issued an emergency use authorization (EUA) for the Pfizer-BioNTech coronavirus disease 2019 (COVID-19) mRNA vaccine for prevention of COVID-19 for individuals aged  $\geq 16$  years.<sup>1</sup> On May 10, 2021, the US Food and Drug Administration revised the EUA for this vaccine to include children aged  $\geq 12$  years.<sup>1</sup> The Pfizer vaccine remains the only vaccine with an EUA for children aged 12 to 17

years. This vaccine was demonstrated to have a 94% to 95% efficacy in preventing COVID-19 infection in participants aged 16 to 55 years and 100% efficacy in the group of those aged 12 to 15 years.<sup>1,2</sup> Systemic reactogenicity occurred more commonly in younger patients and after the second dose of vaccine.<sup>1</sup>

Postimmunization myocarditis is a known rare adverse event after other

## abstract

<sup>a</sup>Department of Pediatrics, Oregon Health and Science University, Portland, Oregon; <sup>b</sup>Department of Pediatrics, Yale University, New Haven, Connecticut; <sup>c</sup>Department of Pediatrics, Emory University and Children's Healthcare of Atlanta, Atlanta, Georgia; <sup>d</sup>Goryeb Children's Hospital, Atlantic Health System, Morristown, New Jersey; <sup>e</sup>Thomas Jefferson University, Philadelphia, Pennsylvania; <sup>f</sup>Spectrum Health, Grand Rapids, Michigan; <sup>g</sup>Department of Radiology, Oregon Health and Science University, Portland, Oregon; and <sup>h</sup>Irving Medical Center, Columbia University, New York, New York

Drs Marshall and Guzman-Cottrill drafted the initial manuscript, designed the data collection instruments, collected data, participated in literature review, and reviewed and revised the manuscript; Drs Jaggi and Lewis drafted case details for the initial manuscript, designed the data collection instruments, collected data, and reviewed and revised the manuscript; Drs Collins, Ferguson Gagliardo, and Shaughnessy drafted case details for the initial manuscript, collected data, and reviewed and revised the manuscript; Drs Corbin, Di Pentima, Emuren, Faherty, Fuss, Hall, Oster, Paintsil, Siddiqui, and Timchak reviewed clinical data and critically reviewed and revised the manuscript for important intellectual subject matter content; Ms Caron participated in drafting the initial manuscript, the data collection, and the literature review; and all authors approved the final manuscript as submitted and agree to be accountable for all aspects of the work.

DOI: <https://doi.org/10.1542/peds.2021-052478>

Accepted for publication May 28, 2021

Address correspondence to Judith Guzman-Cottrill, DO, Department of Pediatrics, Oregon Health and Science University, 707 SW Gaines Rd, Mail Code CDRC-P, Portland, OR 97239. E-mail: [guzmanco@ohsu.edu](mailto:guzmanco@ohsu.edu)

PEDIATRICS (ISSN Numbers: Print, 0031-4005; Online, 1098-4275).

Copyright © 2021 by the American Academy of Pediatrics

**FINANCIAL DISCLOSURE:** The authors have indicated they have no financial relationships relevant to this article to disclose.

**To cite:** Marshall M, Ferguson I D, Lewis P, et al. Symptomatic Acute Myocarditis in 7 Adolescents After Pfizer-BioNTech COVID-19 Vaccination. *Pediatrics*. 2021;148(3):e2021052478

vaccinations, particularly after smallpox vaccination.<sup>3</sup> Recently, the news media have highlighted reports of myocarditis after COVID-19 mRNA vaccination involving US military patients and patients from Israel.<sup>4,5</sup> The Israeli cohort identified a male predominance with an incidence of 1 in 20 000 (men aged 18 to 30 years). However, a conclusive causal link to vaccination has not been confirmed at this time. Additionally, 2 recently published European case reports describe myocarditis after COVID-19 mRNA vaccination in a 56-year-old man with previous COVID-19 and a 39-year-old man with no history of COVID-19.<sup>6,7</sup> In this report, we summarize case histories of 7 healthy male adolescents aged 14 to 19 years who developed acute myocarditis or myopericarditis within 4 days after receiving the second dose of the Pfizer-BioNTech COVID-19 vaccine, none of whom met criteria for multisystem inflammatory syndrome in children (MIS-C). All 7 patients were vaccinated in April and May of 2021 and have been reported to the

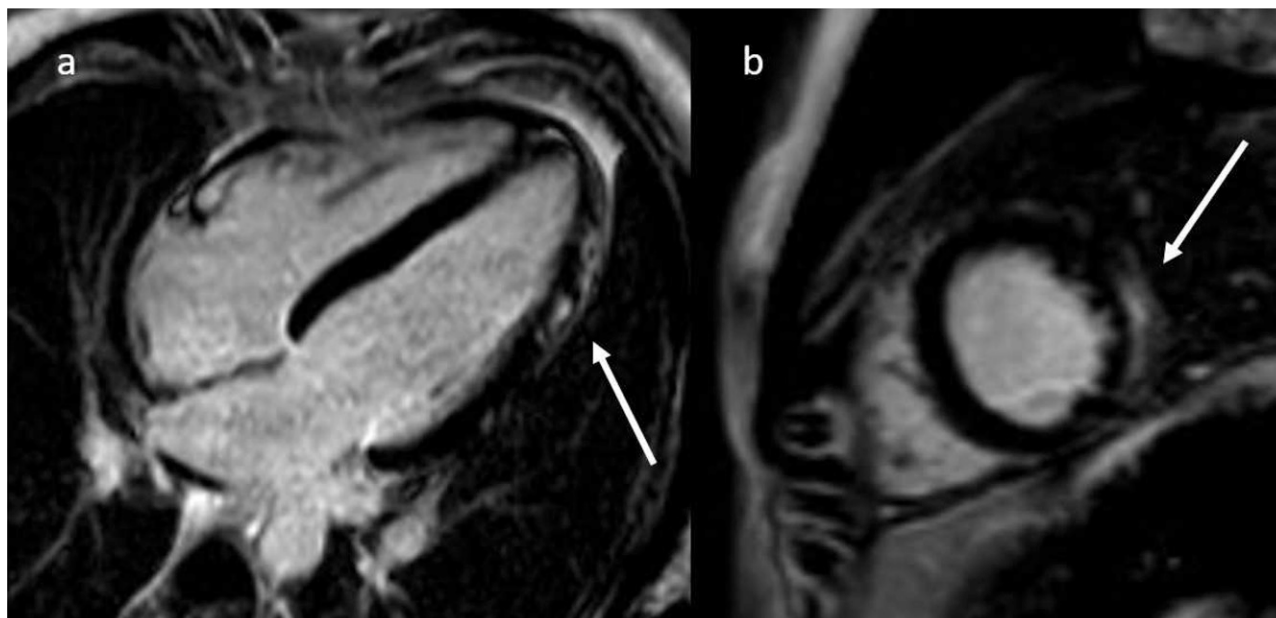
Vaccine Adverse Event Reporting System (VAERS).

#### PATIENT 1

A previously well 16-year-old male individual presented to an emergency department (ED) with fatigue, poor appetite, fever of 38.3°C, and pain in the chest and both arms 2 days after his second Pfizer-BioNTech COVID-19 vaccine dose. He had no history of recent viral illness symptoms and no known COVID-19 exposures. Evaluation included an electrocardiogram (ECG) that revealed atrioventricular dissociation with junctional escape and ST elevation and an elevated troponin I (2.59 ng/mL, normal range for this hospital: <0.03 ng/mL). He was transferred to the PICU of a tertiary care children's hospital for suspected myocarditis. Inflammatory markers were mildly elevated, with D-dimer 1.52 ug/mL, erythrocyte sedimentation rate (ESR) of 43 mm/hour, and maximum C-reactive protein (CRP)

of 12.3 mg/L (normal range: <1.0 mg/dL). Cardiac MRI revealed late gadolinium enhancement characteristic for myocarditis (Fig 1).

Echocardiogram was normal. Troponin I peaked at 12.43 ng/mL (normal range for this hospital: <0.80 ng/mL) (Table 1). A nasopharyngeal swab for severe acute respiratory syndrome coronavirus 2 (SARS-CoV-2) polymerase chain reaction (PCR) was negative, as was the patient's serum SARS-CoV-2 nucleocapsid antibody. All other viral diagnostic studies were negative (Table 1). He remained well appearing, hemodynamically stable, and in normal sinus rhythm throughout the 6-day hospitalization. He received 100 g (1.5 g/kg) of intravenous immunoglobulin (IVIg), then 10 mg/kg of methylprednisolone intravenously on 3 consecutive days, followed by a planned 12-week oral prednisone taper. He also received three 15- to 30-mg doses of intravenous ketorolac for pain. By 3



**FIGURE 1** Cardiac MRI of patient 1. Four chamber (A) and short axis (B) postcontrast images depicting apical and midchamber lateral wall subepicardial late gadolinium enhancement (arrows). Pattern and distribution are highly characteristic for myocarditis.

**TABLE 1** Summary of Diagnostics and Therapeutics: 7 Cases of Symptomatic Myocarditis After Dose 2 of Pfizer-BioNTech COVID-19 Vaccine

|   | Patient 1  | Patient 2                              | Patient 3                 | Patient 4                | Patient 5               | Patient 6                | Patient 7                 |
|---|--|--|---------------------------|--------------------------|-------------------------|--------------------------|---------------------------|
| Laboratory findings on admission  |  |  |                           |                          |                         |                          |                           |
| Troponin (normal range), ng/mL  | Troponin I: 2.59 (<0.03)   | High-sensitivity troponin T: 232 (<14) | Troponin I: 5.55 (<0.045) | Troponin T: 1.09 (<0.01) | Troponin T: 3.2 (<0.01) | Troponin I: 0.66 (<0.01) | Troponin I: 22.1 (<0.045) |
| Brain natriuretic peptide (normal < 100), pg/mL                           | —  | —                                      | —                         | —                        | —                       | —                        | 107.9                     |
| NT-proBNP (normal <125), pg/mL  | 428  | —                                      | 376                       | —                        | 978                     | 149                      | —                         |
| Peripheral white blood cell count, thousands of cells per mm <sup>3</sup> | 6.97   | 8.69                                   | 11.8                      | 12.6                     | 16.3                    | 5.0                      | 8.11                      |
| Absolute lymphocyte count, thousands of cells per mm <sup>3</sup>         | 1.69   | 1.39                                   | 2.13                      | 2.3                      | 4.1                     | 1.4                      | 1.05                      |
| Absolute neutrophil count, thousands of cells per mm <sup>3</sup>         | 4.65   | 5.93                                   | 7.46                      | 9.5                      | 9.8                     | 2.8                      | 4.73                      |
| Platelet count, thousands of cells per mm <sup>3</sup>                    | 198  | 208                                    | 231                       | 236                      | 297                     | 189                      | 208                       |
| Albumin (g/dL)  | 3.9  | 4.1                                    | 4.1                       | 4.4                      | 4.0                     | 3.8                      | 3.5                       |
| Aspartate transaminase, U/L   | 54   | 29                                     | 41                        | 82                       | 150                     | 59                       | 87                        |
| Alanine transaminase, U/L   | 30   | 14                                     | 33                        | 20                       | 46                      | 22                       | 38                        |
| Ferritin, ug/L  | 70   | —                                      | 90                        | 103                      | 347                     | 65                       | 84                        |
| CRP (normal <1.0), mg/dL  | 0.99   | 6.7                                    | 2.5                       | 12.7                     | 18.1                    | 1.5                      | 7.7                       |
| ESR, mm/h   | 18   | 13                                     | 6                         | 40                       | 38                      | 3                        | 10                        |
| Prothrombin time, seconds   | —  | —                                      | 14.0                      | —                        | 12.1                    | 11.4                     | 14.8                      |
| Partial thromboplastin time, seconds                                      | 22.3   | —                                      | 31.4                      | —                        | 30.4                    | 27.9                     | 35.6                      |
| International normalized ratio INR  | 1.11   | —                                      | 1.06                      | —                        | 1.13                    | 1.06                     | 1.2                       |
| Other pertinent laboratory findings                                       | Troponin I: 12.43 (<0.80) Troponin T: 1.09 (<0.01) Troponin T: 3.33 (<0.01) Troponin T: 0.82 (<0.01) |  |                           |                          |                         |                          |                           |

**TABLE 1** Continued

|   | Patient 1  | Patient 2  | Patient 3   | Patient 4   | Patient 5  | Patient 6  | Patient 7  |
|---|--|--|---|---|--|--|--|
| Highest troponin (normal range), ng/mL                            |  | High-sensitivity troponin T: 388 (<14)                                     | Troponin I: 12.20 (<0.045)  |   |  |  | Troponin I: 22.1 (<0.045)  |
| Lowest troponin before discharge (normal range), ng/mL            | Troponin I: 1.42 (<0.80)   | —  | Troponin I: 5.79 (<0.045)   | Troponin T: 0.4 (<0.01)   | Troponin T: 0.96 (<0.01)   | Troponin T: 0.01 (<0.01)   | Troponin I: 8.02 (<0.045)  |
| Highest BNP (normal range), ng/mL                                 | —  | —  | —   | —   | —  | —  | 205 (<100)   |
| Highest NT-proBNP (normal range), pg/mL                           | 482 pg/mL (<125)   | —  | 376 pg/mL (<300)  | —   | 978 pg/mL (<125)   | 275 pg/mL (<125)   | —  |
| Highest CRP (normal <1.0), mg/dL                                  | 1.23   | 6.7  | 2.53  | 12.7  | 18.1   | 1.8  | 12.7   |
| COVID-19 PCR result   | Negative   | Negative   | Negative  | Negative  | Negative   | Negative   | Negative   |
| COVID-19 spike antibody (manufacturer)                            | —  | —  | Positive (Roche)  | Positive (Roche)  | Positive (Roche)   | Positive (Roche)   | —  |
| COVID-19 nucleocapsid antibody result                             | Negative (Abbott)  | —  | Negative (Roche)  | Negative (Roche)  | Negative (Roche)   | Negative (Roche)   | Negative (Abbott)  |
| Respiratory pathogen panel PCR result <sup>a</sup> (manufacturer) | Negative (BioFire)   | Negative (BioFire)   | Negative (BioFire)  | Negative (BioFire)  | Negative (BioFire)   | Negative (BioFire)   | Negative (BioFire)   |
| Adenovirus diagnostics result                                     | Negative serum PCR   | —  | Negative serology   | Negative serum PCR  | Negative serum PCR   | —  | Negative serum PCR   |
| Enterovirus diagnostics result                                    | Negative serum PCR   | —  | Negative serology   | Negative serum PCR  | Negative serum PCR   | Negative serum PCR   | Negative serum PCR   |
| Cytomegalovirus diagnostics result                                | Negative serum PCR   | —  | Negative serology   | Negative serum PCR  | Negative serum PCR   | Negative serum PCR   | Negative serology  |
| Epstein-Barr virus diagnostics result                             | —  | —  | Negative serology   | Negative serum PCR  | Negative serum PCR   | Negative serum PCR   | Negative serology  |
| Other diagnostics   | —  | —  | Negative serology   | Negative serum PCR  | Negative serum PCR   | Negative IgM, positive IgG antibody  | Negative serology  |
| Diagnostic imaging findings                                       | —  | —  | Negative parvovirus, bartonella, and Lyme serology, negative urine drug screen  | —   | Negative parvovirus and bartonella serology, negative HHV-6 serum PCR        | Negative Lyme serology, negative mycoplasma serum PCR, negative parvovirus serum PCR | Negative parvovirus IgM, positive parvovirus IgG antibody, negative mycoplasma PCR (throat swab) |
| Cardiac MRI   | LGE (subepicardial) involving lateral LV apex, myocardial edema of lateral LV wall, left axillary adenopathy | LGE involving mid LV wall, myocardial edema of basal inferolateral LV wall | LGE (subepicardial) involving basal anterolateral and basal to midventricular inferolateral LV segments, myocardial edema, elevated extracellular volume fraction (29.2%) | Fibrosis, myocardial edema, hyperemia, mild mitral regurgitation (~18%) | LGE (epicardial) involving anterior and lateral LV wall, no myocardial edema | LGE, diffuse myocardial edema  | LGE (subepicardial) involving mid and apical LV free wall, myocardial edema, hyperemia           |

**TABLE 1** Continued

|  | Patient 1   | Patient 2                      | Patient 3   | Patient 4   | Patient 5  | Patient 6              | Patient 7   |
|--|---|--------------------------------|---|---|--|------------------------|---|
| Echocardiogram   | Normal  | Normal                         | Borderline basal lateral and basal posterior strain | Normal  | Normal   | Normal                 | Mildly depressed RV and LV systolic function (LVEF 47%) |
| ECG  | Atrioventricular dissociation with junctional escape rhythm, ST elevation | ST segment elevation (diffuse) | ST elevation (diffuse), T-wave abnormality          | ST elevation                                      | Sinus bradycardia, T-wave abnormality                      | ST elevation (diffuse) | ST elevation, low voltage of extremity leads            |
| Therapeutics   | None  | None                           | None  | None  | None   | None                   | LFNC  |
| Oxygen supplementation                                 | None  | None                           | None  | None  | None   | None                   | None  |
| Vasoactive medications or inotropic support            | None  | None                           | None  | None  | None   | None                   | None  |
| Antiinflammatory agents and other relevant medications | NSAID, IVig, IV methylprednisolone, PO prednisone, famotidine             | NSAID, colchicine, aspirin     | NSAID, famotidine                                   | NSAID, IVig, IV methylprednisolone, PO prednisone | NSAID, IVig, IV methylprednisolone, PO prednisone, aspirin | IVig, PO prednisone    | NSAID, famotidine, furosemide                           |

HHV-6, human herpesvirus-6; IgG, immunoglobulin G; IgM, immunoglobulin M; INR, international normalized ratio; IV, intravenous; LGE, late gadolinium enhancement; LFNC, low flow nasal cannula; LV, left ventricular; LVEF, left ventricular ejection fraction; PO, per os (oral); q12hr, every 12 hours; RF, regurgitant fraction; RV, right ventricular; —, not done.

<sup>a</sup> BioFire Respiratory Panel includes PCR for adenovirus, coronavirus 229E, coronavirus HKU1, coronavirus NL63, coronavirus OC43, metapneumovirus (human), rhinovirus or enterovirus, influenza A, influenza B, parainfluenza 1, parainfluenza 2, parainfluenza 3, parainfluenza 4, respiratory syncytial virus, *Bordetella parapertussis*, *Bordetella pertussis*, *Chlamydia pneumoniae*, and *Mycoplasma pneumoniae*.

weeks after presentation, troponin had returned to normal.

**PATIENT 2**

A 19-year-old previously well male individual presented to a general ED with acute, persistent chest pain 3 days after his second Pfizer-BioNTech COVID-19 vaccine dose. He felt unwell for 3 days after vaccination, with myalgias, fatigue, weakness, and subjective low-grade fevers. He had no recent or remote history of viral illness and no known COVID-19 exposures. ECG revealed diffuse ST elevation consistent with acute myocardial injury or pericarditis. Urgent cardiac catheterization revealed normal coronary arteries and normal left ventricular function. Initial high-sensitivity troponin T (232 ng/L, normal range: <14 ng/L) and CRP (6.7 mg/dL, normal range: <1.0 mg/dL) were highly elevated. Cardiac MRI confirmed myocarditis on the basis of the finding of patchy, midwall late gadolinium enhancement along the basal inferolateral wall segment. A nasopharyngeal swab for SARS-CoV-2 was negative. He remained hemodynamically stable and was discharged from the hospital 2 days later with the diagnosis of myopericarditis. He was treated with 1 30 mg dose of intravenous ketorolac, 0.6 mg colchicine daily, and 650 mg aspirin 3 times daily.

One week later, he was seen in follow-up. He complained of mild fatigue but had no chest pain or shortness of breath, and his ECG revealed tachycardia, with a heart rate of 105 beats per minute. ST segment resolution was noted. As a result of his sinus tachycardia, a 48-hour Holter monitor was done, which revealed an average heart rate of 83 beats per minute with a 1% premature ventricular contraction burden. No other arrhythmias were noted. An

echocardiogram was normal. The colchicine (0.6 mg) and aspirin (325 mg) daily were continued.

### PATIENT 3

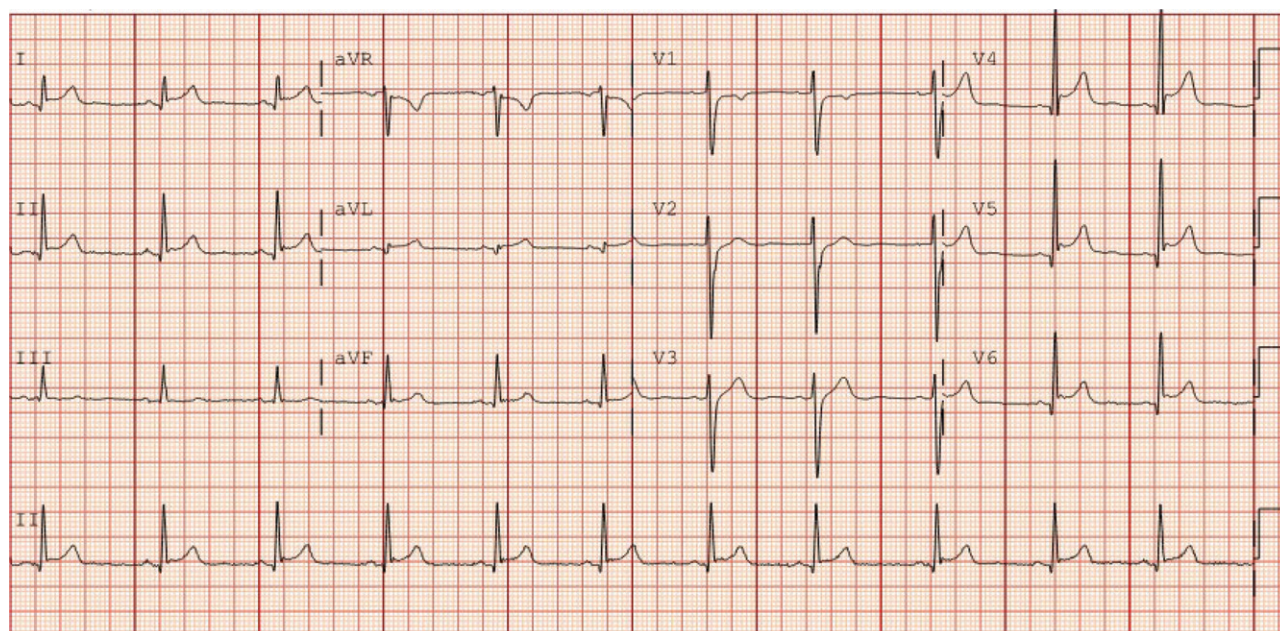
A 17-year-old previously well male individual presented with chest pain 2 days after his second Pfizer-BioNTech COVID-19 vaccine. Chest pain was worse when lying flat and was associated with left arm pain and paresthesias. He had no recent or remote history of viral illness and no known COVID-19 exposures. ECG revealed abnormal T waves with diffuse ST elevation consistent with pericarditis (Fig 2). Notable laboratory studies included elevated troponin I (5.550 ng/mL, normal range: <0.045 ng/mL), N-terminal pro-brain natriuretic peptide (NT-proBNP) (376 pg/mL, normal range: <100 pg/mL) and CRP (25.3 mg/L, normal range: <1.0 mg/dL). Echocardiogram revealed normal function and coronaries, no effusion, trace mitral and aortic valve insufficiency, and decreased

left ventricular basolateral and posterior regional strain. Cardiac MRI revealed delayed enhancement at the left ventricular subepicardial basal anterolateral segment and basal to midventricular inferolateral segments, consistent with myocardial necrosis. There was evidence of diffuse fibrosis on T1-weighted imaging and myocardial edema on T2 mapping. Results for SARS-CoV-2 spike antibody were positive, and nucleocapsid antibody were negative. Workup for other infections and a urine drug screen result were negative. Troponin peaked at 12.200 ng/mL. The patient's symptoms resolved with ibuprofen 600 mg orally every 6 hours, and he was discharged at 48 hours. On the basis of the characteristics of his chest pain, ECG findings, and prompt response to antiinflammatory medication, pericardial involvement was suspected. The presence of elevated cardiac markers and inflammation on cardiac MRI

prompted the diagnosis of myopericarditis. At 1-week follow-up, he remained asymptomatic with normal troponin, CRP, and ECG; the echocardiogram was unchanged.

### PATIENT 4

An 18-year-old previously well male individual was admitted with a chief complaint of chest pain 3 days after he received the second Pfizer-BioNTech COVID-19 vaccine. Soon after vaccination, he had developed malaise, arthralgia, myalgia, and subjective fever. He had no recent or remote history of viral illness and no known COVID-19 exposures. Two days before admission, he noted midsternal chest pain and presented to his primary care physician, who noted ST elevation on ECG, prompting transfer to an ED, where evaluation revealed elevated troponin T (1.09 ng/mL, normal range: <0.01 ng/mL), ST elevation on ECG, and normal echocardiogram. Cardiac MRI revealed edema, hyperemia, and



**FIGURE 2**

Patient 3 ECG with diffuse ST elevations seen, characteristic of pericarditis. aVF, augmented Vector Foot; aVL, augmented Vector Left; aVR, augmented Vector Right.

fibrosis, consistent with myocarditis. Results for a nasopharyngeal SARS-CoV-2 PCR were negative, and antibody testing revealed positive spike and negative nucleocapsid antibodies for SARS-CoV-2. Troponin testing reduced over the course of the 3-day hospitalization, and telemetry remained normal. He was treated with 70 g IVIg and received 30 mg methylprednisolone intravenously every 12 hours for 2 doses, followed by prednisone 30 mg orally twice daily with a gradual taper over 4 weeks. He also received ibuprofen 600 mg orally every 6 hours as needed for pain and was discharged with a 30-day prescription for aspirin 81 mg orally once daily. At his first outpatient follow-up the next week, he felt well, troponin had normalized, and both echocardiogram and ECG remained normal.

#### **PATIENT 5**

A 17-year-old previously well male individual was admitted with a chief complaint of chest pain. His symptoms began 3 days after his second Pfizer-BioNTech COVID-19 vaccine dose with sore throat, headache, dry cough, and body aches. He had no recent or remote history of viral illness and no known COVID-19 exposures. He then developed subjective fever and was treated for suspected streptococcal pharyngitis with amoxicillin; however, a throat swab yielded a negative streptococcal antigen test result. The next day, he developed midsternal chest pain that was worse when lying flat and radiated to the left arm. Evaluation in the ED revealed elevated troponin T (3.21 ng/mL, normal range: <0.01 ng/mL), ST elevation on ECG, and normal function and structure on echocardiogram. Initial cardiac MRI revealed diffuse, nearly complete transmural left ventricle free wall gadolinium enhancement.

Results of a nasopharyngeal SARS-CoV-2 PCR were negative; antibody testing revealed positive spike and negative nucleocapsid antibodies for SARS-CoV-2. He received 70 g IVIg and was started on methylprednisolone 30 mg intravenously every 12 hours (2 doses), then transitioned to prednisone 30 mg orally every 12 hours with a gradual taper over 4 weeks. He also received ibuprofen 600 mg orally every 6 hours for the first 3 days and then as needed. He was discharged from the hospital with a 30-day prescription for aspirin 81 mg by mouth once daily. Troponin level initially fell by 50% over the first 48 hours, but, on the third day of admission, there was an acute rise that sustained for 12 hours before serial reduction. At discharge, troponin T remained elevated (0.96 ng/mL, normal range: <0.01 ng/mL). Telemetry during the 5-day hospitalization revealed occasional monomorphic premature ventricular contractions and sinus bradycardia during sleep but was otherwise normal. Serial echocardiograms were normal. On follow-up 4 days after discharge, the echocardiogram was normal, but ECG revealed diffuse T-wave abnormalities.

#### **Patient 6**

A 16-year-old previously well male individual was admitted with a chief complaint of chest pain. His initial symptoms began 3 days after the second Pfizer-BioNTech COVID-19 vaccine with malaise and subjective fever. He had no recent or remote history of viral illness and no known COVID-19 exposures. The night before admission, he developed acute midsternal chest pain that lasted for ~18 hours. Evaluation in the ED revealed an elevated troponin T (0.66 ng/mL, normal range: <0.01 ng/mL) and ST elevation on ECG

but normal function and structure on echocardiogram. Cardiac MRI revealed diffuse edema and subepicardial late gadolinium enhancement. Results of a nasopharyngeal SARS-CoV-2 PCR were negative, and antibody testing revealed positive spike and negative nucleocapsid antibodies for SARS-CoV-2. He was treated with 70 g IVIg and started on prednisone 30 mg orally twice daily with a gradual taper over 4 weeks. He did not receive any nonsteroidal antiinflammatory drugs (NSAIDs).

Troponin T climbed after admission and remained elevated throughout the hospitalization. Chest pain resolved after administration of 6 mg of morphine in the initial ED evaluation. Telemetry was normal throughout hospitalization. He was discharged 3 days after admission. He had not yet returned for follow-up visit at the time of this submission.

#### **PATIENT 7**

A 14-year-old previously well male individual presented to an urgent care clinic with pleuritic chest pain and shortness of breath 2 days after receiving his second Pfizer-BioNTech vaccine. A measured fever of 38.3°C began the day of vaccination. He had no recent or remote history of viral illness and no known COVID-19 exposures. ECG revealed ST segment elevation consistent with acute pericarditis. Additional evaluation included an echocardiogram that revealed mildly depressed left and right ventricular systolic function and elevated troponin I (22.1 ng/mL, normal range: <0.045 ng/mL). His maximum temperature was 38.6°C on the day of admission. Results of a nasopharyngeal SARS-CoV-2 PCR and serum nucleocapsid antibody were both negative. On hospital day 3, cardiac MRI revealed areas with

high T2 values indicating edema, T1 early postcontrast heterogeneity indicating hyperemia, and late gadolinium enhancement indicating myocardial fibrosis, all primarily in the subepicardial mid- and apical-left ventricle free wall. He was treated with NSAIDs (ketorolac at 30 mg once, followed by naproxen at 250 mg every 12 hours) and furosemide. Echocardiogram was improved 1 day after admission. He was discharged on hospital day 4 on the basis of improvement of symptoms and ejection fraction; the troponin had declined to 8.02 ng/mL. His final diagnosis was myopericarditis. On follow-up 13 days later, he appeared well but reported chest pain with exertion despite instructions to avoid strenuous exercise. An ECG revealed nonspecific T-wave changes, and echocardiogram was normal.

## DISCUSSION

We report 7 cases of clinical myocarditis or myopericarditis that developed in male individuals aged 14 to 19 years within 4 days of receiving the second dose of the Pfizer-BioNTech COVID-19 vaccine with no evidence of acute SARS-CoV-2 infection that did not fulfill criteria for MIS-C. Extensive diagnostic evaluation for other myocarditis etiologies was negative (Table 1), including respiratory pathogens from nasopharyngeal swabs, serum PCR tests, and infectious serologies. Additionally, all cardiac MRIs were diagnostic for myocarditis on the basis of the modified Lake Louise criteria rather than MIS-C characteristics described by Blondiaux et al<sup>8</sup> (diffuse myocardial edema without evidence of late gadolinium enhancement).<sup>9</sup> There was some suggestion of abnormal left ventricular myocardial echocardiographic strain corresponding to regions of

myocardial necrosis on cardiac MRI (patient 3).

All patients in this series had myocarditis or myopericarditis, which is the term for diagnosis of both myocardial and pericardial inflammation. These terms are often used interchangeably, which can make surveillance of these diseases challenging. Myocarditis and pericarditis are rare diseases. The true baseline incidence of myocarditis is unknown and varies by season, geography, and age: it has been reported to occur in 1.95 in 100 000 person-years in children aged <15 years in Finland and in 2.16 cases per 100 000 US military service members in a 30-day period.<sup>10</sup> It is more common in male individuals, and, among children, reveals a bimodal incidence pattern, with peaks at <2 years of age and in adolescence.<sup>11</sup> An evaluation for potential viral causes is recommended, although a cause is usually not found.<sup>12</sup> There have been previous reports of myocarditis after smallpox vaccination.<sup>10</sup> In patients with myocarditis, restriction from competitive sports is recommended for at least 3 months until cleared by a cardiologist to avoid sudden cardiac events while the heart muscle recovers.<sup>13</sup> Less is known about the true incidence of pericarditis. Pericarditis can occur in the setting of a variety of infectious and noninfectious illnesses.<sup>14</sup> In a study of patients aged  $\geq 16$  years in Finland, the incidence rate of hospitalizations for acute pericarditis was 3.32 in 100 000 person-years, with male individuals at higher risk than female individuals,<sup>15</sup> and, in 2007, the incidence of acute pericarditis in 1 study was 27.7 cases per 100 000 population per year.<sup>16</sup> Treatment of myocarditis and pericarditis may vary considerably depending on the patient characteristics, clinical

condition, underlying cause, and physician preference. Consistent with a known male preponderance of myocarditis and pericarditis, all 7 of our patients were male individuals.<sup>10</sup>

The Pfizer-BioNTech clinical trials revealed an increased systemic reactogenicity and immunogenicity in younger study participants after mRNA vaccine.<sup>1</sup> For example, 41.5% of adolescents developed chills after dose 2, compared with 35.1% of subjects aged 18 to 55 years.<sup>1</sup> In terms of immunogenicity, an analysis of SARS-CoV-2 50% neutralizing titers 1 month after dose 2 revealed higher geometric mean titer (GMT) in children aged 12 to 15 years (GMT = 1239.5), compared with subjects aged 16 to 25 years (GMT = 705.1).<sup>1</sup> Adverse events often occurred more frequently after dose 2 and within 2 days after vaccination and included injection site pain, fatigue, myalgia, chills, arthralgia, fever, injection site swelling or redness, nausea, malaise, and lymphadenopathy.<sup>1</sup> It is possible that myocarditis or myopericarditis may be an additional rare adverse event related to systemic reactogenicity, but, currently, no causal association has been established between this vaccine and myopericarditis.

In our case series, 6 patients received NSAID treatment. Four patients received IVIg and oral prednisone; 1 of these 4 patients also initially received high-dose methylprednisolone (Table 1). The recognition of a possible temporal relationship of COVID-19 vaccine and myocarditis is critical because the correct diagnosis may spare healthy adolescents and young adults presenting with chest pain and ECG ST elevation from undergoing unnecessary invasive medical procedures, such as cardiac catheterization. It is unclear if



**TABLE 2** Demographic and Clinical Characteristics of 7 Cases of Symptomatic Myocarditis After Dose 2 of Pfizer-BioNTech COVID-19 Vaccine

|   | Patient 1                            | Patient 2          | Patient 3                                 | Patient 4  | Patient 5                                     | Patient 6 | Patient 7         |
|---|--------------------------------------|--------------------|---|------------|---|-----------|-------------------|
| Age, y  | 16                                   | 19                 | 17  | 18         | 17  | 16        | 14                |
| Sex   | Male                                 | Male               | Male                                      | Male       | Male  | Male      | Male              |
| Race or ethnicity                                 | White                                | White              | White                                     | White      | Hispanic                                      | White     | White             |
| Wt, kg  | 68                                   | 68                 | 71  | 69         | 64  | 71        | 92                |
| BMI   | 24                                   | 19                 | 21  | 21         | 19  | 22        | 28                |
| Exposure to COVID-19 in 14 d before illness onset | None                                 | None               | None                                      | None       | None  | None      | None              |
| Time between vaccine dose 2 and symptom onset, d  | 2                                    | 3                  | 2   | 2          | 4   | 3         | 2                 |
| Total hospital LOS, d                             | 6                                    | 2                  | 2   | 4          | 5   | 3         | 4                 |
| ICU LOS, d  | 4                                    | None               | None                                      | 4          | 5   | 2         | 2                 |
| Symptoms on presentation                          |                                      |                    |   |            |   |           |                   |
| Chest pain  | Present                              | Present            | Present                                   | Present    | Present                                       | Present   | Present           |
| Other pain  | Bilateral arm pain                   | Myalgias           | Bilateral arm pain, numbness, paresthesia | —          | Bilateral arm pain, abdominal pain            | —         | —                 |
| Fever   | 38.3°C by history                    | Subjective, chills | —   | Subjective | Subjective                                    | —         | 38.3°C by history |
| Fatigue   | Present                              | Present            | —   | Present    | —   | —         | —                 |
| Other   | Nausea, vomiting, anorexia, headache | Weakness           | —   | Nausea     | Nausea, vomiting, anorexia, SOB, palpitations | SOB       | SOB               |

LOS, length of stay; SOB, shortness of breath; —, not present.

treatment with IVIg and/or corticosteroids, in the absence of MIS-C criteria, is warranted with all cases of myocarditis that develop temporally after COVID-19 vaccination. Notably, 3 patients recovered with NSAID therapy alone.

Myocarditis and myopericarditis after COVID-19 vaccination appear rare. As of May 23, 2021, the Centers for Disease Control and Prevention reports that 1 560 652 people aged <18 years have completed a 2-dose series of COVID-19 vaccine.<sup>17</sup> Of these, 652 758 adolescents received their second dose >14 days ago.<sup>17</sup> Currently, the Pfizer-BioNTech COVID-19 vaccine is the only COVID-19 vaccine authorized for children aged <18 years in the United States. We urge physicians

and health care providers to consider myocarditis in the evaluation of adolescents and young adults who develop chest pain after COVID-19 vaccination. All cases of myocarditis in patients with recent COVID-19 vaccination should be reported promptly to VAERS.

Our case series has inherent limitations. We compiled cases through personal communications among colleagues rather than using a systematic surveillance system to identify cases. It was not possible to exclude all alternative etiologies including idiopathic and other infectious etiologies, and there was not a systematic diagnostic evaluation for other viral etiologies. Cardiac biopsy was not performed on any patients because they were all clinically

stable during hospitalization. However, no patient had evidence of a preceding or concurrent symptomatic viral illness to implicate as an etiology of myocarditis, and the lack of eosinophilia dissuades a hypersensitivity reaction. The pathophysiology of myocarditis in these patients is indeterminate, and we do not know if it is the same or different from classic myopericarditis or myopericarditis after other vaccines, associated with acute COVID-19, or with MIS-C.<sup>10,18–20</sup> Given the nature of a case series, we cannot determine the incidence rate of myocarditis and myopericarditis after COVID-19 mRNA vaccination. Finally, a negative nucleocapsid antibody test result does not conclusively rule out the possibility of natural infection.

In this report, we summarize a series of US cases of myocarditis and myopericarditis after the Pfizer-BioNTech COVID-19 mRNA vaccine in adolescent male individuals. All cases in this report occurred after the second vaccine dose. Fortunately, none of our patients was critically ill and each was discharged from the hospital. At present, there is no definite causal relationship between these cases and vaccine administration.

As of May 12, 2021, children in the United States aged  $\geq 12$  years are now eligible to receive the Pfizer-BioNTech vaccine. Primary care and ED physicians and health care providers should consider myocarditis an etiology of chest pain in patients with recent COVID-19 mRNA vaccination. Elevated serum troponin, an abnormal ECG, and an abnormal cardiac MRI were seen in all cases (Table 2). An evaluation for acute COVID-19 infection (via PCR of respiratory tract sample) and past

disease (via SARS-CoV-2 nucleocapsid and spike protein antibodies) is recommended for all cases of myocarditis that occur after COVID-19 mRNA vaccination, as well as a comprehensive workup to exclude other infectious and noninfectious causes. The benefits of vaccination significantly exceed possible risks. Individuals and physicians are encouraged to follow the guidance of the Centers for Disease Control and Prevention Advisory Committee on Immunization Practices.<sup>21</sup> All cases of myocarditis with or without pericarditis occurring after COVID-19 vaccination should be promptly reported to VAERS.

#### ACKNOWLEDGMENTS

We thank our patients and their families, who consented to sharing the details of their medical illnesses in this case report. We thank Katherine M. Mullin, MD who assisted with case finding.

#### ABBREVIATIONS

COVID-19: coronavirus disease 2019  
CRP: C-reactive protein  
ECG: electrocardiogram  
ED: emergency department  
EUA: emergency use authorization  
GMT: geometric mean titer  
IVIg: intravenous immunoglobulin  
MIS-C: multisystem inflammatory syndrome in children  
NSAID: nonsteroidal antiinflammatory drug  
NT-proBNP: N-terminal pro-brain natriuretic peptide  
PCR: polymerase chain reaction  
SARS-CoV-2: severe acute respiratory syndrome coronavirus 2  
VAERS: Vaccine Adverse Event Reporting System

**FUNDING:** No external funding.

**POTENTIAL CONFLICT OF INTEREST:** The authors have indicated they have no potential conflicts of interest to disclose.

**COMPANION PAPER:** A companion to this article can be found online at [www.pediatrics.org/cgi/doi/10.1542/peds.2021-052644](http://www.pediatrics.org/cgi/doi/10.1542/peds.2021-052644).

#### REFERENCES

1. Pfizer-BioNTech. Full emergency use authorization (EUA) prescribing information. Available at: <http://labeling.pfizer.com/ShowLabeling.aspx?id=14471&format=pdf&#page=13>. Accessed May 15, 2021
2. Polack FP, Thomas SJ, Kitchin N, et al; C4591001 Clinical Trial Group. Safety and efficacy of the BNT162b2 mRNA covid-19 vaccine. *N Engl J Med*. 2020; 383(27):2603–2615
3. Halsell JS, Riddle JR, Atwood JE, et al; Department of Defense Smallpox Vaccination Clinical Evaluation Team. Myopericarditis following smallpox vaccination among vaccinia-naive US military personnel. *JAMA*. 2003; 289(24):3283–3289
4. Kime P. Pentagon tracking 14 cases of heart inflammation in troops after COVID-19 shots. 2021. Available at: <https://www.military.com/daily-news/2021/04/26/pentagon-tracking-14-cases-of-heart-inflammation-troops-after-covid-19-shots.html>. Accessed May 16, 2021
5. Reuters. Israel examining heart inflammation cases in people who received Pfizer COVID shot. *Reuters*. April 25, 2021. Available at: <https://www.reuters.com/world/middle-east/israel-examining-heart-inflammation-cases-people-who-received-pfizer-covid-shot-2021-04-25/>. 2021. Accessed May 16, 2021
6. Ammirati E, Cavalotti C, Milazzo A, et al. Temporal relation between second dose BNT162b2 mRNA Covid-19 vaccine and cardiac involvement in a patient with previous SARS-COV-2 infection. *Int J Cardiol Heart Vasc*. 2021;34:100774
7. Bautista García J, Peña Ortega P, Bonilla Fernández JA, Cárdenes León A, Ramírez Burgos L, Caballero Dorta E. Acute myocarditis after administration of the BNT162b2 vaccine against COVID-19. *Rev Esp Cardiol (Engl Ed)*. 2021;27: S1885–S1887(21)00133-X
8. Blondiaux E, Parisot P, Redheuil A, et al. Cardiac MRI in children with multisystem inflammatory syndrome associated with COVID-19. *Radiology*. 2020; 297(3):E283–E288
9. Ferreira VM, Schulz-Menger J, Holmvang G, et al. Cardiovascular magnetic resonance in nonischemic myocardial

- inflammation: expert recommendations. *J Am Coll Cardiol*. 2018;72(24):3158–3176
10. Arola A, Pikkarainen E, Sipilä JO, Pykäri J, Rautava P, Kytö V. Occurrence and features of childhood myocarditis: a nationwide study in Finland. *J Am Heart Assoc*. 2017;6(11):e005306
  11. Ghelani SJ, Spaeder MC, Pastor W, Spurney CF, Klugman D. Demographics, trends, and outcomes in pediatric acute myocarditis in the United States, 2006 to 2011. *Circ Cardiovasc Qual Outcomes*. 2012;5(5):622–627
  12. Dasgupta S, Iannucci G, Mao C, Clabby M, Oster ME. Myocarditis in the pediatric population: a review. *Congenit Heart Dis*. 2019;14(5):868–877
  13. Maron BJ, Udelson JE, Bonow RO, et al. Eligibility and Disqualification Recommendations for Competitive Athletes With Cardiovascular Abnormalities: Task Force 3: Hypertrophic Cardiomyopathy, Arrhythmogenic Right Ventricular Cardiomyopathy and Other Cardiomyopathies, and Myocarditis: A Scientific Statement From the American Heart Association and American College of Cardiology. *J Am Coll Cardiol*. 2015;66(21):2362–2371
  14. Adler Y, Charron P, Imazio M, et al; ESC Scientific Document Group. 2015 ESC Guidelines for the diagnosis and management of pericardial diseases: The Task Force for the Diagnosis and Management of Pericardial Diseases of the European Society of Cardiology (ESC) endorsed by: The European Association for Cardio-Thoracic Surgery (EACTS). *Eur Heart J*. 2015;36(42):2921–2964
  15. Kytö V, Sipilä J, Rautava P. Clinical profile and influences on outcomes in patients hospitalized for acute pericarditis. *Circulation*. 2014;130(18):1601–1606
  16. Imazio M, Cecchi E, Demichelis B, et al. Myopericarditis versus viral or idiopathic acute pericarditis. *Heart*. 2008;94(4):498–501
  17. Centers for Disease Control and Prevention. Demographic characteristics of people receiving COVID-19 vaccinations in the United States. 2021. Available at: <https://covid.cdc.gov/covid-data-tracker/#vaccination-demographic>. Accessed May 23, 2021
  18. Arness MK, Eckart RE, Love SS, et al. Myopericarditis following smallpox vaccination. *Am J Epidemiol*. 2004;160(7):642–651
  19. Kawakami R, Sakamoto A, Kawai K, et al. Pathological evidence for SARS-CoV-2 as a cause of myocarditis: JACC review topic of the week. *J Am Coll Cardiol*. 2021;77(3):314–325
  20. Vukomanovic VA, Krasic S, Prijic S, et al. Differences between pediatric acute myocarditis related and unrelated to SARS-CoV-2. *Pediatr Infect Dis J*. 2021;40(5):e173–e178
  21. Centers for Disease Control and Prevention. Vaccine recommendations and guidelines of the ACIP. 2021. Available at: <https://www.cdc.gov/vaccines/hcp/acip-recs/vacc-specific/covid-19>. Accessed May 23, 2021